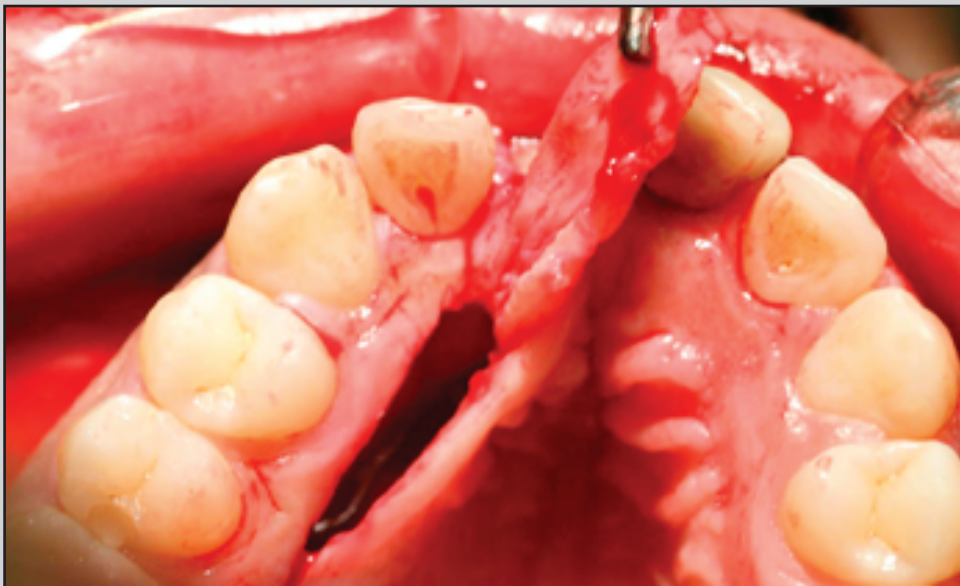
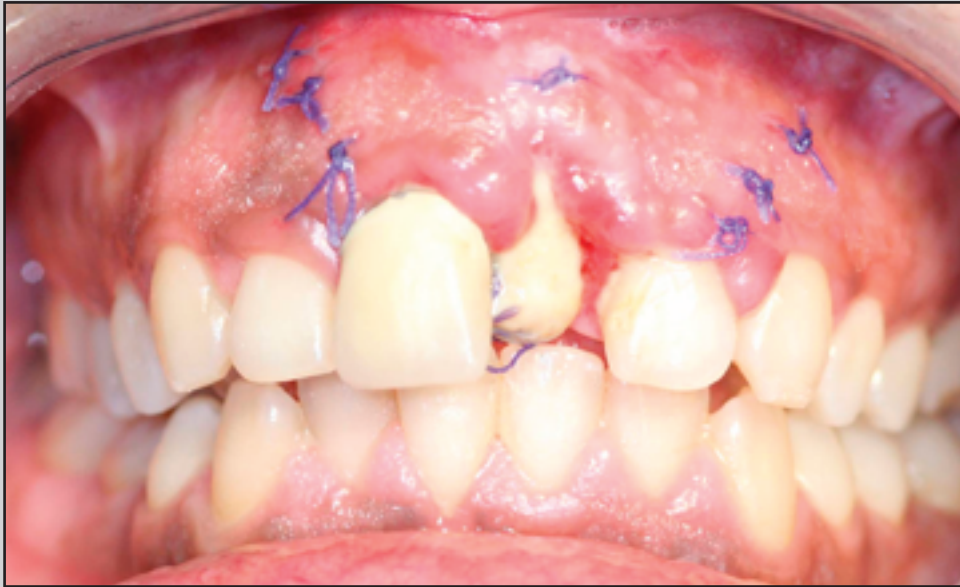
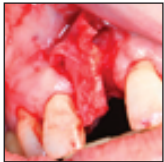

Incisive Vessel–Based Palatal Flap for the Reconstruction of Anterior Maxillary Soft Tissues



Alfredo Martinez-Garcia, MD, DMD*/
Javier Mareque Bueno, MD, DMD, PhD**

After tooth loss, alveolar bone resorption occurs and causes soft tissue collapse. In the anterior maxilla, this situation becomes a great challenge. Bone volume must be reestablished to allow for proper implant placement. Another challenge is achieving primary closure and improving soft tissue esthetics. Nine patients who were partially edentulous in the anterior maxilla and received 10 palatal incisive vessel–based connective tissue flaps were included in this study. Primary closure was successfully achieved in 4 patients who received simultaneous onlay block grafting in the surgical area [Au: Edit ok?]. Total treatment time was shortened as an added benefit, since a secondary procedure for soft tissue augmentation was not necessary. In two patients with improper implant angulation, this technique resulted in improved esthetics. (Int J Periodontics Restorative Dent 2011;31:xxx–xxx.)

*Private Practice, Bilbao, Spain.

**Hospital Valle de Hebrón, Barcelona, Spain; Professor, Universidad Internacional de Cataluña, Barcelona, Spain. [Au: Correct? Also, please provide a title for Dr Bueno at Hospital Valle de Hebrón.]

Correspondence to: [Au: Please provide an author for correspondence along with a complete mailing address and fax number and/or email address.]

[Au: Text has been edited heavily. Please pay close attention to this and revise where necessary.]

Anterior maxillary edentulism can be a great challenge in oral implantology since tooth loss causes alveolar bone resorption.¹ This resorption may affect the extraction socket height, width, or a combination of the two [Au: Edit ok?].^{2,3} In many cases, lack of bone volume is seen in conjunction with a loss of soft tissue quality and quantity. All of these factors, including high patient esthetic demands, may lead to a poor outcome.

There are many indications for soft tissue augmentation: improvement of the soft tissue esthetics, papillary reconstruction,⁴ increase in soft tissue thickness, need for primary closure, and improper implant emergence profile.

Bone width atrophy may be an indication for bone grafting. Block grafts or guided bone regeneration^{5,6} techniques can be used for this purpose. This increase in volume often makes primary wound closure difficult. Coronal displacement of the mucogingival junction and shortening of the vestibule depth may occur as a result of advancing the vestibular [Au: Buccal or labial meant here?] flap to achieve primary closure.

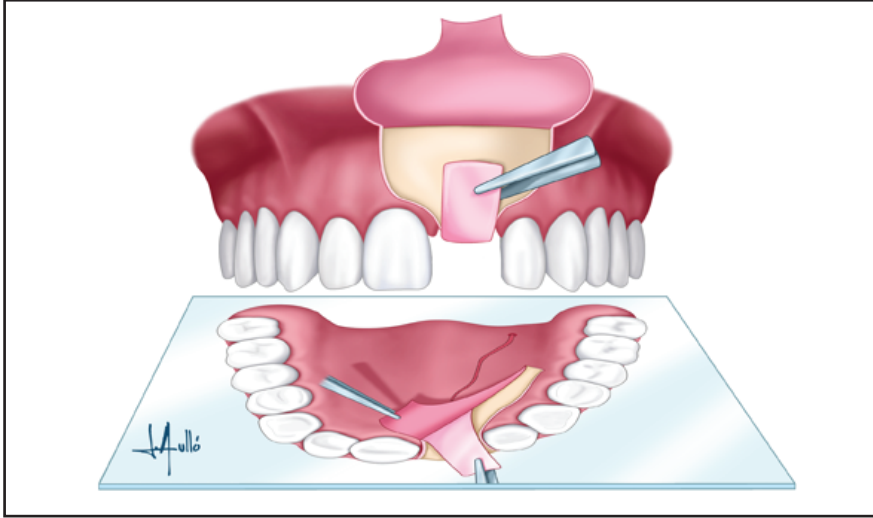


Fig 1 Illustration of the connective tissue palatal flap procedure.

Many procedures have been proposed to improve soft tissue esthetics, such as masticatory mucosal grafts, connective tissue grafts,^{7,8} acellular dermal matrix,^{9,10} and others.^{11–17} Soft tissue graft revascularization is accomplished using the periosteum-submucosa complex and the underlying bone [Au: Edit ok?]. In cases where an onlay bone graft is also performed, this vascular supply is diminished when a free soft tissue graft is inserted between the flap and the bone graft because of a lack of contact with native bone.

In this study, a rotated connective tissue flap based on incisive vessels was presented. This procedure reduces postoperative secondary contraction of the grafted soft tissue. As an added benefit, there is no need to

cover the graft completely, compared to free grafts.

The palatal connective tissue flap was first described by Khoury and Happe¹⁸ in 2001 [Au: Reference says 2000.]. This flap consists of a strip of connective tissue pulled out of the palatal vault, which is then rotated into the defect. This tissue receives its vascular [Au: Blood?] supply from the incisive vessels. The length and width of the flap should not exceed a proportion of 4:1 (Fig 1).¹⁹

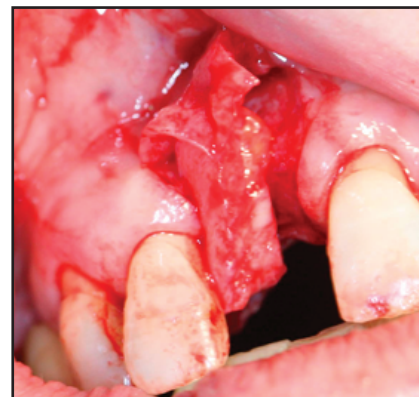
Success is dependent on the thickness of the palatal fibromucosa, which is greatest between the canines and molars. Another important factor is the distance from the marginal gingiva to the palatine vessel, which varies from 7 to 17 mm at second premolar sites.²⁰

Method and materials

Nine patients (six women, three men) with a mean age of 47.6 years (range, 30 to 73 years) and 10 anterior maxillary defects in which a palatal flap was raised were included in this study. Two patients were smokers. All patients were in good general health and signed a consent form prior to treatment. [Au: Correct?]

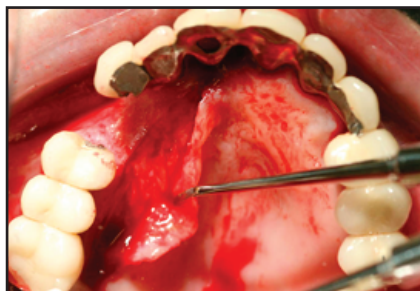

Fig 2 A partial-thickness palatal flap was (a, left) raised and (b, right) rotated to the buccal aspect of the recipient site. [Au: Edit ok?]



Technique

Local anesthesia was administered at both the palate and the recipient site. Prior to surgery, a minimum palatal mucosal thickness of 3 mm should be confirmed to perform this procedure.²¹ In the area of the defect to be treated, a vestibular [Au: Buccal? Labial?] flap was raised with two releasing incisions. If the purpose of the procedure was to increase buccal gingival thickness, a partial-thickness flap was raised. If an implant was to be placed simultaneously, the flap was of full thickness at the alveolar crest. A partial-thickness dissection may then be carried out on the buccal aspect of the flap. For patients in which an onlay block graft was to be performed simultaneously, the flap

was of full thickness at both the crest and the vestibular [Au: Buccal? Labial?] area.

On the palate, a paramarginal reversed bevel incision was made 2 mm away from the gingival margin^{8,9} to a depth of approximately 1 mm. The posterior limit should not exceed the first molar area. At this point, a small distal releasing incision was made to facilitate elevation of the connective tissue flap.²² Once a partial-thickness flap was dissected, two incisions were made parallel to the gingival margin to the level of the bone; one distal incision was made perpendicular to the gingival margin. The flap must not be made narrower than 5 mm.¹² This connective tissue flap was then elevated, rotated, and sutured to the buccal flap (Fig 2). A metaplasia then

occurred, maintaining the capacity of the flap to form keratinized epithelium, which was seen at 10 days.

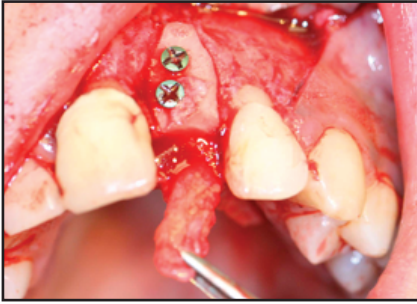


Fig 3a (left) *Partial-thickness palatal flap with simultaneous onlay bone grafting.*

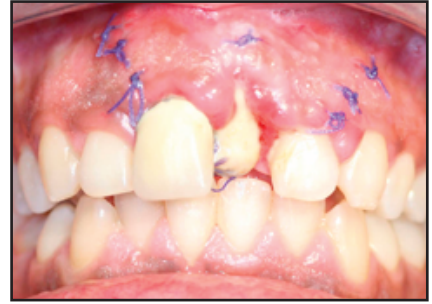

Fig 3b (right) *Flap necrosis resulted because the patient was a heavy smoker.*

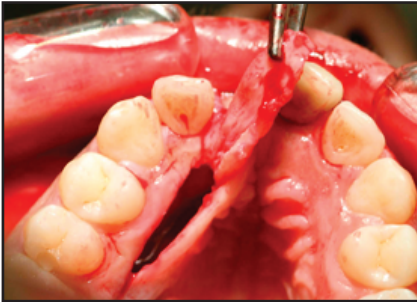


Fig 3c (left) *After 3 months, another flap was raised. Note the more fibrous tissue.*

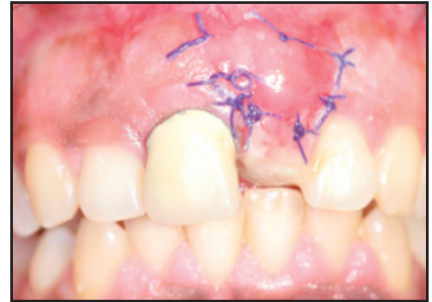
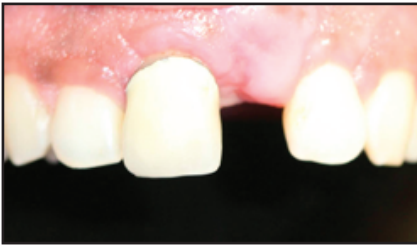
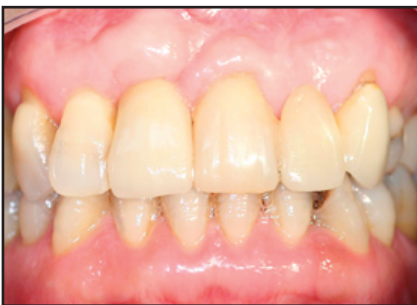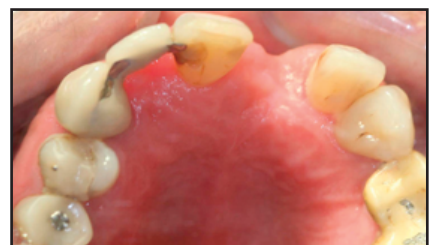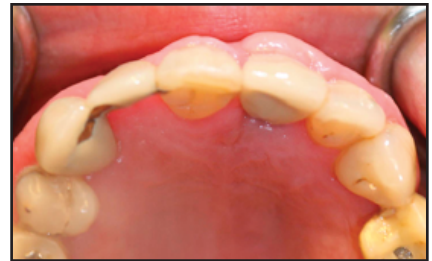Fig 3d (right) *Seven days postoperative; re-epithelialization has begun.*



Figs 3e and 3f (e, left) *Frontal and (f, right) occlusal views of the recipient site [Au: How long after surgery? No figure legend provided.]*



Figs 3g and 3h *Final (g, left) frontal and (h, right) occlusal views after prosthesis delivery at 5 months postoperative. Great soft tissue volume was achieved.*



Results

A palatal flap was raised to gain buccal gingival thickness and improve esthetics in implants with an incorrect angulation in two patients. One patient presented buccal gingival recession after several bone reconstructive surgeries at a central incisor site that had led to a poor implant esthetic outcome. Another patient received an immediate implant. An allograft was placed in the gap for this patient. Four patients suffered atrophies that required bone grafting, and one patient wanted to improve the esthetics of a current fixed partial denture. [Au: Correct?]

One patient, who was a heavy smoker, suffered flap necrosis. After 3 months of smoking habit elimination, another flap from the same palatal location was raised successfully (Fig 3). So far, the authors have not found any literary reference of two consecutive flaps on the same location. Flap necrosis was also observed in another patient, probably related to an extraction history with the two included maxillary canines. This could explain possible previous damage to the incisive vessels.

Discussion

Anterior maxillary edentulism is one of the biggest challenges in implantology. Bone atrophy often leads to improper implant positioning. Insufficient bone volume is also frequently related to a lack of keratinized gingiva. Many techniques have been proposed to improve the soft tissue condition, such as free grafts,^{7,8} palatal roll flaps,^{17,23} or palatal mucosal flaps.¹²⁻¹⁵ Most flaps raised in this region are confined to the anterior palate, where thickness is often limited. This problem increases the complexity of the treatment, while in the posterior region, mucosal thickness allows the use of much more tissue.²⁴

The palatal connective tissue flap allows for a lot of volume, which is useful for esthetics. It is also useful for covering bone grafts. In certain patients, this technique can also shorten the total treatment time, since a secondary soft tissue grafting procedure is seldom required.

This flap is incisive vessel-based, which could explain the minimized contraction seen compared to free grafts.¹⁹ The exposed connective tissue will re-epithelialize with keratinized tissue in all patients undergoing this treatment.

In the authors' experience, minor complications, such as donor site dehiscences, have occurred in 9 of 10 cases. In 2 cases, flap necrosis occurred, 1 of which was performed in a heavy smoker. These findings are in agreement with that described by Khoury and Happe.¹⁸ After smoking cessation, a flap was again raised from the same palatal region successfully. Another instance of flap necrosis was seen in a patient who had a history of maxillary canine extraction. However, Sclar¹⁹ did not describe any necrosis complications. In the authors' experience, care should be taken when treating a patient with a smoking habit or previous maxillary surgery, especially in the palate.

One important limitation is related to the shape of the palatal vault. In shallow palates, the neurovascular bundle is located closer to the gingival margin.²⁰ This limitation will result in a narrower flap. Also, a high, steep palatal vault tends to be thinner.

If the indication for the flap is strictly to improve esthetics, then a partial-thickness flap on the vestibular [Au: Buccal? Labial?] aspect of the flap [Au: Recipient site?] can be made. If an implant is to be placed, then the flap should be of full thickness at the crest, and on the buccal aspect, a partial-thickness dissection may be carried out. If an onlay bone graft is to be placed at the time of surgery, the flap must be of full thickness at both the buccal and crestal aspects. This type of palatal flap approach eliminates the need for coronal advancement of the buccal flap. This prevents misplacement of the mucogingival junction and shorten-

ing of the vestibule.

Conclusion

This is a versatile and useful technique that yields a large amount of soft tissue. Minor complications such as dehiscences in the palate are encountered frequently, although flap necrosis should be taken into account. Anatomy of the palate must be considered before surgery.

Acknowledgment

The authors wish to thank Santiago Mareque for his kind help in translating this paper.

References

1. Steiner GG, Francis W, Burrell R, Kallet MP, Steiner DM, Macias R. The healing socket and socket regeneration. *Compend Contin Educ Dent* 2008;29:114–116, 118.
2. Seibert JS. Reconstruction of the partially edentulous ridge: Gateway to improved prosthetics and superior aesthetics. *Pract Periodontics Aesthet Dent*. 1993;5:47–55.
3. Wang HL, Al-Shammari K. HVC ridge deficiency classification: A therapeutically oriented classification. *Int J Periodontics Restorative Dent* 2002;22:335–343.
4. Azzi R, Etienne D, Takei H, Fenech P. Surgical thickening of the existing gingiva and reconstruction of interdental papillae around implant-supported restorations. *Int J Periodontics Restorative Dent* 2002;22:71–77.
5. Chiapasco M, Abati S, Romeo E, Vogel G. Clinical outcome of autogenous bone blocks or guided bone regeneration with e-PTFE membranes for the reconstruction of narrow edentulous ridges. *Clin Oral Implants Res* 1999;10:278–288.

6. Fagan MC, Miller RE, Lynch SE, Kao RT. Simultaneous augmentation of hard and soft tissues for implant site preparation using recombinant human platelet-derived growth factor: A human case report. *Int J Periodontics Restorative Dent* 2008;28:37–43.
7. Langer B, Langer L. Subepithelial connective tissue graft technique for root coverage. *J Periodontol* 1985;56:715–720.
8. Langer B, Calagna LJ. The subepithelial connective tissue graft. A new approach to the enhancement of anterior cosmetics. *Int J Periodontics Restorative Dent* 1982;2:22–33.
9. Harris RJ. Soft tissue ridge augmentation with an acellular dermal matrix. *Int J Periodontics Restorative Dent* 2003;23:87–92.
10. Harris RJ. Gingival augmentation with an acellular dermal matrix: Human histologic evaluation of a case—Placement of the graft on periosteum. *Int J Periodontics Restorative Dent* 2004;24:378–385.
11. Barone R, Clauser C, Prato GP. Localized soft tissue ridge augmentation at phase 2 implant surgery: A case report. *Int J Periodontics Restorative Dent* 1999;19:141–145.
12. Nemcovsky CE, Artzi Z, Moses O, Gelernter I. Healing of dehiscence defects at delayed-immediate implant sites primarily closed by a rotated palatal flap following extraction. *Int J Oral Maxillofac Implants* 2000;15:550–558.
13. Nemcovsky CE, Moses O. Rotated palatal flap. A surgical approach to increase keratinized tissue width in maxillary implant uncovering: Technique and clinical evaluation. *Int J Periodontics Restorative Dent* 2002;22:607–612.
14. Nemcovsky CE, Artzi Z. Split palatal flap. II. A surgical approach for maxillary implant uncovering in cases with reduced keratinized tissue: Technique and clinical results. *Int J Periodontics Restorative Dent* 1999;19:385–393.
15. Nemcovsky CE, Artzi Z. Split palatal flap. I. A surgical approach for primary soft tissue healing in ridge augmentation procedures: Technique and clinical results. *Int J Periodontics Restorative Dent* 1999;19:175–181.
16. Peñarrocha M, García-Mira B, Martínez O. Localized vertical maxillary ridge preservation using bone cores and a rotated palatal flap. *Int J Oral Maxillofac Implants* 2005;20:131–134.
17. Block MS. De-epithelialized connective tissue pedicle graft: The palatal roll. *Atlas Oral Maxillofac Surg Clin North Am* 1999;7:109–116.
18. Khoury F, Happe A. The palatal subepithelial connective tissue flap method for soft tissue management to cover maxillary defects: A clinical report. *Int J Oral Maxillofac Implants* 2000;15:415–418.
19. Sclar. *Soft Tissues and Esthetic Considerations in Implant Therapy*. Chicago: Quintessence, 2003:163–187.
20. Reiser GM, Bruno JF, Mahan PE, Larkin LH. The subepithelial connective tissue graft palatal donor site: Anatomic considerations for surgeons. *Int J Periodontics Restorative Dent* 1996;16:130–137.
21. Carnio J, Hallmon WW. A technique for augmenting the palatal connective tissue donor site: Clinical case report and histologic evaluation. *Int J Periodontics Restorative Dent* 2005;25:257–263.
22. Liu CL, Weisgold AS. Connective tissue graft: A classification for incision design from the palatal site and clinical case reports. *Int J Periodontics Restorative Dent* 2002;22:373–379.
23. Israelson H, Plemons JM. Dental implants, regenerative techniques, and periodontal plastic surgery to restore maxillary anterior esthetics. *Int J Oral Maxillofac Implants* 1993;8:555–561.
24. Studer SP, Allen EP, Rees TC, Kouba A. The thickness of masticatory mucosa in the human hard palate and tuberosity as potential donor sites for ridge augmentation procedures. *J Periodontol* 1997;68:145–151.

[Au: Figures were not called out in the text. Please confirm the location of all callouts and revise/add as necessary.]