

Reconstructive Surgery

Minimal incision in parotidectomy

C. Martí-Pagès, E. García-Díez, L. García-Arana, D. Mair, M^a. J. Biosca, X. Gimeno-Medina, F. Hernández-Alfaro: Minimal incision in parotidectomy. *Int. J. Oral Maxillofac. Surg.* 2007; 36: 72–76. © 2006 Published by Elsevier Ltd on behalf of International Association of Oral and Maxillofacial Surgeons.

**C. Martí-Pagès, E. García-Díez,
L. García-Arana, D. Mair,
M^a. J. Biosca, X. Gimeno-Medina,
F. Hernández-Alfaro**

International University of Catalonia,
Department of Oral and Maxillofacial Surgery,
General Hospital of Catalonia and Institute of
Oral and Maxillofacial Surgery, Teknon
Medical Center, Barcelona, Spain

Abstract. Conservative parotidectomy has been for years an effective and well-established technique. Recently, aesthetic considerations have been reviewed. A minimal pre- and retroauricular incision is proposed that does not extend to the hair-bearing skin. This reduces the length of the scar and the extent of the dissection improving aesthetic results. This is a retrospective study of 32 parotidectomies performed through this incision because of benign parotid diseases and diagnosed by fine needle aspiration cytology. The minimal incision is mainly indicated in small and medium-sized tumours located in the superficial lobe of the parotid gland. Neither operating time nor the morbidity associated with parotidectomy is increased with this safe and effective technique for the treatment of benign parotid masses.

Accepted for publication 6 September 2006

Conservative parotidectomy is an effective and well-established technique for the treatment of parotid gland pathology^{15,16}, but there are complications such as visible scars, retromandibular depression, Frey's syndrome and facial nerve injury. Recently, aesthetic considerations for this area of surgery have been reviewed. The facelift incision improves scar appearance compared to the classic bayonet-shaped incision by eliminating its cervical portion, although it maintains an often-visible occipital scar^{3,7,18}. The superficial musculoaponeurotic system (SMAS) flap helps to maintain facial symmetry, dissimulating the post-parotidectomy retromandibular depression⁶. The incidence of Frey's syndrome has been reduced due to this flap^{2,6}. Alternatives such as sternocleidomastoid muscle transposition³ and the temporoparietal fascial flap² have been described.

One of the main objectives in treating benign pathology of the parotid gland is

preservation of the facial nerve. Recently, limited resections, with safety margins, have been proposed, but are still subject to controversy. Such resections diminish surgical trauma to the nerve, improve aesthetic results and maintain the oncologic quality of the surgery^{5,13}. Proposed here is a minimal pre- and retroauricular incision with no extension to the hair-bearing skin to improve the parotidectomy approach with three objectives: to reduce dissection of areas situated out of the surgical field, shorten the approach time and diminish postoperative complications.

Patients and methods

The mini-incision has been performed from July 2003 until July 2005 in all cases of parotidectomy due to benign parotid lump, tumoural or not tumoural, and any size and localization, with diagnosis by fine-needle aspiration cytology (FNAC). All cases were performed by the oral and

maxillofacial surgeons at the Teknon Medical Center (Barcelona, Spain) and Hospital General de Catalunya (Barcelona, Spain).

This is a retrospective study of the first 31 consecutive patients operated on using this technique. Factors recorded preoperatively were age, gender and parotid gland affected (left or right). Preoperative study included FNAC and a radiological evaluation of the lesion either by computerized tomography or magnetic resonance. Incision length, operating time, complications, specimen size and pathology diagnosis were recorded.

Surgical technique

Surgery is performed under general anaesthesia. The minimal incision is drawn with an indelible pen. Then the subcutaneous plane is infiltrated with local anaesthesia plus vasoconstrictor (articaine 40 mg and epinephrine 0.01 mg). Incision starts at the

helix insertion and is carried out along the internal face of the tragus (Fig. 1). It continues inferiorly anterior to the ear and is curved, separated by 1 mm from the lobule. The incision rises 2 mm away from the crease behind the conchal cartilage and ends at the level of the middle of the ear (Fig. 2).

Dissection of the parotid skin flap in the subcutaneous plane is then performed (Fig. 3) by undermining of the anterior cervical skin and the superior sternomastoid muscle's insertion. The posterior branch of the greater auricular nerve is identified and preserved. Afterwards, a SMAS flap is elevated antero-inferiorly beginning its dissection 1 cm below the zygomatic arch to the anterior border of the parotid gland. At this point it is important not to damage the terminal branches of the facial nerve that appear in the anterior aspect of the parotid gland. The inferior and posterior limits of the SMAS flap are generally determined by the anterior border of the sternomastoid muscle and the greater auricular nerve.

Once the SMAS flap is elevated the complete parotid gland is exposed surrounded by the parotid fascia (Fig. 4). Parotidectomy proceeds according to the classical technique: the facial nerve's main trunk is identified by dissecting the pretragal cartilage down to the 'pointer' and the anterior border of the sternocleidomastoid muscle down to the posterior belly of the digastric muscle⁴. Both reference points facilitate the identification of the facial nerve main trunk. Dissection of the nerve branches is then performed carrying out the conservative parotidectomy (Fig. 5).

Haemostasis is revised and the SMAS flap is repositioned (Fig. 6) in a tent fashion, folding its excess so that the parotid bed is filled. A vacuum drain is placed. The incision is closed in two layers. Vicryl[®] is used subcutaneously and resorbable monofilament is used in a running intradermic fashion. The drain is usually removed after 24 h. The incision, if necessary, can be extended easily in two ways: through the hair as in the rhytidectomy technique; or by extending the retroauricular incision through the hair-line and cervical region as with the classic bayonet-shaped incision.

Results

A total of 32 parotidectomies were performed in 31 patients (21 female/10 male). Patient age ranged between 26 and 78 years (mean 43 years). Twenty-eight par-

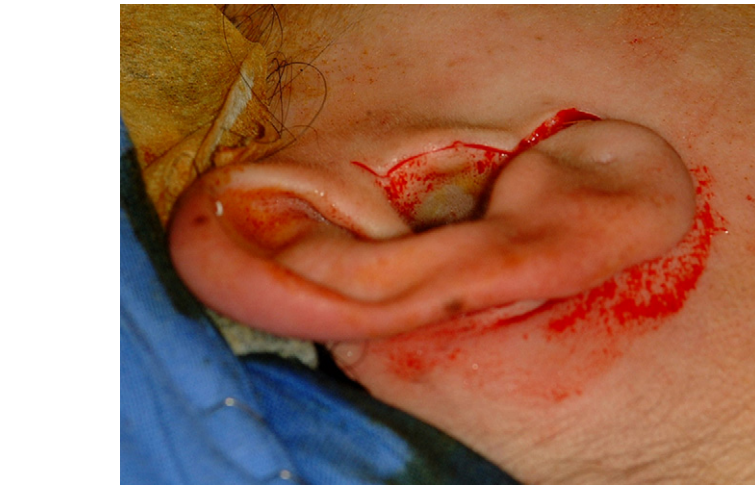

Fig. 1. Preauricular incision.

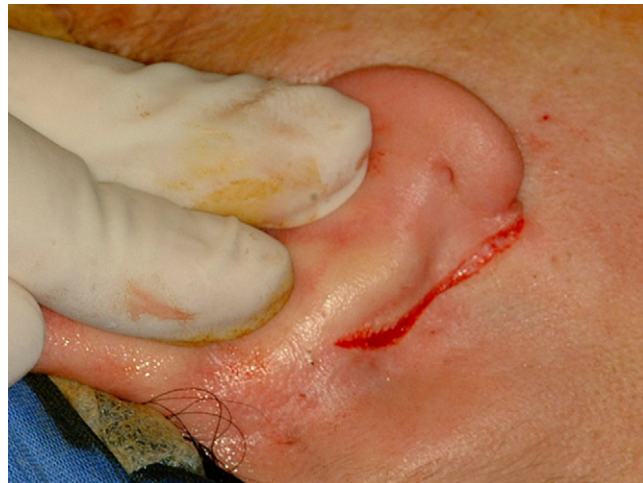

Fig. 2. Retroauricular incision.

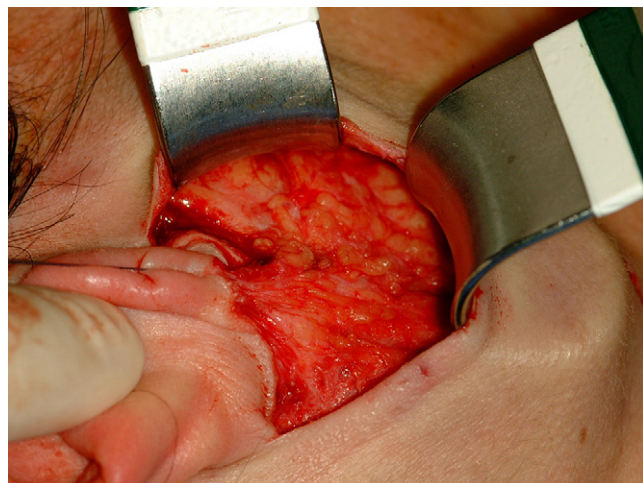


Fig. 3. Dissection of the skin flap in the subcutaneous plane.

otidectomies (28 patients) were carried out because of a benign tumoural disease and four parotidectomies (three patients) because of a non-tumoural disorder.

Sixteen superficial parotidectomies, 11 partial parotidectomies, four total parotidectomies (two cases with extension to parapharyngeal space and two cases with

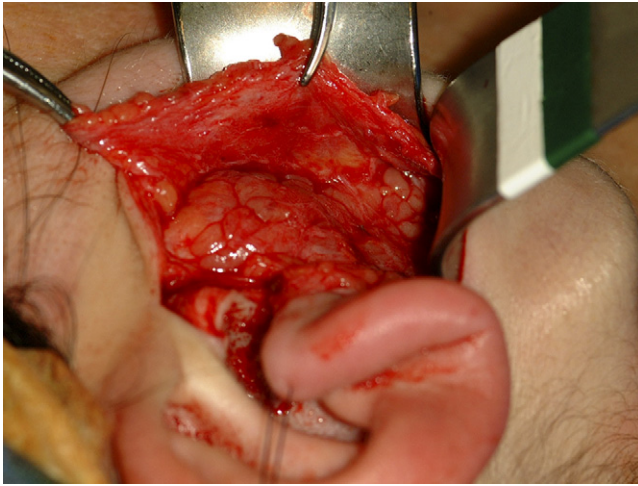


Fig. 4. Elevated SMAS flap and exposed parotid gland.

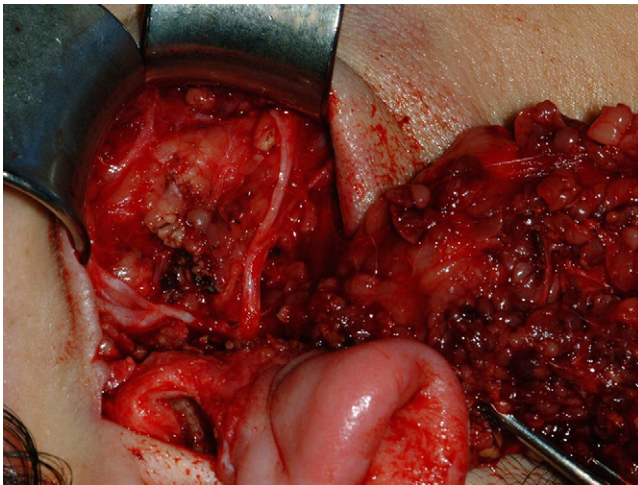


Fig. 5. Dissection of the facial nerve branches and resection piece.

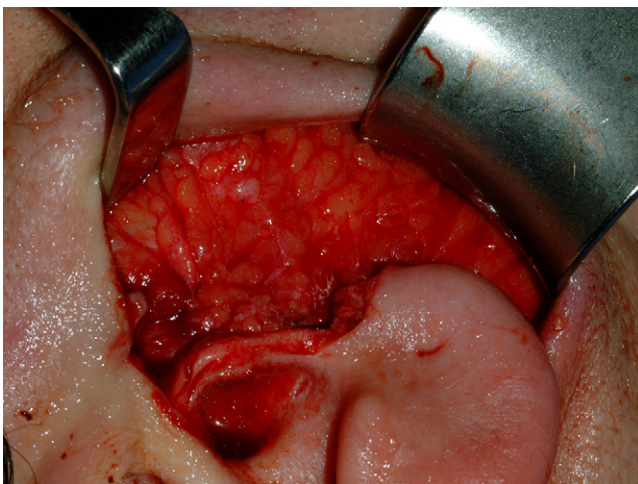


Fig. 6. Reconstruction of postparotidectomy defect with SMAS flap.

facial nerve retrograde dissection) and one accessory parotid gland resection were carried out. Histopathologic diagnosis was: 20 pleomorphic adenomas, three warthin tumours, two benign lymphoepithelial lesions, one lymphoma of mucosa-associated lymphoid tissue, one choristoma, one adenopathy, one chronic sialadenitis due to intraglandular lithiasis, one bilateral sialosis in an ex-bulimic patient and one Sjögren's syndrome.

The average length of the incision was 60.2 mm (range 50–75), and the mean operating time was 115 min (range 70–180). Mean size of the specimens was 51 mm × 36 mm × 20 mm (range 20 mm × 15 mm × 6 mm–85 mm × 45 mm × 80 mm) and the mean size of the tumours was 21 mm × 15 mm (range 10 mm × 8 mm–60 mm × 40 mm). In no cases were tumour capsule ruptures found.

Postoperative complications were two haematomas that required surgical drainage (one of them by open drainage, and the other one by needle aspiration), two seromas that required puncture and 13 cases of transient facial nerve dysfunction. There has been no permanent facial nerve dysfunction and no patient has presented with clinical Frey's syndrome to date. Data were collected from surveys of the patients and from medical records. Aesthetic results were very/extremely satisfactory. There have been no alterations in relation to the scars. Symmetry of the cheeks was completely restored except for a minimum retromandibular depression in the seven patients that presented the largest tumours and those with a deep-lobe tumour.

Discussion

Parotidectomy has been classically performed through a bayonet-shaped incision without parotid bed reconstruction. This approach allows quick and wide access for dissection of the facial nerve and eases parotid gland removal, but is associated with visible cervical scarring, retromandibular depression and Frey's syndrome. These three drawbacks have led to the development of alternative approaches based on the facelift incision^{7,18} and SMAS flap⁶.

Numerous studies support the theory that the rhytidectomy incision provides sufficient exposition and visualization of the parotid gland without too conspicuous scarring⁷. The retroauricular region dissection is unnecessary owing to the elastic properties of the skin, so it is possible to reduce the incision with no extension into the scalp. This minimal incision provides a

wide exposition that allows easy elevation of the SMAS flap and safe treatment of parotid tumours of small and medium size, located in the superficial lobe of the parotid gland, around the ear. Recently, a similar incision has been proposed to assist in face lifts¹⁹.

With this technique placing incisions in the hairline is avoided, eliminating the risk of hypertrophic scars (Fig. 7), distortions in the hairline and local alopecia in the occipital area, a complication that is reported to be 2.8%¹⁴. An important advantage is the possibility to extend the incision in two different ways: extending through the rhytidectomy incision increases the surgical field very slightly but gives a good aesthetic result, hiding the incision in the hair. If a wider surgical field is needed, the extension can be made through the cervical region, leaving a more visible scar. Minimal incision is not the goal of treatment but rather a safe parotidectomy, with a good view of the facial nerve, removing the tumour with safety margins and avoiding capsule rupture and tumour spillage.

We agree with most authors in recommending the SMAS flap elevation since it helps to prevent Frey's syndrome, avoids a sunken facial appearance and better outlines the angle of the mandible^{1,2,11,12}. We routinely use the SMAS flap except in superficial tumours affecting the SMAS itself, where we make partial resections of the SMAS with the tumour. Most of the patients (72.8%) were satisfied with the aesthetic outcome (Fig. 8a and b). Only patients (21.8%, seven patients) with deep-lobe and the largest tumours presented a slight retromandibular depression. There are alternatives to filling the parotid bed postparotidectomy, including the sternocleidomastoid muscle flap³, digastric muscle flap⁵ and temporoparietal fascial flap^{2,8,17}. These are indicated only if the SMAS is not available.

With this conservative approach limited, superficial and in selected cases total parotidectomies can be safely performed, and it also provides limited access to the parapharyngeal space without increasing the risk of injuring the facial nerve. In the present series, 40.6% of patients suffered temporal facial paralysis. All of them completely recovered within the first two postoperative months, with no permanent injury to the nerve. MEHLE et al.¹⁰ reported immediate dysfunction in 46.1%, with permanent palsy in 3.9%. They showed that the incidence of long-term dysfunction was higher in revision cases and when an extended parotidectomy was performed. LACCOURREYE et al.⁹ presented

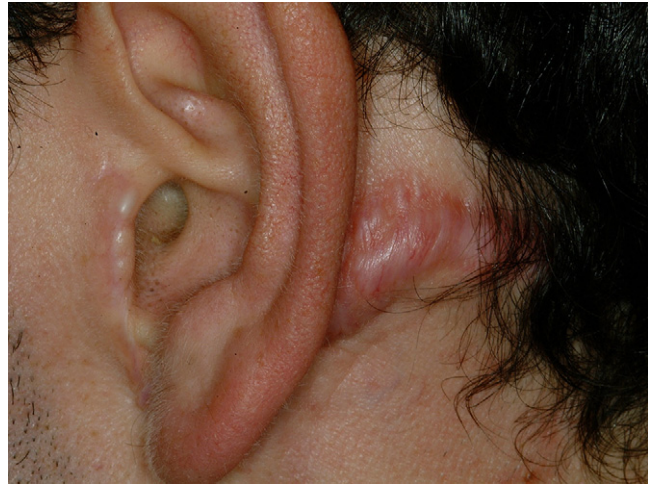

Fig. 7. Occipital keloid of facelift incision for parotidectomy.

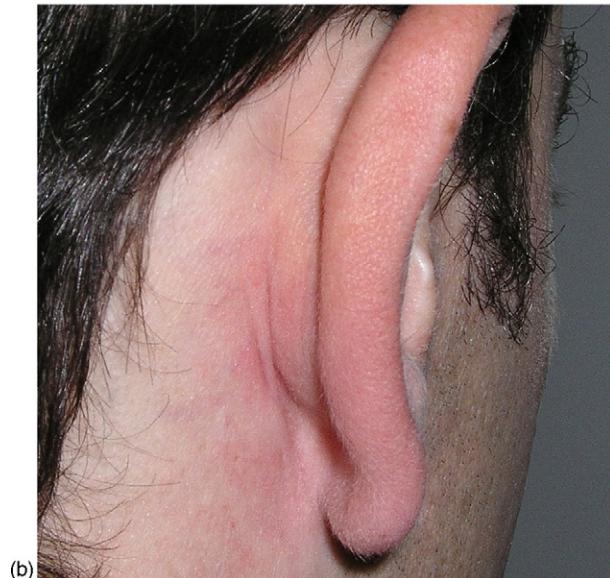
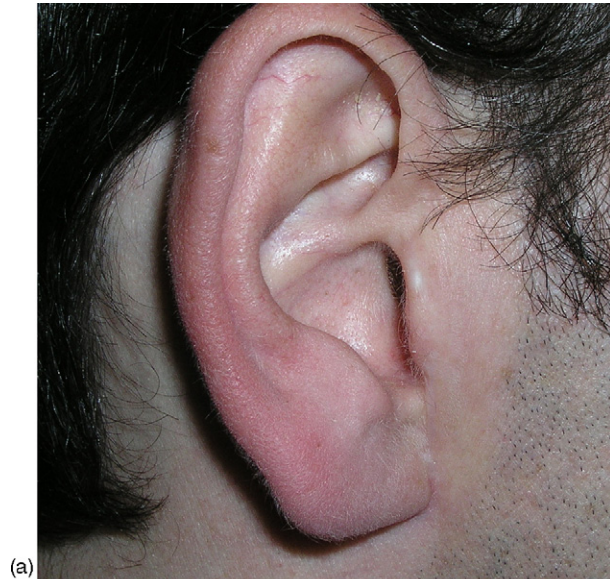
Fig. 8. (a and b). Scar 2 years after parotidectomy.

a large series in which temporal dysfunction was frequently encountered (64.6%) but permanent dysfunction was uncommon (5.6%). O'BRIEN¹³ in 363 parotidectomies following these criteria reported temporary postoperative facial weakness in 27%, with permanent weakness in 2.5%.

References

- BONANNO PC, PALAIA D, ROSENBERG M, CASSON P. Prophylaxis against Frey's syndrome in parotid surgery. *Ann Plast Surg* 2000; **44**: 498–501.
- CESTELEYN L, HELMAN J, KING S, VAN DE VYVERE G. Temporoparietal fascia flaps and superficial musculoaponeurotic system placcation in parotid surgery reduces Frey's syndrome. *J Oral Maxillofac Surg* 2002; **60**: 1284–1297.
- CHOW TL, LAM CYW, CHIU PWY, LIM BH, KWOK SPY. Sternomastoid-muscle transposition improves the cosmetic outcome of superficial parotidectomy. *Br J Plast Surg* 2001; **54**: 409–411.
- GUERRIER Y. Chirurgie de glandes salivaires. In: Masson, ed: *Traité de Technique Chirurgicale ORL et Cervicofaciale*. 10th edn. Tome 4ème: cou et cavité bucale 1988: 200–201.
- HELMUS C. Conservative versus superficial parotidectomy for benign lesions of the parotid tail. *Arch Otolaryngol Head Neck Surg* 1999; **125**: 1166–1167.
- HÖNIG JF. Facelift approach with hybrid SMAS rotation advancement flap in parotidectomy for prevention of scars and contour deficiency affecting the neck and sweat secretion of the cheek. *J Craniofac Surg* 2004; **15**: 797–803.
- HÖNIG JF. Omega incision face-lift approach and SMAS rotation advancement flap in parotidectomy for prevention of scars affecting the neck. *Int J Oral Maxillofac Surg* 2005; **34**: 612–618.
- JOST G, GUENON PH, GENTIL S. Parotidectomy: a plastic approach. *Aesthetic Plast Surg* 1999; **23**: 1–4.
- LACOURREYE H, LACOURREYE O, CAUCHOIS R, JOUFFRE V, MÉNARD M, BRASNU D. Total conservative parotidectomy for primary benign pleomorphic adenoma of the parotid gland: a 25-year experience with 229 patients. *Laryngoscope* 1994; **104**: 1487–1494.
- MEHLE ME, KRAUS DH, WOOD BG, BENNINGER MS, ELIACHAR I, LEVINE HL, TUCKER HM, LAVERTU P. Facial nerve morbidity following parotid surgery for benign disease: the Cleveland Clinic Foundation experience. *Laryngoscope* 1993; **103**: 386–388.
- MENINGAUD JP. Parotidectomy: the face-lift access route. *EMC Stomatol* 2005; **1**: 80–84 in French.
- MOULTON-BARRET R, ALLISON G, RAPAPORT I. Variations in the use of SMAS (Superficial musculoaponeurotic system) to prevent Frey's syndrome after parotidectomy. *Int Surg* 1996; **81**: 174–176.
- O'BRIEN CJ. Current management of benign parotid tumours. The role of limited superficial parotidectomy. *Head Neck* 2003; 946–952.
- PARKES ML, KAMER FM, BASSILIOS MI. Treatment of alopecia in temporal region following rhytidectomy procedures. *Laryngoscope* 1977; **87**: 1011–1014.
- PATEY DH, THACKRAY AC. The treatment of parotid tumours in the light of a pathological study of parotidectomy material. *Br J Surg* 1958; **55**: 477–487.
- ROSCIC Z. Conservative parotidectomy: a new surgical concept. *J Maxillofac Surg* 1980; **8**: 234–240.
- SULTAN MR, WIDER TM, HUGO NE. Frey's syndrome: prevention with temporoparietal fascial flap interposition. *Ann Plast Surg* 1995; **34**: 292–296.
- TERRIS DJ, TUFO KM, FEE Jr WE. Modified facelift incision for parotidectomy. *J Laryngol Otol* 1994; **108**: 574–578.
- ZAGER WH, DYER WK. Minimal incision facelift. *Fac Plast Surg* 2005; **21**: 21–27.

Address:

Carlos Martí Pagès
Teknon Medical Center
Calle Vilana 12
Consultorios Vilana
despacho 185
08022 Barcelona
Spain
Tel.: +34 93 393 3185
Fax: +34 93 393 3085
E-mail: secretaria@institutomaxilofacial.com