

Clinical Paper
 Orthognathic Surgery

On a definition of the appropriate timing for surgical intervention in orthognathic surgery

**F. Hernández-Alfaro^{1,2},
 R. Guijarro-Martínez^{1,2}**

¹Institute of Maxillofacial Surgery, Teknon Medical Centre Barcelona, Barcelona, Spain;
²Department of Oral and Maxillofacial Surgery, Universitat Internacional de Catalunya, Sant Cugat del Vallés, Barcelona, Spain

F. Hernández-Alfaro, R. Guijarro-Martínez: On a definition of the appropriate timing for surgical intervention in orthognathic surgery. Int. J. Oral Maxillofac. Surg. 2014; xxx: xxx–xxx. © 2014 International Association of Oral and Maxillofacial Surgeons. Published by Elsevier Ltd. All rights reserved.

Abstract. Together with the introduction of new orthodontic techniques and minimally invasive surgery protocols, the emergence of modern patient prototypes has given way to novel timing schemes for the handling of dento-maxillofacial deformities. The aim of this study was to define, justify, and systematize the appropriate timing for orthognathic surgery. A retrospective analysis of orthognathic surgery procedures carried out over a 3-year period was performed. Six timing schemes were defined: ‘surgery first’, ‘surgery early’, ‘surgery late’, ‘surgery last’, ‘surgery only’, and ‘surgery never’. Gender, age at surgery, main motivation for treatment, orthodontic treatment length, and number of orthodontic appointments were evaluated. A total of 362 orthognathic procedures were evaluated. The most common approach was ‘surgery late’. While aesthetic improvement was the leading treatment motivation in ‘surgery first’, ‘surgery early’, and ‘surgery last’ cases, occlusal optimization was the chief aim of ‘surgery late’. Sleep-disordered breathing was the main indication for treatment in ‘surgery only’. Compared to ‘surgery late’, orthodontic treatment was substantially shorter in ‘surgery early’ and ‘surgery first’ cases, but the number of orthodontic appointments was similar. In conclusion, the skilful management of dento-maxillofacial deformities requires a comprehensive analysis of patient-, orthodontist-, and surgeon-specific variables. Each timing approach has well-defined indications, treatment planning considerations, and orthodontic and surgical peculiarities.

Keywords: orthognathic surgery; timing; surgery first; dentofacial anomalies; malocclusion.

Accepted for publication 17 February 2014

During the last decade, treatment concepts in orthognathic surgery have undergone a profound reassessment. In particular, the traditional therapeutic scheme based on a variable length of preoperative orthodontic preparation, surgery itself, and a relatively stable period of postoperative orthodontics,

has given way to a new trend in surgical timing that entails the performance of the surgical intervention prior to orthodontic treatment.^{1–7} The so-called ‘surgery first’ approach has gained popularity among orthodontists and surgeons for several reasons. First, the skeletal bases – and there-

fore the aesthetic concern, which is often the patient’s chief complaint – are corrected from the beginning.^{1,6} This circumstance improves patient compliance with post-operative orthodontics and makes a powerful contribution to global satisfaction with treatment.⁵ Second, orthodontic treatment

2 Hernández-Alfaro and Guijarro-Martínez

– and hence total treatment time – is significantly reduced. This improved orthodontic efficiency is probably related to the transient demineralization of the operated bones due to the regional acceleratory phenomenon (RAP)^{1,2,7–11} and to a more efficient skeletal position in which soft tissue imbalances that can interfere with orthodontic movements have been suppressed.⁷ Third, when compared to the conventional orthodontics–surgery–orthodontics approach, a ‘surgery first’ protocol does not seem to impair the final occlusal result. Consequently, the satisfaction of orthodontists and patients with the treatment is at least as high as with the traditional timing scheme.⁵

The ‘surgery first’ concept was implemented at our centre in 2010. After documenting our preliminary experience with this approach,^{1,5} we realized that a significant number of patients did not fall into this ‘black or white’ (traditional approach vs. ‘surgery first’ approach) classification. Indeed, several patients were operated on at different time-points along the orthodontic treatment timeline. After a comprehensive analysis of the indications and limitations of these different timing schemes, the aim of this study was to define, justify, and subsequently systematize the appropriate timing for surgical intervention in the context of dento-maxillofacial deformities.

Materials and methods

A retrospective analysis of all orthognathic surgery procedures performed at a specialized centre in dento-maxillofacial anomalies during a 3-year time period (June 2010 to June 2013) was performed.

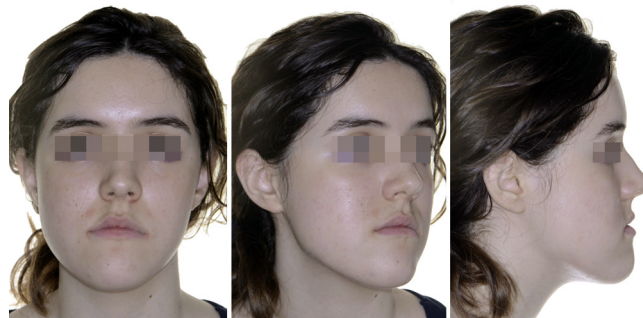

Fig. 1. Case example 1: Frontal, three-quarter, and profile views of a patient treated with a ‘surgery first’ approach. The patient’s main motivation for surgery was her wish to correct her facial asymmetry and concave profile.

The guidelines of the Declaration of Helsinki on medical protocol and ethics were followed in all treatment phases. Patient clinical records and media files were reviewed with the approval of the institutional medical centre committee on ethical medical practice.

Patients were classified according to the time at which the surgical intervention took place with regards to orthodontic treatment. The categories were established as outlined below.

Surgery first

By definition, this approach proceeds with orthognathic surgery without preoperative orthodontic preparation and is followed by regular postoperative dental alignment. Our particular methodology has been described in detail elsewhere.⁵

Patients were selected for a ‘surgery first’ sequence on the basis of a skeletal malocclusion requiring combined orthodontic–surgical treatment without extractions, the need for aesthetic

improvement, or sleep-disordered breathing (SDB) as the main motivation for treatment. Orthodontic management was performed by an officially qualified orthodontist with previous experience in orthognathic surgery. Exclusion criteria were as follows: severe crowding in need of extractions, severe asymmetry with three-dimensional (3D) dental compensations, transverse maxillary hypoplasia requiring previous surgically-assisted rapid palatal expansion (SARPE), class II second division with overbite, acute periodontal problems, and underlying temporomandibular joint (TMJ) disease (Figs 1 and 2).

As well as routine virtual planning of the orthognathic osteotomies, the necessary dental movements of the future orthodontic treatment were simulated in a 3D virtual orthodontic setup for this group of patients. This was built by the combined orthodontic–surgical team (Fig. 3).

Brackets (without archwires) were bonded 1 week before surgery. In order to avoid dental movements that could

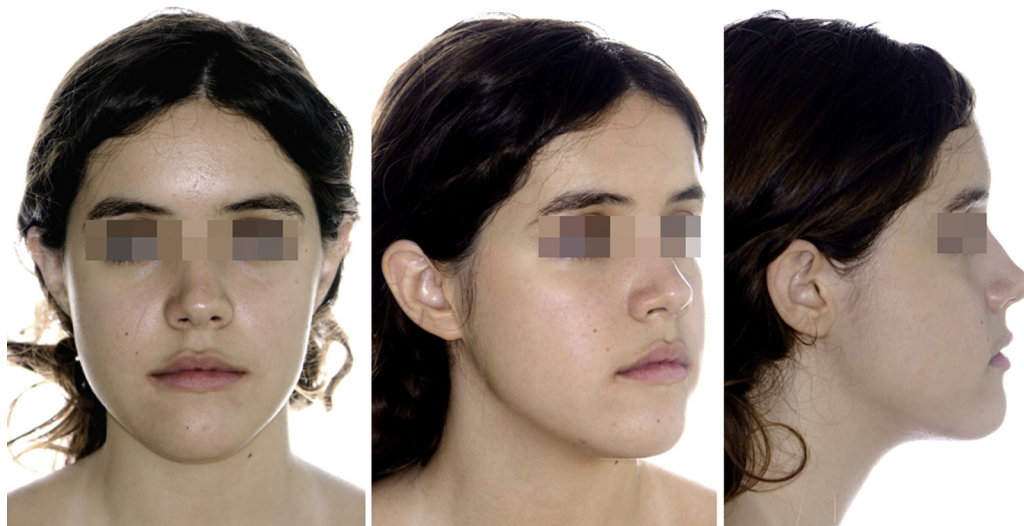

Fig. 2. Case example 1: Frontal, three-quarter, and profile views after surgery.

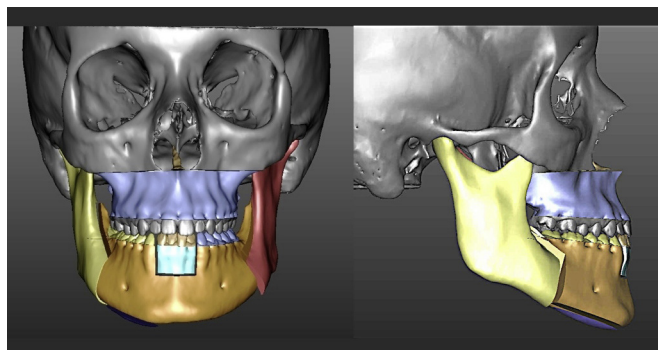


Fig. 3. Case example 1: Simulation of skeletal movements and virtual orthodontic setup. Bimaxillary surgery with 6-mm maxillary advancement, mandibular midline correction, and mandibular front-block osteotomy for incisor decompensation were planned.

render the computer assisted design–computer assisted manufacturing (CAD–CAM) splint inaccurate and thus interfere with proper bone positioning, the first soft archwire was not placed until 24 h before surgery or even until the first postoperative orthodontic appointment at 1–2 weeks after surgery.

In addition to the standard maxillary and mandibular osteotomies, interdental corticotomies were systematically executed with a piezoelectric microsaw in order to accelerate postoperative orthodontic movement owing to the RAP^{9,11–13} (Fig. 4). These corticotomies were extended through the entire thickness of the buccal cortical layer and interrupted when penetrating the medullary bone. No luxation manoeuvres followed. Whenever the targeted teeth were not accessible through the incision required for the orthognathic procedure itself, a tunnel approach under endoscopic assistance was used. This tunnel approach was performed through one to three buccal vertical incisions (5–10 mm) per arch in order to minimize soft tissue debridement and periodontal risks. The technical details of this particular method are available elsewhere.¹³

Orthodontic treatment began at the end of the second postoperative week in order to benefit from the RAP. Archwires were changed every second to third week. During the first postoperative month, intraoperatively placed miniscrews were used for skeletal anchorage, thereby avoiding premature loading of the orthodontic appliances and undesirable dental extrusions⁵ (Fig. 5).

Surgery early

Patients were selected for a ‘surgery early’ approach when the aforementioned selection criteria for ‘surgery first’ were not completely met, despite the patient’s wish

for an immediate aesthetic change. With this treatment concept, the presence of severe crowding in need of extractions and complex 3D dental compensations due to facial asymmetry, including dental midline deviation, required at least partial orthodontic preparation. As soon as the severe crowding had been managed with extractions and a good amount of the necessary space closure was achieved, surgery was performed. In the case of severe 3D compensations and/or dental midline deviations, surgery proceeded once transverse compensations were resolved.

Regarding treatment planning, the surgery itself, and the postoperative orthodontic treatment, the same methodology as for ‘surgery first’ was followed. In other words, virtual planning included both osteotomy simulation and 3D orthodontic setup. Intraoperatively, the regular facial osteotomies were followed by interdental corticotomies in order to further enhance the RAP, and miniscrews were placed for intraoperative intermaxillary fixation and postoperative orthodontic use; orthodontic treatment began after 2 postoperative weeks.

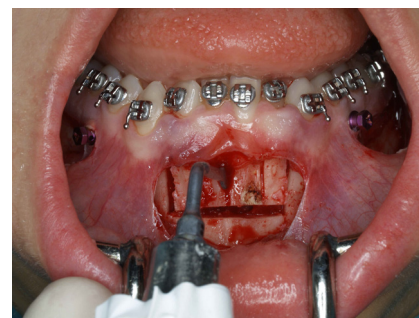

Fig. 4. Case example 1: Execution of buccal interdental corticotomies in the mandibular front-block segment in order to accelerate postoperative orthodontic movement. Transmucosal 2.0-mm miniscrews were used to stabilize the occlusion. These were placed between the first and second bicuspids.

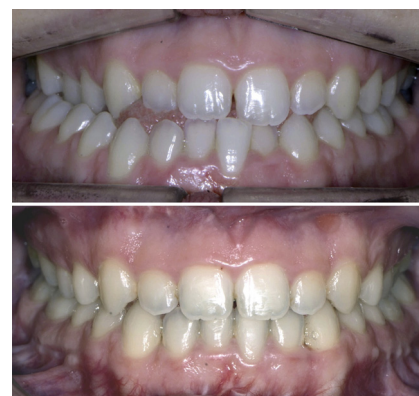

Fig. 5. Case example 1: Preoperative occlusion (top) and postoperative occlusion at 32 weeks after orthodontic treatment (bottom).

Surgery late

The ‘surgery late’ category corresponds to the conventional approach for orthognathic surgery, i.e., the traditional sequence of preoperative orthodontics, surgery, and postoperative orthodontics.

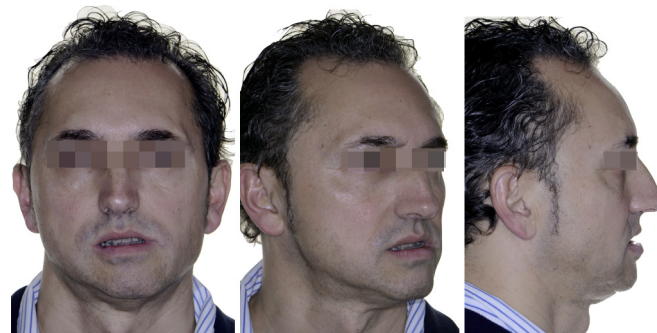

Fig. 6. Case example 2: Frontal, three-quarter, and profile views of a patient treated with a ‘surgery late’ approach. The patient’s main motivation for surgery was aesthetics (correction of facial asymmetry). However, a ‘surgery late’ approach was preferred based on the presence of anterior crowding and three-dimensional compensations.

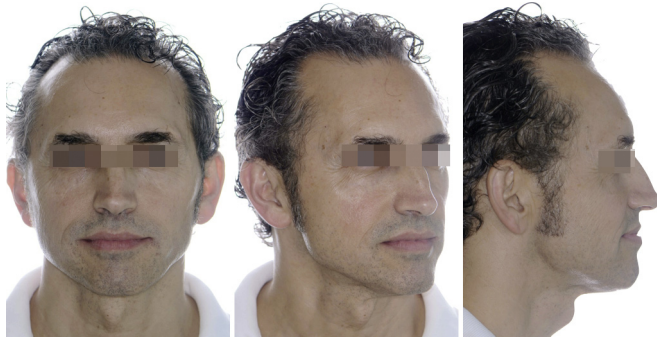4 *Hernández-Alfaro and Guijarro-Martínez*

Fig. 7. Case example 2: Frontal, three-quarter, and profile views at the end of treatment.

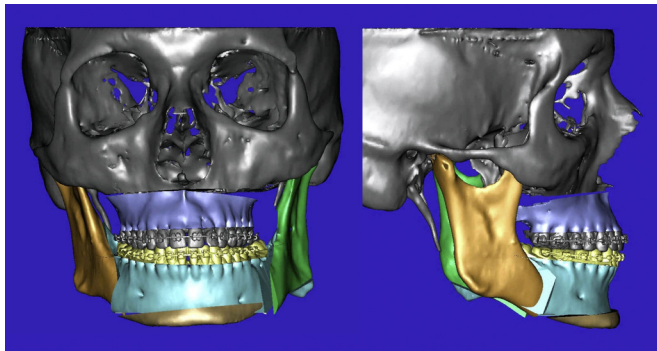


Fig. 8. Case example 2: Virtual treatment planning. Bimaxillary surgery with maxillary canting correction, mandibular canting and midline correction, and advancement and anticlockwise rotation of the maxillomandibular complex was planned.

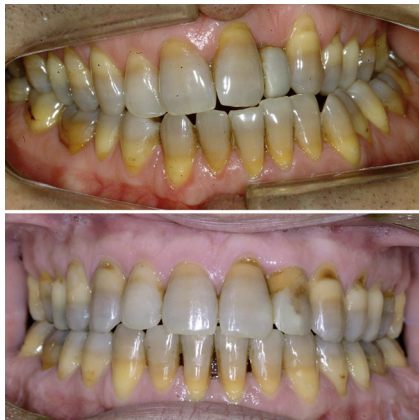

Fig. 9. Case example 2: Preoperative occlusion (top) and postoperative occlusion at 91 weeks after orthodontic treatment (bottom).

Patients were selected for this approach when the conditions for a 'surgery first' or 'surgery early' timing scheme were not met, or when the patient's main motivation for treatment was the achievement of optimal occlusal parameters (Figs 6–9).

Patients underwent routine preoperative orthodontic preparation for arch levelling and decompensation. Surgery proceeded in a standard fashion. As opposed to the 'surgery first' and 'surgery early' protocols, the use of miniscrews or other temporary anchorage devices (TADs) was not

systematic but rather reserved for cases of maxillary segmentation. Likewise, corticotomies were not performed routinely.

Surgery last

The 'surgery last' timing group comprised patients who had undergone compensatory orthodontic treatment in the past but had eventually decided upon surgery. In these cases, a compensated, stable occlusion was already present, such that no additional orthodontic preparation was

necessary (Figs 10 and 11). Cases who presented an inappropriate occlusion and required further preoperative tooth alignment or who accepted a new decompensating orthodontic treatment with reopening of extraction spaces were excluded from immediate surgery and managed with a 'surgery early' or 'surgery late' treatment concept.

Since these patients presented a functional class I occlusion, surgical planning was aimed at improving the aesthetic parameters maintaining, nevertheless, the preoperative maxillomandibular relationship. In other words, bimaxillary surgery with clockwise or counter-clockwise rotation was the main surgical movement. In some cases, the occlusal relationship was slightly modified in order to achieve occlusal optimization in addition to aesthetic improvement (Figs 12 and 13). No corticotomies were executed, since no major dental movements would follow. Miniscrews were placed for intraoperative intermaxillary fixation and postoperative elastic mechanics.

Surgery only

Conceptually, a 'surgery only' protocol proceeds directly with surgery, without any previous or subsequent orthodontic treatment. This approach was limited to three specific indications: (1) patients with an exclusively aesthetic concern who presented a stable postoperative occlusion as confirmed by study models; (2) patients with total or subtotal edentulism in whom orthodontic treatment would add little or no benefit to the final outcome, and in whom a combined prosthodontic–surgical (orthognathic surgery plus implant placement) management was foreseen; (3) patients with obstructive sleep apnoea (OSA) and a stable occlusion in whom the therapeutic objective was entirely functional (respiratory), and who refused to undergo any orthodontic treatment (Figs 14 and 15).

As in the 'surgery last' category, surgical planning required that the preoperative occlusion be maintained. Anticlockwise rotation of the maxillomandibular complex was the most common surgical movement in order to increase the upper airway volume (Fig. 16). Miniscrews were placed in all cases. No corticotomies were performed.

Surgery never

Conceptually, this group comprises patients who never undergo orthognathic surgery, in other words, patients with

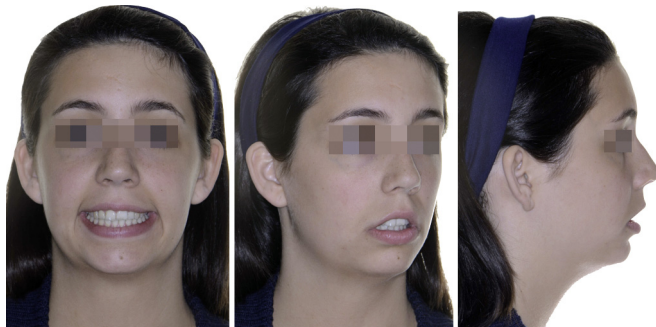

Fig. 10. Case example 3: Frontal, three-quarter, and profile views of a patient treated with a 'surgery last' approach. The patient had undergone compensatory orthodontic treatment in the past, resulting in a stable occlusion but an unsatisfactory aesthetic outcome.

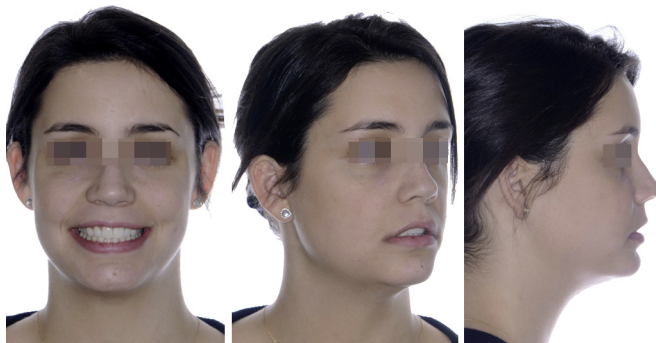

Fig. 11. Case example 3: Frontal, three-quarter, and profile views after surgery.

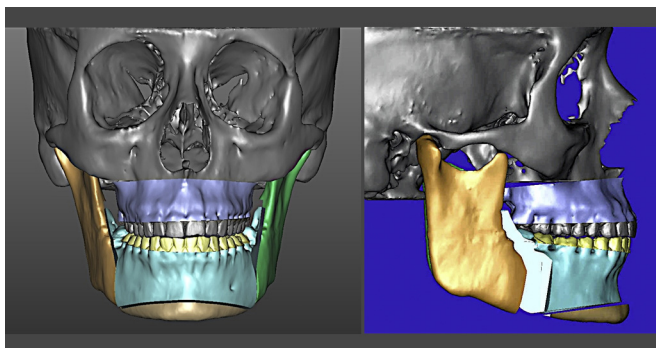


Fig. 12. Case example 3: Virtual treatment planning. Bimaxillary surgery with anticlockwise rotation and advancement of the maxillomandibular complex was planned.

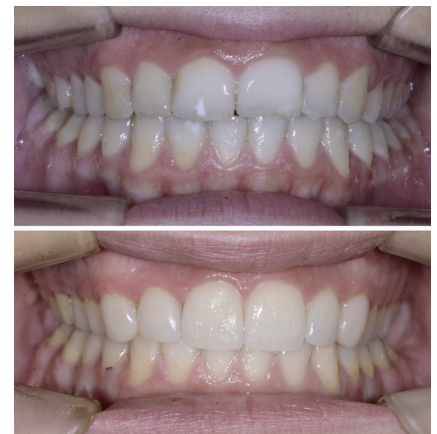

Fig. 13. Case example 3: Preoperative occlusion (top) and postoperative occlusion (bottom).

documented dentoskeletal deformities who have a wholly occlusal concern and/or fear of surgery leading them to seek exclusive orthodontic treatment.

For all six timing categories, the following variables were recorded: gender, age at the time of surgery, chief complaint and main motivation for treatment, orthodontic treatment length, and number of orthodontic appointments.

Results

From June 2010 to June 2013, a total number of 362 orthognathic procedures were performed at our centre (in 150 males and 212 females, mean age 23.4 years).

Results are summarized in Table 1. The most commonly indicated approach was by far 'surgery late', i.e., the traditional timing modality. No patients were assigned to the 'surgery never' category; as a unit specializing in orthognathic surgery, no exclusively orthodontic cases are managed at this centre.

Table 1. Results.

Approach	'Surgery first'	'Surgery early'	'Surgery late'	'Surgery last'	'Surgery only'
Total number of patients	68	15	261	11	7
Percentage out of total ($N = 362$)	18.8%	4.1%	72.1%	3.0%	1.9%
Males	27	7	110	3	3
Females	41	8	151	8	4
Mean age at the time of surgery, years	25.5	28.2	21.8	35.7	39
Age range at the time of surgery, years	19–46	17–38	16–68	24–52	33–57
Motivation for treatment					
Aesthetic concern	63	14	115	11	3
Occlusal concern	0	1	146	0	0
SDB	5	0	0	0	4
Most common surgical procedure	Bimaxillary surgery	Bimaxillary surgery	Bimaxillary surgery	Bimaxillary surgery	Bimaxillary surgery
Mean duration of orthodontic treatment, weeks	45.3	59.5	97.5	–	–
Mean number of orthodontic appointments	21	28	29	–	–

SDB, sleep-disordered breathing.

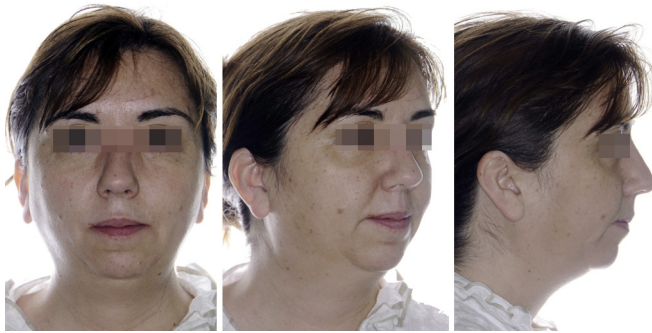

Fig. 14. Case example 4: Frontal, three-quarter, and profile views of a patient with obstructive sleep apnoea (OSA) treated with a 'surgery only' approach.

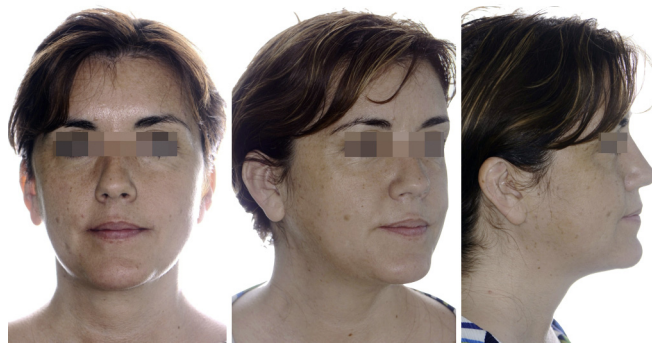

Fig. 15. Case example 4: Frontal, three-quarter, and profile views after surgery.

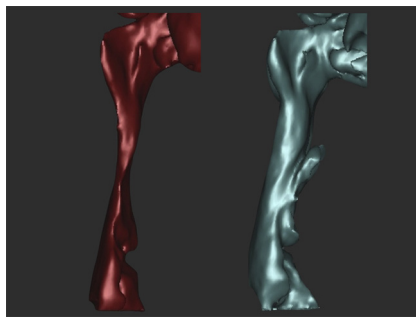


Fig. 16. Case example 4: Preoperative (left) and postoperative (right) three-dimensional reconstruction of the upper airway. A significant volumetric increase in the airway was achieved with counter-clockwise rotation and advancement of the maxillomandibular complex, while maintaining the preoperative occlusion.

Candidates for the 'surgery last' or 'surgery only' approaches tended to be older than patients undergoing a 'surgery first', 'surgery early', or 'surgery late' treatment scheme. In all cases, bimaxillary surgery was the most common surgical procedure.

With the 'surgery first', 'surgery early', and 'surgery last' approaches, the most common motivation for treatment was the desire for an improvement in facial aesthetics. Alternatively, occlusal optimization was the chief objective of patients selected for a 'surgery late' approach. Finally, patients who underwent a 'surgery only' scheme sought functional improve-

ment of their SDB, followed closely by aesthetic improvement.

Compared to the 'surgery early' and 'surgery first' timing modalities, 'surgery late' required an average of 38 weeks and 52.2 weeks more of orthodontic treatment, respectively. Nevertheless, the total number of orthodontic appointments was similar for the three timing options: 21 for 'surgery first', 28 for 'surgery early', and 29 for 'surgery late'.

Discussion

The orthodontic and surgical communities of the last 50 years have witnessed a

prodigious revolution in the treatment of dento-maxillofacial deformities. In the surgical field, improved rigid fixation systems and substantial technical refinements have given way to the development of minimally invasive surgical protocols.¹⁴ Together with the routine use of hypotensive anaesthesia and subsequent reduction in bleeding and oedema, this fact has consolidated orthognathic surgery as a safe, reliable procedure that can often be performed in an outpatient context.¹⁵ In the orthodontic field, the introduction of TADs has given way to a wide range of new anchorage possibilities, increased orthodontic efficiency, and reduced treatment times.^{16–19}

The orthognathic surgery patient 'prototype' has changed too. The desire to improve facial aesthetics – rather than just correcting a dysfunctional occlusion – has become the primary motivation for treatment in many cases. This aspiration for aesthetic upgrading, together with the popular perception of surgery as safe and predictable, is widening the number and age range of patients who become involved in orthodontic or combined orthodontic–surgical therapy. Indeed, the number of adult patients, with subsequent periodontal involvement and job-time limitations for long treatments, has increased significantly.¹ Some of these patients are orthodontically compensated individuals who are nevertheless unhappy with the aesthetic outcome and have eventually decided upon surgical correction of their deformity. Others are patients with SDB, often at a phase of OSA, who require immediate expansion of the oropharyngeal airway through counter-clockwise rotation and advancement of the maxillo-mandibular complex and cannot – or will not – undergo regular preoperative orthodontic preparation. As a result, these new patient profiles have led to a profound revision in the traditional timing scheme for orthognathic surgery and novel treatment options have arisen.

In an attempt to define and classify these new timing approaches, the authors of this paper carried out a retrospective analysis of all orthognathic procedures performed at a specialized centre for orthognathic surgery since June 2010. This particular date was chosen as the starting point of the evaluation because it coincided with the introduction of a formal treatment protocol for 'surgery first'. However, the timing of orthognathic surgery is not simply planned with a 'traditional perspective' or a 'surgery first perspective'. Our case review revealed that, at least in our practice, surgery takes place at different points

Table 2. Variables influencing orthognathic surgery timing.

Variable	Common situations
<i>Patient-specific variables</i>	
Chief complaint and main motivation for surgery	Occlusion Facial aesthetics OSA
Opportunity or willingness to adapt his/her personal agenda to the surgical procedure	Flexible agenda Job/time limitations
Opportunity or willingness to adapt his/her personal agenda to the required orthodontic appointments	Flexible agenda Job/time limitations
Underlying conditions that may compromise surgery or orthodontics	Active periodontal condition contraindicating demanding orthodontic movements Active TMJ disease or symptoms contraindicating an unstable occlusion and large occlusal plane changes
Occlusal characteristics	Severe crowding 3D dental compensations Transverse compromise in need of SARPE
<i>Orthodontist-specific variables</i>	
Previous experience with orthognathic surgery cases managed with the traditional timing approach	Broad experience Limited experience
Previous experience with TAD	Broad experience Limited experience
<i>Surgeon-specific variables</i>	
Previous experience with orthognathic surgery cases managed with the traditional timing approach	Broad experience Limited experience

OSA, obstructive sleep apnoea; TMJ, temporomandibular joint; 3D, three-dimensional; SARPE, surgically assisted rapid palatal expansion; TAD, temporary anchoring devices.

along the orthodontic treatment timeline. These particular time points, which are always case-specific and decided by consensus between the orthodontist, surgeon, and patient, are influenced by several variables (Table 2). According to these, the optimal timing approach is selected from a total of six possibilities: (1) 'surgery first', (2) 'surgery early', (3) 'surgery late', (4) 'surgery last', (5) 'surgery only', and (6) 'surgery never'.

In a 'surgery first' approach, surgery is performed directly with no preoperative orthodontic phase. Our preliminary experience with this treatment modality together with a standardized workflow model has been reported recently.^{1,5} Compared to conventional timing, a substantial reduction in the total treatment time was achieved. Indeed, this study revealed that the mean treatment time with 'surgery late' (97.5 weeks) was more than double the time required for a 'surgery first' protocol (45.3 weeks), even though the average number of orthodontic appointments was similar (29 for 'surgery late', 21 for 'surgery first'). This shortened treatment time can be explained by the high orthodontic efficiency resulting from the surgically induced RAP^{1,2,7} plus the onset of orthodontic treatment after skeletal base correction.⁵ Our results show that as many as 18.8% of our cases were treated with a 'surgery first' approach. However, it must be emphasized that careful patient selec-

tion is absolutely essential. First and foremost, the chief complaint should be either facial aesthetics or SDB. In our opinion, a patient whose prime motivation for surgery is the attainment of a perfect occlusion is not a good candidate for 'surgery first', since more predictable orthodontic results can probably be attained with other approaches. Secondly, and in agreement with other authors,²⁰ our protocol excludes patients with severe crowding in need of extractions and cases of class II second division with overbite, i.e., cases in which the inferior curve of Spee is severely altered. Cases requiring SARPE to achieve an adequate transverse maxillary dimension, or severe asymmetries with 3D dental compensations, are currently disregarded for 'surgery first' too. In our hands, these scenarios appear too complex to anticipate the final occlusion accurately. Moreover, 3D dental compensations can significantly impair immediate postsurgical stability. Finally, patients with TMJ symptoms or uncontrolled periodontal disease are automatically excluded from the 'surgery first' approach on the basis of an unstable postoperative occlusion and excessively demanding or risky orthodontic movements, respectively.

Despite this systematized inclusion-exclusion criteria list, the orthodontist should have the last word in patient selection. Indeed, while a 'surgery first' proto-

col does not entail greater procedural complexity from a surgical point of view, it can be very technically demanding for the orthodontist.^{1,4,5} In our protocol, a preoperative 3D virtual orthodontic setup is absolutely essential in order to anticipate the future dental movements. The orthodontist must be familiarized with the use of TADs and be prepared for a rather stressful patient follow-up; tooth movements should begin no later than 2 weeks after surgery in order to benefit from the surgically stimulated RAP, and archwires must be changed every second to third week. Consequently, we believe orthodontists who become involved with 'surgery first' timing should have a broad experience in orthognathic surgery with the classical ('surgery late') approach.

An important advantage of a 'surgery first' sequence is the fact that patients can decide for themselves the surgical appointment date without the need to wait for complete arch levelling and decompensation. The lack of preoperative axial correction of the incisors is also an important advantage for skeletal class III patients, in whom orthodontic preparation tends to exacerbate a compensated anterior crossbite, thereby accentuating the prognathic profile and intensifying the patient's perception of facial disharmony.¹ Conversely, if surgery is performed prior to orthodontics, the total treatment time is noticeably reduced. The skeletal problem

– and therefore the aesthetic concern – is corrected from the beginning.^{1,6} This circumstance has a very positive influence on patient compliance with postoperative orthodontics and is a powerful contributor to global satisfaction with treatment.⁵ However, it is often the case that patients with a predominantly aesthetic concern and the wish for prompt surgical correction – thereby requiring a ‘surgery first’ approach – present with severe crowding in need of extractions and/or complex 3D dental compensations due to skeletal asymmetry. In these cases, a ‘surgery early’ approach is followed. This timing modality is very similar to ‘surgery first’, with the exception that a brief preoperative orthodontic phase takes place. In the case of severe crowding, surgery can proceed as soon as most of the necessary space closure after tooth extractions has been completed. If severe 3D compensations and/or dental midline deviations are present, the requisite for surgery is that corrections in the transverse dimension are attained. At any rate, complete levelling and decompensation are not necessary. Another indication for this ‘surgery early’ approach is patients who are candidates for ‘surgery first’, but due to personal logistical reasons – academic, professional – need to delay surgery. Until such time as an appropriate date for the surgical appointment is fixed, orthodontic treatment anticipates some dental movements before surgery. The surgical procedure and postoperative orthodontic treatment proceed with the same particularities as for a ‘surgery first’ approach. Consequently, a high degree of orthodontic expertise is also essential.

Despite these relatively innovative ‘surgery first’ and ‘surgery early’ timing schemes, ‘surgery late’ – in other words, the conventional timing approach – continues to be the most frequently indicated methodology in our hands (72.1%). It is well known that traditional surgical-orthodontic treatment comprises two orthodontic phases: a preoperative preparation where most of the orthodontic movements are performed to achieve a decompensated, levelled occlusion (with or without the anticipation of maxillary segmentation), and a postoperative phase for minor adjustments. Preoperative orthodontics usually requires 15–17 months,^{21,22} sometimes even up to 24 months.²³ The postoperative orthodontic phase has been reported to last an average of 7 months²¹ to 12 months.²³ At any rate, total orthodontic treatment is frequently longer than what is initially indicated to the patient.^{1,21} In addition, some patients,

especially skeletal class III, are extremely reluctant to accept the aesthetic decay associated with dental decompensation. Finally, another disadvantage of this scheme is the fact that surgery timing is strictly conditioned by orthodontic treatment. Thus, the patient must agree to an externally imposed surgical appointment date. Despite these drawbacks, however, ‘surgery late’ continues to be the most predictable timing scheme to attain occlusal normalization. As such, it should be the way to go in cases where the final 3D dental position cannot be accurately foreseen or guaranteed, when complex 3D dental movements are anticipated, or when the patient’s main motivation for surgery is the achievement of an optimal occlusion. Finally, surgeons or orthodontists with limited experience in orthognathic surgery or TADs should also select this approach. In our ‘surgery late’ protocol, surgery proceeds in a standard fashion, i.e., the regular facial osteotomies are performed with no additional interdental corticotomies. The use of TADs is reserved for cases of maxillary segmentation, where miniscrews are used for vertical control anteriorly and for vertical and transversal control posteriorly.

Our retrospective evaluation revealed a small group of patients who were treated with a special timing methodology, the so-called ‘surgery last’. The typical patient prototype of this category is an individual who has declined orthognathic surgery in the past and has undergone compensatory orthodontic treatment that has resulted in a stable functional occlusion; at some point, however, the patient becomes concerned with aesthetics and decides to seek surgical skeletal correction. In our practice, the number of patients in such a situation is steadily increasing. The mean age of this group of patients – and the level of periodontal compromise – tends to be higher than in patients involved in a ‘surgery first’, ‘surgery early’, or ‘surgery late’ protocol. When a clinician is confronted with a case of this type, two possibilities exist: (1) the occlusion is inappropriate and requires some type of orthodontic treatment; in this case, one of the previously described approaches – ‘surgery first’, ‘surgery early’, or ‘surgery late’ – can be followed; (2) the occlusion is indeed a stable, functional, class I occlusion. In this latter scenario, one alternative would be to initiate a standard decompensation orthodontic treatment that would probably include reopening of extraction spaces. Besides the substantial amount of time that this orthodontic retreatment implies, alveolar bone compromise and

the risk of root resorption is often a strong limiting factor. In addition, many patients are very reluctant to undergo another long orthodontic treatment to undo what was previously accomplished. In the past, when surgeons contemplated skeletal movements in the sagittal and vertical dimensions only, this was, nevertheless, the standard approach; the orthodontist would recuperate the pre-orthodontic maxillomandibular discrepancy such that surgery could simultaneously correct occlusion and facial harmony. For years now, most orthognathic surgeons have acknowledged that rotational movements of the maxillomandibular complex need to be incorporated into the surgical plan in order to achieve adequate projections of the different facial components and thereby maximize aesthetic results.^{24,25} This principle is applied in what we call the ‘surgery last’ scheme. Therefore, if the patient has a stable functional occlusion, we opt for no further orthodontic preparation. Instead, an occlusal plane change is introduced with clockwise or counterclockwise rotation of the maxillomandibular complex. In this way, facial harmony is restored while the patient’s preoperative occlusion is maintained. Incorrect dental inclinations that resulted from previous orthodontic compensation – in particular, the characteristic over-torqued incisors of compensated class II and class III patients – can hence be readjusted. From an orthodontic point of view, it could be argued that such a procedure does not correct dental inclinations with regards to the skeletal bases. However, they are restored with regards to the facial complex, which is what produces facial improvement. No postoperative orthodontic treatment follows. This means that surgery is the critical step that governs the final outcome, with the key particularity that the preoperative occlusion must remain intact. In our protocol, miniscrews are used for intraoperative intermaxillary fixation and postoperative elastic mechanics. Finally, it must be mentioned that ‘surgery last’ patients with less ambitious aesthetic demands can be satisfactorily managed with a camouflaging genioplasty and/or ancillary cosmetic procedures.

As in a ‘surgery last’ approach, a ‘surgery only’ protocol proceeds directly with surgery without any subsequent orthodontic treatment. The difference between the two timing schemes is the fact that in a ‘surgery only’ situation, the patient has not received any previous orthodontic treatment in the past either. In other words, the case is managed entirely with surgery. In our practice, this approach is strictly

Table 3. Comparison between the six surgical timing options.

	'Surgery first'	'Surgery early'	'Surgery late'	'Surgery last'	'Surgery only'	'Surgery never'
Aesthetic motivation	+++	+++	++	+++	+++	–
Occlusal motivation	+	++	+++	–	–	+++
Respiratory motivation (OSA)	+++	+++	–	+++	+++	–
3D virtual orthodontic setup	+++	+++	+	–	–	+
Patient decides timing	+++	++	+	+++	+++	NA
Preoperative orthodontics	–	+	++	+++	–	NA
Use of TAD (miniscrews)	+++	+++	–	+++	+++	+
Corticotomies to increase the RAP	+++	+++	–	–	–	+
Orthodontic complexity	+++	+++	+	NA	NA	+++
Surgical complexity	++	++	+	+++	+++	NA

OSA, obstructive sleep apnoea; 3D, three-dimensional; TAD, temporary anchoring devices; RAP, regional acceleratory phenomenon; NA, not applicable.

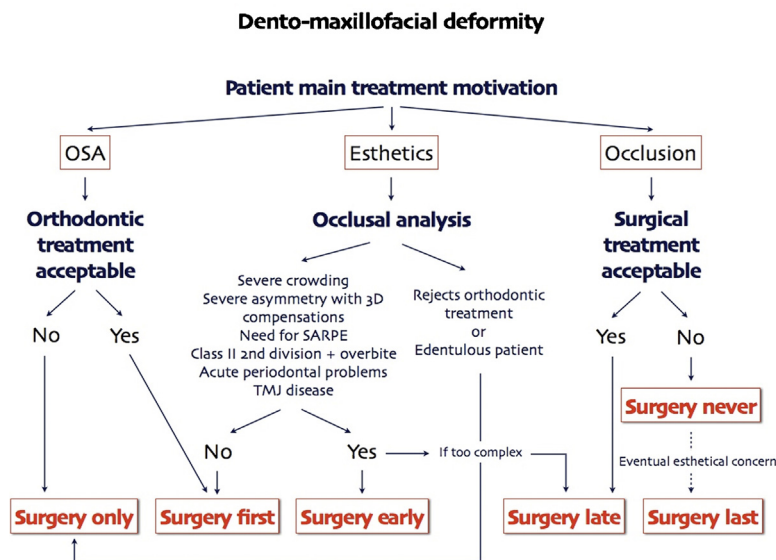


Fig. 17. The selection of timing according to patient-specific variables. Patients whose main motivation for treatment is obstructive sleep apnoea can be managed with a 'surgery only' approach if they present a stable functional occlusion and/or they reject orthodontic treatment. If orthodontic treatment is acceptable, the airway volume may be increased with a 'surgery first' approach, followed by orthodontics. When the chief complaint is facial aesthetics, a 'surgery first' approach may be considered if the patient's baseline occlusal characteristics do not hinder an accurate prognostication of the end occlusion and the orthodontist has sufficient experience in orthognathic surgery. If the end occlusion cannot be reliably foreseen, a 'surgery early' approach is preferred. Inexperienced orthodontists, however, should preferably follow a conventional 'surgery late' scheme. Patients who reject orthodontic treatment or whose occlusal condition makes the benefit of orthodontics questionable or irrelevant (partial or total edentulous) can be managed with a 'surgery only' approach. If occlusal optimization is the main motivation for treatment, a 'surgery late' modality is the preferred approach. However, if the patient refuses surgery, 'surgery never' (i.e., orthodontic compensation) may be considered as long as aesthetic decay does not occur and the patient understands the limitations of this option. Should a patient who has been orthodontically compensated eventually become concerned with aesthetics, a 'surgery last' approach may be considered.

limited to three specific scenarios: (1) patients whose chief complaint is facial aesthetics and who present a stable functional occlusion as confirmed by study models; (2) partial or total edentulous patients in whom orthodontic treatment would add little or no benefit to the final outcome, and in whom a combined prosthodontic–surgical (orthognathic surgery plus implant placement) management is foreseen; and (3) patients with OSA and a stable occlusion in whom the treatment

goal is to increase the airway volume, and who reject additional orthodontic treatment. In all these three situations, it is required that the preoperative occlusal relationship be maintained. Consequently, as in a 'surgery last' approach, the treatment basis is occlusal plane correction through rotational–translational movements of the maxillomandibular complex.

It is important to emphasize the fact that, while a high degree of orthodontic expertise is essential for the 'surgery first'

and 'surgery early' timing approaches, the 'surgery last' and 'surgery only' modalities represent the most demanding surgical scenarios. Considering that no postoperative orthodontic treatment is anticipated, skeletal repositioning must be precise enough to correct the aesthetic or respiratory problem while maintaining the preoperative occlusion. Any slight deviation from this aim can render the postoperative occlusion unstable. Thus, only expert surgeons should become involved with these two modalities.

The last treatment timing option is that in which surgery does not take place at all. This 'surgery never' category is comprised of patients with documented dento-maxillofacial deformities who reject any type of surgical formula, and whose treatment motivation is exclusively occlusion-based. These patients tend to be managed with orthodontic compensation, which, in expert hands, can produce a stable and functional occlusion. As long as this option does not provoke facial decay and the patient understands its limitations, it can be a reasonable compromise option. High orthodontic expertise is critical in these cases in order to avoid relapse-prone movements and periodontal compromise. Some of these patients could eventually benefit from the previously discussed 'surgery last' approach.

Table 3 offers a comparison between the six treatment timing modalities regarding patient motivation, treatment planning, orthodontic and surgical management, and technical particularities. Figure 17 shows a simple algorithm to aid in the preliminary selection approach.

If the clinician acknowledges the patient's complaints, wishes, and expectations as the primary guidelines for individualized treatment planning, timing for orthognathic surgery can no longer be conceived as a constant, inflexible dogma valid for all patients and all therapeutic contexts. On the contrary, the contemporary management of dento-maxillofacial

deformities must be based on a comprehensive analysis of various patient-, orthodontist-, and surgeon-specific variables. Moreover, the timing particularities of each treatment approach require the contemplation of specific orthodontic and surgical techniques aimed at enhancing the final outcome while minimizing patient morbidity and financial costs.

Funding

None.

Competing interests

None declared.

Ethical approval

Approved by the Committee on Ethical Medical Practice of the Teknon Medical Centre (Ref. 2013FHA005).

Patient consent

Written patient consent was obtained to use clinical photographs and radiological data.

References

- Hernández-Alfaro F, Guijarro-Martínez R, Molina-Coral A, Badia-Escriche C. "Surgery first" in bimaxillary orthognathic surgery. *J Oral Maxillofac Surg* 2011;**69**:e201–7.
- Liou EJ, Chen PH, Wang YC, Yu CC, Huang CS, Chen YR. Surgery-first accelerated orthognathic surgery: postoperative rapid orthodontic tooth movement. *J Oral Maxillofac Surg* 2011;**69**:781–5.
- Nagasaka H, Sugawara J, Kawamura H, Nanda R. "Surgery first" skeletal class III correction using the Skeletal Anchorage System. *J Clin Orthod* 2009;**43**:97–105.
- Sugawara J, Aymach Z, Nagasaka DH, Kawamura H, Nanda R. "Surgery first" orthognathics to correct a skeletal class II malocclusion with an impinging bite. *J Clin Orthod* 2010;**44**:429–38.
- Hernández Alfaro F, Guijarro-Martínez R, Peiró-Guijarro MA. Surgery first in orthognathic surgery: what have we learned? A comprehensive workflow based on 45 consecutive cases. *J Oral Maxillofac Surg* 2014;**72**:376–90.
- Villegas C, Janakiraman N, Uribe F, Nanda R. Rotation of the maxillomandibular complex to enhance esthetics using a "surgery first" approach. *J Clin Orthod* 2012;**46**:85–91.
- Villegas C, Uribe F, Sugawara J, Nanda R. Expedited correction of significant dentofacial asymmetry using a "surgery first" approach. *J Clin Orthod* 2010;**44**:97–103.
- Wilcko WM, Wilcko T, Bouquot JE, Ferguson DJ. Rapid orthodontics with alveolar reshaping: two case reports of decrowding. *Int J Periodontics Restorative Dent* 2001;**21**:9–19.
- Sebaoun JD, Ferguson DJ, Wilcko MT, Wilcko WM. Alveolar osteotomy and rapid orthodontic treatments. *Orthod Fr* 2007;**78**:217–25.
- Wilcko MT, Wilcko WM, Pulver JJ, Bissada NF, Bouquot JE. Accelerated osteogenic orthodontics technique: a 1-stage surgically facilitated rapid orthodontic technique with alveolar augmentation. *J Oral Maxillofac Surg* 2009;**67**:2149–59.
- Strippoli J, Akin JJ. Accelerated tooth movement by alveolar corticotomy or piezoscision. *Orthod Fr* 2012;**83**:155–64.
- Frost HM. The biology of fracture healing. An overview for clinicians. Part I. *Clin Orthop Relat Res* 1989;(248):283–93.
- Hernández-Alfaro F, Guijarro-Martínez R. Endoscopically assisted tunnel approach for minimally invasive corticotomies: a preliminary report. *J Periodontol* 2012;**83**:574–80.
- Hernández-Alfaro F, Guijarro-Martínez R. "Twist technique" for pterygomaxillary dysjunction in minimally invasive Le Fort I osteotomy. *J Oral Maxillofac Surg* 2013;**71**:389–92.
- Cangemi Jr CF. Administration of general anesthesia for outpatient orthognathic surgical procedures. *J Oral Maxillofac Surg* 2011;**69**:798–807.
- Yao CC, Lai EH, Chang JZ, Chen I, Chen YJ. Comparison of treatment outcomes between skeletal anchorage and extraoral anchorage in adults with maxillary dentoalveolar protrusion. *Am J Orthod Dentofacial Orthop* 2008;**134**:615–24.
- Chung KR, Kim SH, Lee BS. Speedy surgical-orthodontic treatment with temporary anchorage devices as an alternative to orthognathic surgery. *Am J Orthod Dentofacial Orthop* 2009;**135**:787–98.
- Mimura H. Treatment of severe bimaxillary protrusion with miniscrew anchorage: treatment and complications. *Aust Orthod J* 2008;**24**:156–63.
- Upadhyay M, Yadav S, Nanda R. Vertical-dimension control during en-masse retraction with mini-implant anchorage. *Am J Orthod Dentofacial Orthop* 2010;**138**:96–108.
- Liou EJ, Chen PH, Wang YC, Yu CC, Huang CS, Chen YR. Surgery-first accelerated orthognathic surgery: orthodontic guidelines and setup for model surgery. *J Oral Maxillofac Surg* 2011;**69**:771–80.
- Luther F, Morris DO, Hart C. Orthodontic preparation for orthognathic surgery: how long does it take and why? A retrospective study. *Br J Oral Maxillofac Surg* 2003;**41**:401–6.
- Dowling PA, Espeland L, Krogstad O, Stenvik A, Kelly A. Duration of orthodontic treatment involving orthognathic surgery. *Int J Adult Orthodon Orthognath Surg* 1999;**14**:146–52.
- Diaz PM, Garcia RG, Gias LN, Aguirre-Jaime A, Perez JS, de la Plata MM, Navarro EV, Gonzalez FJ. Time used for orthodontic surgical treatment of dentofacial deformities in white patients. *J Oral Maxillofac Surg* 2010;**68**:88–92.
- Wolford LM, Chemello PD, Hilliard F. Occlusal plane alteration in orthognathic surgery—part I: effects on function and esthetics. *Am J Orthod Dentofacial Orthop* 1994;**106**:304–16.
- Chemello PD, Wolford LM, Buschang PH. Occlusal plane alteration in orthognathic surgery—part II: long-term stability of results. *Am J Orthod Dentofacial Orthop* 1994;**106**:434–40.

Address:

Raquel Guijarro-Martínez
Institute of Maxillofacial Surgery
Teknon Medical Centre Barcelona
Vilana 12
D-185
08022 Barcelona
Spain
E-mail: guijarro.raq@gmail.com