

“Surgery First” in Bimaxillary Orthognathic Surgery

Federico Hernández-Alfaro, MD, DDS, PhD, FEBOMS,
Raquel Guijarro-Martínez, MD,† Ana Molina-Coral, DMD,‡
and Consuelo Badía-Escriche, DMD§*

The general formula in traditional orthognathic treatment has consisted of a variable length of preoperative orthodontic preparation, surgery itself, and a relatively constant period of postoperative orthodontics.¹ Patients have usually expressed high levels of satisfaction with the esthetic and functional outcomes, especially if they were accurately informed about all aspects of their treatment.² However, an important percentage of patients will rate the orthodontics as the worst part of their treatment owing to the appliances' visibility, the pain caused, and the duration.³ The usual estimated duration of orthodontic treatment has often tended to be too optimistic.⁴

Recently, the performance of surgery without orthodontic preparation (ie, “surgery first”), followed by regular postoperative dental alignment, was proposed by Nagasaka et al.⁵ The authors used this approach to correct skeletal Class III malocclusion with the aid of skeletal anchorage system orthodontics. The total treatment time was noticeably reduced. In addition, preoperative profile worsening owing to incisor decompensation was avoided and the immediate profile improvement after the surgery was greatly appreciated by the patient.⁵

The purpose of the present study was to report our experience with the “surgery first” approach in 2 cases of bimaxillary surgery.

Patients and Methods

Two patients were treated with bimaxillary surgery using the “surgery first” approach at the Institute of Maxillofacial Surgery and Implantology of the Teknon Medical Center (Barcelona, Spain) during 2010. The Helsinki Declaration guidelines were followed in all treatment phases. Under institutional review board approval, a prospective evaluation was performed.

The inclusion criteria for the “surgery first” sequence were skeletal malocclusions requiring combined orthodontic-surgical treatment with no need for extractions. The patients were informed about the treatment protocol and provided treatment-specific written informed consent. In one case, the orthodontic appliances were installed after the surgery was performed; in the other, the protocol was modified to place them right before the surgical stage.

Preoperative cone-beam computed tomography was performed in both cases. The IS i-CAT, version 17-19 (Imaging Sciences International, Hatfield, PA), was used. A 7-second scan was taken with the patient sitting upright, with the clinical Frankfort horizontal plane parallel to the floor and the mandible in centric relation with the help of a wax bite. With the aid of specific software (SimPlant OMS, version 13.0; Materialize, Leuven, Belgium), a virtual orthodontic and surgical setup was done to anticipate the future dental and skeletal movements. First, an orthodontic setup was performed to anticipate the final position of the upper and lower incisors. Using the anticipated orthodontic setup and following the clinical guidelines,⁶ the surgical planning was completed.

Both procedures were performed with the patient under general anesthesia by the same surgeon. Patient satisfaction was evaluated using a visual analog scale ranging from 1 (least satisfied possible) to 100 (most satisfied possible).

CASE 1

A 23-year-old woman had been referred by her orthodontist with the complaint of an open bite. She

*Oral and Maxillofacial Surgeon, Head, Institute for Maxillofacial Surgery and Implantology, Teknon Medical Center, Barcelona, Spain; Clinical Professor in Oral and Maxillofacial Surgery and Director, Master Program in Implant Dentistry, Universitat Internacional de Catalunya, Barcelona, Spain.

†Resident in Oral and Maxillofacial Surgery, Fellow, Institute for Maxillofacial Surgery and Implantology, Teknon Medical Center, Barcelona, Spain.

‡Orthodontist, Associate Professor in Orthodontics, Universitat Internacional de Catalunya, Barcelona, Spain.

§Orthodontist, Private Practice, Valencia, Spain.

Address correspondence and reprint requests to Dr Guijarro-Martínez: Institute for Maxillofacial Surgery and Implantology, Teknon Medical Center Vilana 12D-185, Barcelona 08022, Spain; e-mail: raquelguijarro@comv.es

© 2011 American Association of Oral and Maxillofacial Surgeons

0278-2391/11/6906-0075\$36.00/0

doi:10.1016/j.joms.2011.01.010

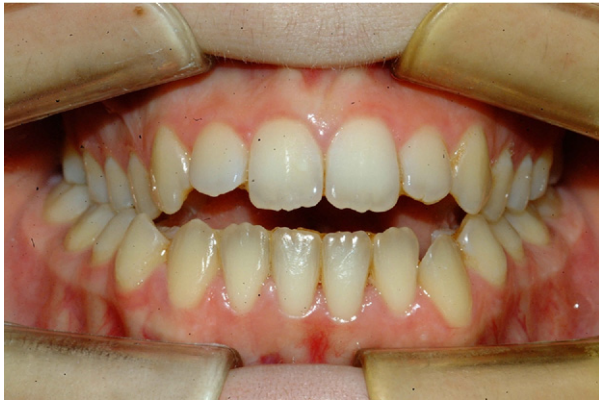

FIGURE 1. Preoperative occlusion of patient 1, who had presented with primary occlusal complaints.

Hernández-Alfaro et al. "Surgery First" in Bimaxillary Orthognathic Surgery. J Oral Maxillofac Surg 2011.

had undergone a 3-year orthodontics-only treatment 6 years earlier, and the bite had reopened shortly after the removal of the appliances (Fig 1). She had no esthetic concerns; in fact, she requested no facial changes apart from those strictly related to the correction of her malocclusion. She was extremely concerned with having to again undergo a long orthodontic treatment.

Frontal inspection revealed long face syndrome because of the skeletal open bite. The radiologic and clinical profile evaluation revealed a biretrusive contour with an anterior open bite (Fig 2). Occlusally, she exhibited an angle Class II malocclusion with transverse maxillary deficiency, a pronounced curve of Spee in the upper jaw, and moderate crowding in the lower. A diagnosis of long face, biretrusive, with an anterior open bite, transverse deficiency of the maxilla, and crowding in the mandible was established.

The virtual orthodontics setup excluded the need for extractions. The treatment plan included a segmented Le Fort I maxillary osteotomy with 5-mm advancement, 4-mm expansion, and 3-mm posterior impaction, plus bilateral sagittal split osteotomies (BSSO) for mandibular advancement of 8 mm and counterclockwise rotation. Virtual surgical planning allowed for the generation of an intermediate computer-assisted design, computer-assisted manufacturing (CAD/CAM) splint. The final splint was prepared using plaster models in a nonadjustable articulator. Because of the lack of splint support owing to the absence of regular orthodontic appliances, extra retention was given to the final splint.

Surgery was performed 3 weeks after the first appointment. The usual maxilla-first approach was followed (Fig 3). Before starting the osteotomies, 6 anchorage screws were placed transmucosally to assist in intraoperative stabilization of the segments and

splints. Microscrews were used to avoid loading of the recently bonded brackets. The planned surgical movements were executed (Fig 4). Fixation of the 4-piece maxilla was achieved with 4 titanium miniplates and 16 screws. The BSSO for advancement was stabilized with 2 plates and 8 screws. The final splint was left in place to aid in transversal contentment of the expanded maxilla. The operative time was 78 minutes.

Her postoperative recovery was uneventful. She was discharged from the hospital 24 hours after the surgery. At 2 weeks postoperatively, the final splint was removed, and the orthodontic movements were begun using round wires and intermaxillary elastics.

CASE 2

A 20-year-old woman checked into our institute with the complaint of facial disharmony (Fig 5). She reported emotional and social disability because of her facial deformity. She requested corrective surgery as soon as possible and hoped it could occur before she started university 2 months later.

The clinical and radiologic examination revealed a skeletal Class III malocclusion with maxillary deficiency and mandibular asymmetry (Fig 6). Cant of the occlusal plane was also evident on frontal inspection. Compensations in the lower jaw were accompanied by discrete crowding. No transverse problems were present.

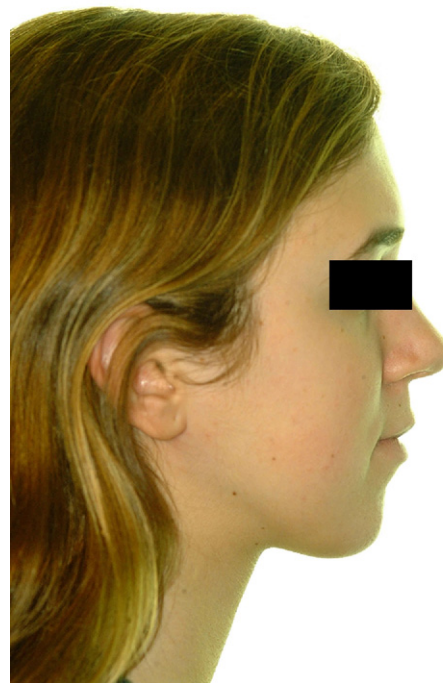

FIGURE 2. Preoperative profile of patient 1.

Hernández-Alfaro et al. "Surgery First" in Bimaxillary Orthognathic Surgery. J Oral Maxillofac Surg 2011.

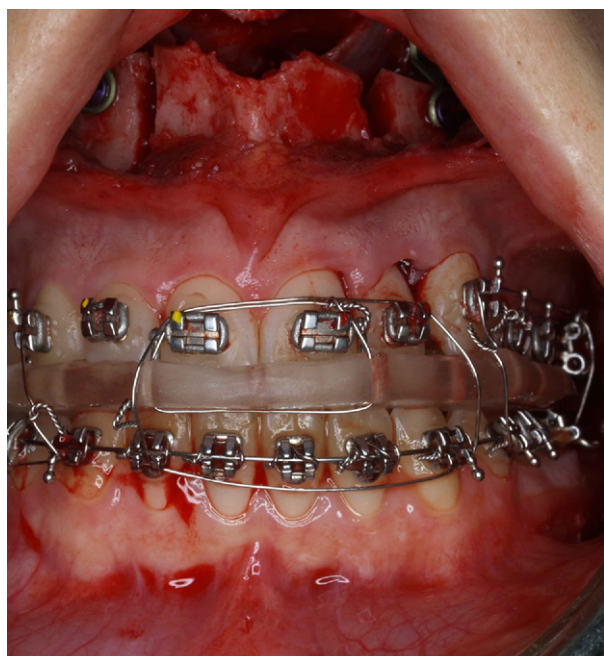


FIGURE 3. Patient 1. Intraoperative view of segmented Le Fort I osteotomy, with intermediate CAD/CAM splint in place.

Hernández-Alfaro et al. "Surgery First" in Bimaxillary Orthognathic Surgery. J Oral Maxillofac Surg 2011.

The virtual orthodontic setup ruled out the need for extractions and verified an adequate position and axial inclination of the upper incisors. The virtual surgical treatment plan included Le Fort I maxillary osteotomy for 7-mm advancement and 4-mm descent and a BSSO for 3-mm retrusion and centering. Just as in the previous case, an intermediate CAD/CAM splint was generated, and a final splint was crafted from the plaster models placed in a nonadjustable articulator.

Likewise, temporary screws were placed, and a maxilla-first protocol was followed (Figs 7-9). Two

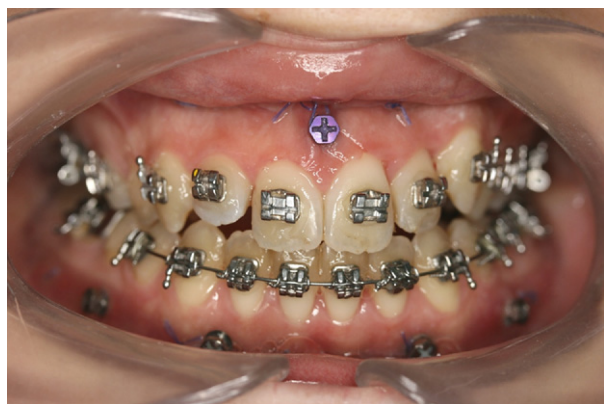

FIGURE 4. Immediate postoperative occlusion of patient 1 with temporary screws in place.

Hernández-Alfaro et al. "Surgery First" in Bimaxillary Orthognathic Surgery. J Oral Maxillofac Surg 2011.

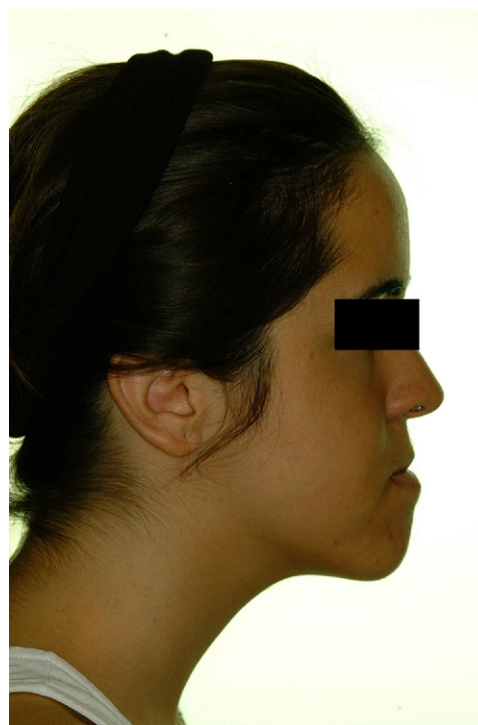

FIGURE 5. Preoperative profile of patient 2, who had presented with primary esthetic complaints.

Hernández-Alfaro et al. "Surgery First" in Bimaxillary Orthognathic Surgery. J Oral Maxillofac Surg 2011.

preformed plates with 7 screws on each were used to stabilize the maxilla, and 2 more with 4 screws each were used for the mandible. Autologous fat transfer for cheek recontouring was performed using the trochanteric areas as donor sites. The final splint was removed at the end of surgery. The orthognathic procedure lasted 65 minutes, with another 25 minutes needed for the liposculpturing.

Her postoperative recovery was uneventful, and the patient was discharged from the hospital the next

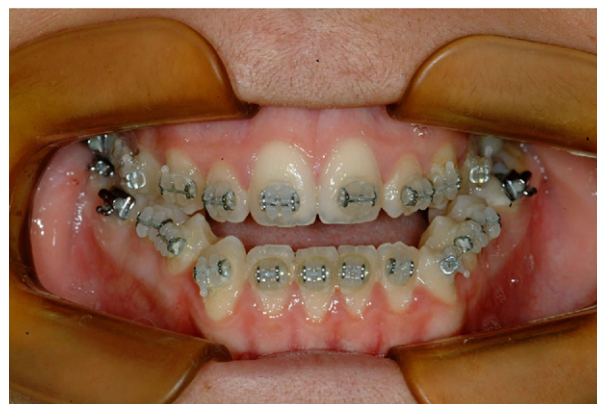

FIGURE 6. Preoperative occlusion of patient 2.

Hernández-Alfaro et al. "Surgery First" in Bimaxillary Orthognathic Surgery. J Oral Maxillofac Surg 2011.

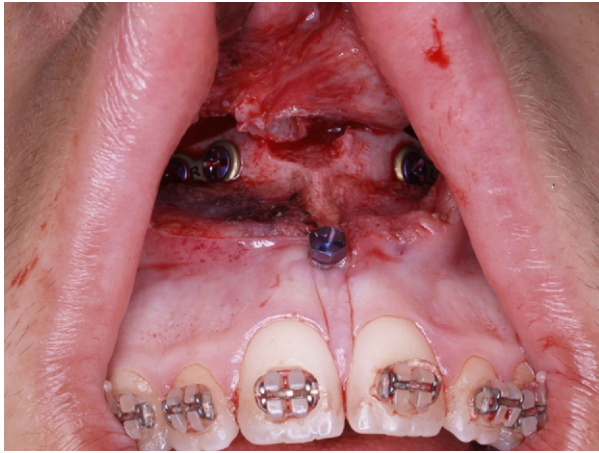


FIGURE 7. Intraoperative view of Le Fort I osteotomy of patient 2.

Hernández-Alfaro et al. "Surgery First" in Bimaxillary Orthognathic Surgery. J Oral Maxillofac Surg 2011.

day. Her orthodontics began 10 days after surgery and involved arch alignment and leveling, with decompensation of the lower arch.

Results

In patient 1, the total orthodontic treatment required 250 days. Arch settlement and leveling achieved a Class I relationship, with adequate root parallelism that was stable at 1 year of follow-up (Fig 10). The patient was satisfied with the esthetic result (Fig 11).

For patient 2, the total orthodontic treatment lasted 185 days, after which an adequate Class I occlusion and an esthetically balanced profile was achieved (Figs 12,13).

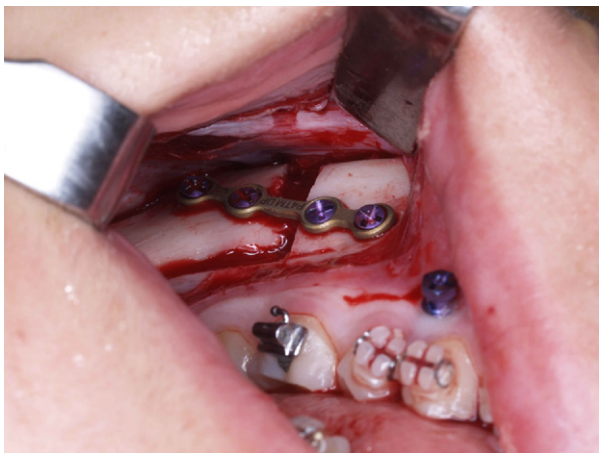

FIGURE 8. Intraoperative view of BSSO of patient 2.

Hernández-Alfaro et al. "Surgery First" in Bimaxillary Orthognathic Surgery. J Oral Maxillofac Surg 2011.

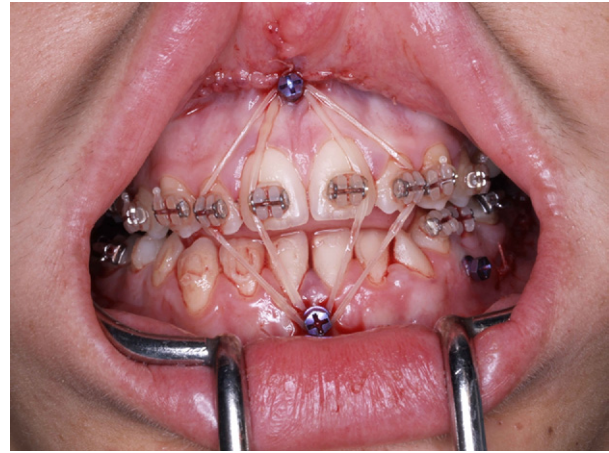

FIGURE 9. Immediate postoperative occlusion of patient 2, with temporary screws in place.

Hernández-Alfaro et al. "Surgery First" in Bimaxillary Orthognathic Surgery. J Oral Maxillofac Surg 2011.

Patient 1 rated the treatment outcome and duration at a score of 95. The orthodontist considered the case challenging but extremely satisfactory from a time-results perspective. Patient 2 rated satisfaction with the duration and results of treatment as 100 on the visual analog scale. The orthodontist considered the case easy and extremely satisfactory from a time-results and patient-perception perspective.

Discussion

The "surgery first" concept in orthognathic surgery was introduced by Nagasaka et al⁵ in 2009. They reported the correction of a Class III skeletal malocclusion with mandibular setback surgery and subsequent orthodontic alignment with the aid of temporary anchorage devices. The patient did not undergo any previous orthodontic preparation. Because of

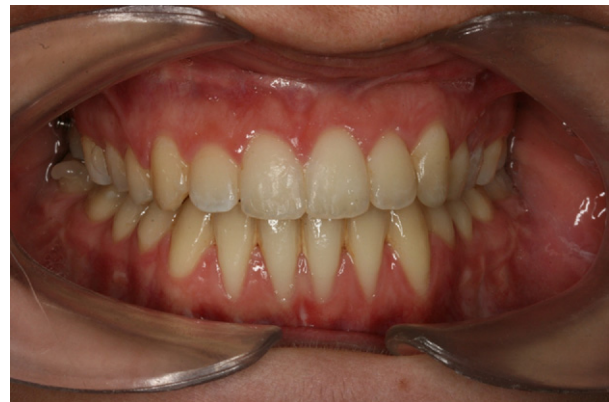

FIGURE 10. Final occlusion at 1 year of follow-up for patient 1.

Hernández-Alfaro et al. "Surgery First" in Bimaxillary Orthognathic Surgery. J Oral Maxillofac Surg 2011.

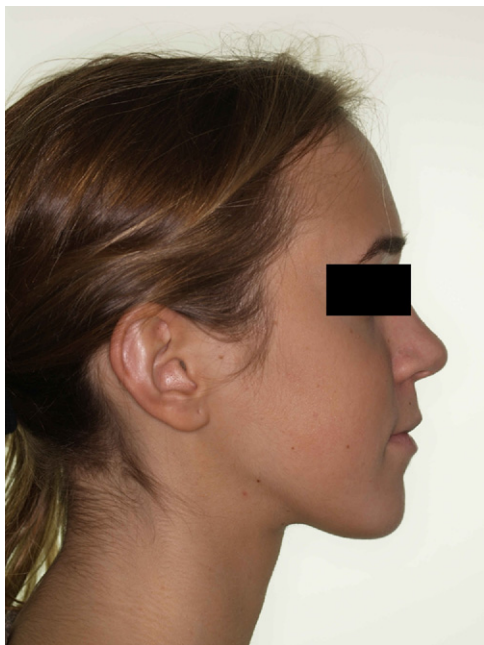

FIGURE 11. Postoperative profile of patient 1.

Hernández-Alfaro et al. "Surgery First" in Bimaxillary Orthognathic Surgery. J Oral Maxillofac Surg 2011.

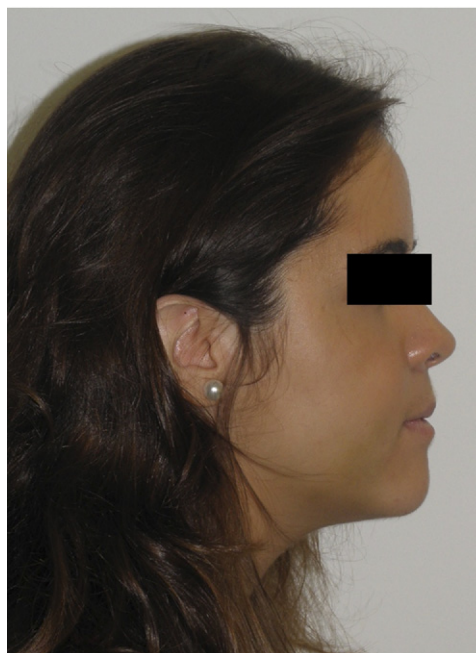

FIGURE 13. Postoperative profile of patient 2.

Hernández-Alfaro et al. "Surgery First" in Bimaxillary Orthognathic Surgery. J Oral Maxillofac Surg 2011.

their excellent clinical results and substantial reduction in total treatment time, the investigators postulated that this new treatment approach could become a standard procedure in the future.⁵ Taking into consideration the number of patients requesting orthognathic surgery with primarily esthetic concerns and time limitations for long treatment, the "surgery first" approach could represent a reasonable, cost-effective method to manage skeletal malocclusion in selected cases. However, to our knowledge, no references to the use of the "surgery first" approach in bimaxillary orthognathic surgery exist in published scientific reports.

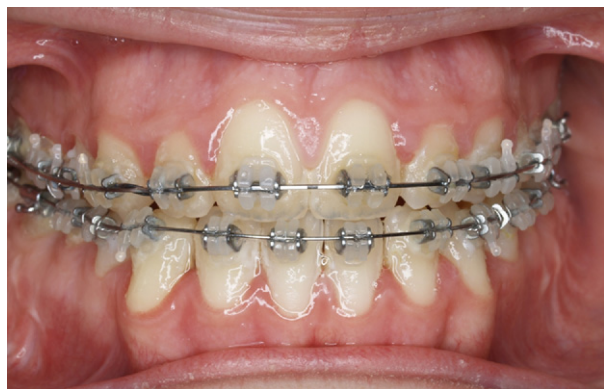

FIGURE 12. Postoperative occlusion, 1 month before bracket debonding, for patient 2.

Hernández-Alfaro et al. "Surgery First" in Bimaxillary Orthognathic Surgery. J Oral Maxillofac Surg 2011.

Traditional surgical-orthodontic treatment has included 2 orthodontic phases: a preoperative preparation in which most of the orthodontic movements are performed to achieve a precise, stable occlusion and a postoperative phase for minor adjustments. Preoperative orthodontic treatment usually lasts 15 to 17 months,^{4,7} or even up to 24 months.⁸ However, the total preoperative treatment is frequently longer than that initially indicated to the patient.⁴ The average duration of the postoperative orthodontic phase has varied from 7 months⁹ to 12 months.⁸ No statistically significant differences regarding patient age, gender, or type of malocclusion have been detected.^{4,8-10} These orthodontic phases often cause significant discomfort to the patient.^{4,11} One study found that one third of patients rated the orthodontics as the worst part of their orthognathic treatment owing to the appliances' visibility and discomfort and the length of treatment.³

In contrast, if the surgery is performed before the orthodontic treatment, the total treatment time will be noticeably reduced. Nagasaka et al⁵ reported that the treatment could be shortened to about 12 months, less than the average time needed for traditional preoperative orthodontics alone.^{4,7,9} In our patients, the total treatment time was 264 days (8.8 months) for patient 1 and 195 days (6.5 months) for patient 2. These data, although lacking statistical significance, have illustrated that a "surgery first" approach tends to condense the treatment time consid-

erably, mainly by shortening the total orthodontic period.

In 2001, Wilcko et al¹² suggested that rapid tooth movement in the context of corticotomy-facilitated orthodontics was the result of a demineralization–remineralization process consistent with the wound healing pattern of the regional acceleratory phenomenon. It seems that selective bone injury results in an overwhelming activating stimulus for both catabolic and anabolic responses in the periodontium.¹³ It is possible that the alveolar bone adjacent to the osteotomies performed during orthognathic surgery also undergoes increased bone turnover.¹⁴ This could account for the more efficient postoperative orthodontic movements and hence contribute to the total treatment time reduction in a "surgery first" sequence.

Moreover, routine preoperative orthodontics involve dental alignment, arch coordination, and incisor decompensation; very often, the latter tends to prolong the treatment time with little or no significant benefit to the patient.⁵ In addition, axial correction of the incisors exacerbates an anterior crossbite and tends to unmask the patient's underlying skeletal deformity. Especially in the case of Class III patients, the prognathic profile will be greatly accentuated as the preoperative orthodontics progress. This intensifies the patient's perception of facial disharmony. The "surgery first" approach, in contrast, corrects the skeletal problem (and hence the esthetic concern) from the beginning. This clearly accounted for the favorable evaluation of the treatment by our second patient.

Another advantage of the "surgery first" approach compared with traditional surgical-orthodontic treatment includes the rapid profile improvement with subsequent immediate patient satisfaction. This was evident in patient 1, in whom the open bite was already closed at the end of surgery. In addition, in the case of skeletal Class III patients, such as patient 2, the upper lip and tongue tone improvement that occurs after mandibular setback increases the force on the incisors and improves the efficiency of incisor decompensation, adding to the total treatment time reduction.

In contrast, several difficulties and disadvantages must be considered. First, the occlusion cannot serve as a guide for the designation of treatment goals. Second, the immediate postoperative occlusion is often unstable; thus, an occlusal splint while eating has been recommended.⁵ Temporary anchorage devices can be considered to help stabilize the osteotomies when no solid orthodontic appliances are present during surgery.^{5,14} These temporary anchorage devices might later aid in anchoring orthodontic forces firmly in a specific fashion to

apply all required vectors. In addition, they could play a role in compensation of a surgical error or skeletal relapse.⁵

It is unquestionable that this treatment concept requires a precise diagnosis and detailed treatment planning. The postoperative orthodontic movements must be accurately planned with the surgical plan, implying constant communication between the surgeon and orthodontist. It is absolutely indispensable that the orthodontist be skilled in orthognathic surgery cases, because the orthodontist is often confronted with a rather complex scenario. We have thus recommended that only experienced teams be involved with this approach.

To our knowledge, this is the first report of orthognathic bimaxillary cases performed with the "surgery first" sequence. In addition to other advantages, this method reduced the total treatment time significantly and was very well accepted by patients. High orthodontic efficiency responds to the correction of the skeletal bases as a starting point and accelerated tooth movement owing to the increased postoperative metabolic turnover. Our first case (anterior open bite, with transverse maxillary deficiency and vertical excess) represented one of the most complex situations in orthognathic surgery and yet was successfully managed with this approach. Our second patient requested rapid correction of her esthetically compromising profile, and the treatment was completed within 6 months. Both patients manifested high satisfaction with the treatment protocol and duration. A thorough diagnosis, planning, and execution could render the "surgery first" approach appropriate for a good proportion of our routine cases.

References

1. Proffit WR, White RP, Sarver DM: Contemporary Treatment of Dentofacial Deformity. St Louis, MO, Mosby, 2003, p 250
2. Cunningham SJ, Hunt NP, Feinmann C: Perceptions of outcome following orthognathic surgery. *Br J Oral Maxillofac Surg* 34:210, 1996
3. Nurminen L, Pietilä T, Vinkka-Puhakka H: Motivation for and satisfaction with orthodontic-surgical treatment: A retrospective study of 28 patients. *Eur J Orthod* 21:79, 1999
4. Luther F, Morris DO, Hart C: Orthodontic preparation for orthognathic surgery: How long does it take and why? A retrospective study. *Br J Oral Maxillofac Surg* 41:401, 2003
5. Nagasaka H, Sugawara J, Kawamura H, et al: "Surgery first" skeletal class III correction using the skeletal anchorage system. *J Clin Orthod* 43:97, 2009
6. Hernández-Alfaro F: Upper incisor to soft tissue plane (UI-STP): A new reference for diagnosis and planning in dentofacial deformities. *Med Oral Patol Oral Cir Bucal* 15:e779, 2010
7. Dowling PA, Espeland L, Krogstad O, et al: Duration of orthodontic treatment involving orthognathic surgery. *Int J Adult Orthodon Orthognath Surg* 14:146, 1999
8. Diaz PM, Garcia RG, Gias LN, et al: Time used for orthodontic surgical treatment of dentofacial deformities in white patients. *J Oral Maxillofac Surg* 68:88, 2010

9. Luther F, Morris DO, Karnezi K: Orthodontic treatment following orthognathic surgery: How long does it take and why? A retrospective study. *J Oral Maxillofac Surg* 65:1969, 2007
10. Robb SI, Sadowsky C, Schneider BJ, et al: Effectiveness and duration of orthodontic treatment in adults and adolescents. *Am J Orthod Dentofac Orthop* 114:383, 1998
11. Flanary CM, Alexander JM: Patients' response to the orthognathic surgery experience: Factors leading to dissatisfaction. *J Oral Maxillofac Surg* 41:770, 1983
12. Wilcko WM, Wilcko T, Bouquot JE, et al: Rapid orthodontics with alveolar reshaping: Two case reports of decrowding. *Int J Periodontics Restorative Dent* 21:9, 2001
13. Sebaoun JD, Ferguson DJ, Wilcko MT, et al: Alveolar osteotomy and rapid orthodontic treatments. *Orthod Fr* 78:217, 2007
14. Villegas C, Uribe F, Sugawara J, et al: Expedited correction of significant dentofacial asymmetry using a "surgery first" approach. *J Clin Orthod* 44:97, 2010