

Alveolar Ridge Split on Horizontal Bone Augmentation: A Systematic Review

Basel Elnayef, DDS, MS¹/Alberto Monje, DDS²/Guo-Hao Lin, DDS³/Jordi Gargallo-Albiol, DDS, PhD⁴/
Hsun-Liang Chan, DDS, MS⁵/Hom-Lay Wang, DDS, MS, PhD⁶/Federico Hernández-Alfaro, MD, DDS, MS, PhD⁷

Purpose: Many techniques have been proposed to overcome the limitations displayed by maxillary atrophy. The aim of this systematic review was to assess the predictability, dimensional changes, and associated factors to successfully perform the alveolar ridge split (ARS) technique of augmentation. **Materials and Methods:** An electronic and manual literature searches was conducted by two independent reviewers in several databases, including Medline, Embase, Cochrane Central Register of Controlled Trials, and Cochrane Oral Health Group Trials Register, for articles written in English up to February 2014. A manual search was also performed to ensure a thorough screening process. Based on the PICO (problem, intervention, comparison, outcome) model, the chief question of this study was: Can patients with horizontal ridge deficiency be successfully treated with the ARS technique and implant therapy? **Results:** Overall, 17 articles met the inclusion criteria, and a subsequent meta-analysis was performed. A Cohen kappa interagreement rate of 0.82 was reached. The implant survival rate of the included studies was 97.0% (range, 94.4% to 100%) with the full-thickness flap (FTF) approach and 95.7% (range, 86.6% to 100%) with the partial-thickness flap (PTF) approach. The weighted mean (WM) of horizontal bone width gain was calculated for included studies using FTF for the ARS technique. Four studies that had data were included in the meta-analysis. The WM \pm standard deviation of bone width gain was 3.19 ± 1.19 mm (range, 2.00 to 4.03 mm). For studies using PTF for ARS, only one study provided mean and standard deviation of horizontal bone width gain (4.13 ± 3.13 mm); hence, meta-analysis could not be performed. Buccal wall fracture represented the most frequent postoperative complication, followed by postoperative ridge resorption. **Conclusion:** In selected scenarios, the ARS technique might represent a predictable approach as demonstrated by a high implant survival rate, adequate horizontal bone gain, and minimal intra- and postoperative complications. Further research is needed to determine the influence of the grafting materials inserted and flap tissue biotype, as well as the anatomical characteristics on final bone augmentation outcomes. INT J ORAL MAXILLOFAC IMPLANTS 2015;30:596–606. doi: 10.11607/jomi.4051

Key words: alveolar ridge augmentation, bone regeneration, dental implants, osteotomy, systematic review, treatment outcome

¹Lecturer, Department of Oral Surgery and Implantology, International University of Catalonia, Spain.

²Resident and Fellow Research, Department of Periodontics and Oral Medicine, The University of Michigan, Ann Arbor, Michigan, USA.

³Resident, Department of Periodontics and Oral Medicine, The University of Michigan, Ann Arbor, Michigan, USA.

⁴Professor, Department of Oral Surgery and Implantology, International University of Catalonia, Spain.

⁵Lecturer, Department of Oral Surgery and Implantology, International University of Catalonia, Spain.

⁶Professor and Program Director, Department of Periodontics and Oral Medicine, The University of Michigan, Ann Arbor, Michigan, USA.

⁷Professor and Chairman, Department of Oral Surgery and Implantology, International University of Catalonia, Spain.

Correspondence to: Dr Alberto Monje, Department of Periodontics and Oral Medicine, University of Michigan School of Dentistry, 1011 North University Ave, Ann Arbor, MI 48109-1078, USA. Fax: 734-936-0374. Email: amonjec@umich.edu.

©2015 by Quintessence Publishing Co Inc.

Alveolar bone resorption after tooth extraction often is a challenge for proper dental implant placement and stability, especially in the maxillary arch.^{1–3} In maxillae, bone resorption after extraction follows a centripetal pattern; the majority of bone resorption occurs within the first 6 months, and has been reported to be up to 40% in height and 60% in width.^{4–7} This translates to a horizontal bone resorption of 5 to 7 mm (50% of the original socket width),⁸ which makes proper implant placement difficult.

Numerous treatment procedures/approaches have been proposed to overcome horizontal bone resorption. These include guided bone regeneration (GBR) using titanium mesh⁹ or absorbable membrane,¹⁰ bone blocks combined with or without particulate graft material,^{11–14} and the minimally invasive approach of using narrow-diameter implants.¹⁵ All these approaches have been shown to be relatively predictable.⁶ However, complications and drawbacks do exist. For example,

membrane exposure to the oral cavity used for GBR might trigger infection, and as a consequence, lead to failure.¹⁶ Furthermore, in case of bone block grafting, donor site morbidity might lead patients to look into other approaches. The alveolar ridge split (ARS) technique with or without the use of interpositional bone graft (also known as alveolar corticotomy) may overcome some of these deficiencies, while providing a good amount of dimension for proper implant insertion.^{17,18} ARS splits the crest cortical bone to create proper horizontal dimension for immediate or delayed implant placement.^{19,20} Advantages such as the possibility of simultaneous implant placement, avoiding donor site, reducing morbidity, and shortening the treatment time have all been associated with this approach. However, Scipioni et al²⁰ suggested using the partial-thickness flap (PTF) approach instead of the traditional full-thickness flap (FTF) approach to preserve periosteal blood supply and therefore minimize the amount of alveolar bone loss. Nonetheless, Blus et al²¹ appealed for the traditional FTF approach because it is easier to control the surgical field with the FTF approach.

Recently, Milinkovic and Cordaro conducted a systematic review to compare the effectiveness of several techniques to augment horizontal bone in the atrophic maxillary ridges.⁶ ARS was found to have a high implant survival rate (97.4%) with minimal technical complications (6.8%). However, factors that might influence the outcomes were not addressed in that study. Hence, the present systematic review examined the amount of horizontal bone gain after ARS as well as its related predictability, complications, implant survival rate, and factors (eg, the FTF vs PTF approach) that might influence the final outcomes.

MATERIALS AND METHODS

Information Sources and Development of Focused Question

An electronic and manual literature searches were conducted by two independent reviewers (B.E. and A.M.) through the Medline, Embase, Cochrane Central Register of Controlled Trials, and Cochrane Oral Health Group Trials Register databases for articles written in English up to February 2014. Based on the PICO (problem, intervention, comparison, outcome) model, the chief question of the study was: Can patients with horizontal ridge deficiency be successfully treated with the ARS technique and implant therapy?

Screening Process

Two reviewers (AM and BE) designed and assessed the proposal for the present project to make sure the PRISMA guideline was followed to provide a high level

of evidence. PRISMA consists of a 27-item checklist and a four-phase flow diagram.²² Combinations of controlled terms (MeSH and Emtree) and keywords were used whenever possible. The search terms used, where "[mh]" represented the MeSH terms and "[tiab]" represented title and/or abstract, for the PubMed search were as follows: ("bone graft" [mh] OR "bone grafting" [ti] OR ("dental implantation, endosseous"[mh] OR "dental implants" [mh]) OR "grafting" [mh]) AND (ridge-split [tiab]) or (expanded ridge [tiab]) or (split alveolar [tiab]) or (crest-split [tiab]) AND English [la] NOT (letter [pt] OR comment [pt] OR editorial [pt]) NOT ("animals"[mh]). In addition, a manual search of implant-related journals, including the *International Journal of Oral & Maxillofacial Implants*, *Clinical Implant Dentistry and Related Research*, *Clinical Oral Implants Research*, *Implant Dentistry*, *Journal of Dental Research*, *Journal of Clinical Periodontology*, *Journal of Periodontology*, and the *International Journal of Periodontics & Restorative Dentistry*, from January to June of 2014, was performed to ensure a thorough screening process.

Eligibility Criteria

Articles were included in this systematic review if they met the following inclusion criteria: prospective or retrospective, cohort or case series with 10 or more human subjects, reporting the outcomes of ARS technique, implant survival and/or failure rate and/or mean and standard deviation of ridge gain, complication rates, horizontal bone augmentation in the partial or full edentulous maxilla. Accordingly, data on several factors, such as the study design, number of patients included at the last follow-up assessment, number of defect sites, surgical location, type of bone grafting material, whether a membrane was placed, implant system, and whether any other grafting material was further used (ie, growth factors), were extracted from the selected studies and analyzed. Moreover, to more comprehensively address the aim of this study, other parameters related to the technique were further extracted: initial mean bone ridge width, bone augmentation achieved at the end of the study period, mean resorption, and if failure occurred, the presumptive cause (Table 1). Lastly, to study implant behavior on ridge-expanded bone, factors such as implant placement protocol, loading time, and cumulative survival rate were included in Table 1. Case reports or case series with fewer than 10 subjects, systematic reviews, preclinical studies, or human trials with missing information were excluded. Also, studies in which ARS was followed by the use of expanders were further excluded to focus only on the most commonly used approach. References in the excluded articles were also screened for studies that met the inclusion criteria. The Newcastle-Ottawa scale (NOS) was used to assess the

Table 1 Characteristics of the Studies Included in the Qualitative Assessment

Authors (year)	Study design	Groups	No. of patients	No. of defects	Location of horizontal defects	Type of bone grafting material (Placement of the grafting material)	Membrane (Y/N)	Implant system	Approach	Additional grafting material/growth factor
Anitua et al ⁵¹ (2013)	RC	NCG	15	17	Mandible/maxillae	AB+DBBM (inside /outside)	Y	BTI	FTF	PRGF
Basa et al ³⁷ (2004)	PCT	NCG	30	38	Mandible/maxillae	PRP+BTCP/AG (inside)	N	FD/CML	FTF	PRP
Blus et al ³⁸ (2010)	PCT	NCG	43	61	Mandible/maxillae	DBBM (inside/outside)	Y	3i/LR	FTF	PRP
Bravi et al ⁴⁸ (2007)	RCS	NCG	734	NR	Mandible/maxillae	NG	Y	DS/FD/FT	PTF	NR
Chiapasco et al ³⁹ (2006)	PCT	NCG	45	NG	Mandible/maxillae	NG	N	ITI	PTF	N
Danza et al ⁴⁸ (2009)	RCS	PES	86	NG	Mandible/maxillae	NG	N	NC	FTF	N
		No PES		NG	Mandible/maxillae	NG	N	NC	FTF	N
Demetriades et al ⁴³ (2011)	PCT	NCG	15	NG	Mandible/maxillae	DBBM (inside)	N	NR	FTF	N
Ella et al ⁴⁰ (2014)	PCT	No BS	15	NG	Mandible	NG	Y	NB	PTF	N
		BS	17	17	Mandible	BCP (17) (inside)	Y	NB	PTF	N
Engelke et al ⁴¹ (1997)	PCT	NCG	44	14	Mandible/maxillae	HA (14) (inside)	Y	NB/ITI	PTF	N
Ferrigno et al ⁴² (2005)	PCT	ITI TE	20	42	Maxillae	AB+DBBM (NR)	Y	ITI	FTF/PTF	N
		ITI SI	20	40	Maxillae			ITI		N
Garcez-Filho et al ⁵² (2014)	RCS	NCG	14	19	Maxillae	DBBM (NR)	N	ST	PTF	N
Holtzclaw et al ⁴⁹ (2010)	RCS	NCG	13	17	Mandible	AG (NR)	Y	NR	FTF	N
Jensen et al ⁴⁷ (2009)	RC	OPF PTF FTF	40	1 50 13	Mandible/maxillae	NR	NR	NR	OPF PTF FTF	N
Rahpeyma et al ⁴⁴ (2013)	PCT	NCG	25	21	Mandible/maxillae	BTCP (NR)	NR	NR	FTF	N
Scipioni et al ²⁰ (1994)	RCS	NCG	170	NG	Maxillae	NG (NR)	N	FD	PTF	NR
Sethi et al ⁴⁵ (2000)	PCT	NCG	102	NR	Maxillae	AB+HA (NR)	N	NR	FTF	N
Sohn et al ⁵⁰ (2010)	RCS	NCG	32	NG	Mandible	NC (NR)	Y	NR	FTF/MPF	NR

RC = retrospective cohort; NCG = no control group; AB = autologous bone; DBBM = deproteinized C bone mineral; BTI = Biotechnology Institute SL; FTF = full-thickness flaps; PRGF = platelet-rich growth factor; NR = no reported; N = no; PCT = prospective controlled trial; PRP = platelet-rich plasma; BTCP = β -tricalcium phosphate; FD = tapered titanium plasma-sprayed Frialit implants; CML = Camlog implants; 3i = biomet 3i Osseotite implants; LR = leader Tixos; RCS = retrospective case series; NG = no grafted; Y = yes; DS = Frialit implants (Dentsply); FT = IMZ implants (Friatec); PTF = partial-thickness flaps; PES = piezo-electric surgery; NC = not clear; No PES = no PES performed; No BS = no bone substitute; BS = bone substitute; ITI TE = Tapered Effect Implants (Institute Straumann); ITI SI = standard solid-screw implants (Institute Straumann); OPF = osteoperiosteal flap; BCP = biphasic calcium phosphate; HA = hydroxyapatite; AG = allograft; NB = Nobel Biocare; ITI = Institute Straumann; ST = SLActive (Institut Straumann AG); MPF = mucoperiosteal flap.

quality of such studies for a proper understanding of nonrandomized studies²³ by two calibrated masked investigators (B.E. and A.M.). The Cohen kappa coefficient was used to assess interrater agreement.

Data Analysis

The method of meta-analysis used for this article was previously described by another systematic review.²⁴

The primary outcome was the implant survival rate, and the secondary outcome was horizontal bone width gain. The pooled weighted mean (WM) and the 95% confidence interval (CI) of each variable were estimated using a computer program (Comprehensive Meta-analysis version 2, Biostat). Random effects meta-analyses of the selected studies were applied to account for potential bias arising from methodologic

Initial mean bone ridge width (mm)	Bone augmentation achieved (mm/cm ³)	Mean resorption (mm)	Mean final bone gain (mm)	No. of implants placed	Implant placement protocol (stages)	Mean implant loading time (mo)	Follow-up of implants (mo)	Implant survival (overall)	Failed "split-crests"	
									%	Cause
4.29 ± 0.16	7.63 ± 0.32	NR	3.35 ± 0.34	37	1	3	16.73 ± 4.03	100	0	N
3.5	NR	NR	NR	120	1	3.5	6	100	0	N
3.3 ± 0.7	6.0 ± 0.4	NR	2.7	180	1	5.5	36	97.2	0	N
NR	NR	NR	NR	1,715	1/2	3	120	95.7	0	N
4	8	0.8	4	110	1/2	3.5	20.4	97.3	2.2	Buccal plate fracture
NR	NR	NR	NR	21	1	0	13	95.3	1.1	NR
NR	NR	NR	NR	199	1	6	13	96.2		
4	NR	1.8	NR	34	1/2	5	24	97	6.6	Facial bone resorption
3.5	NC	NC	NR	64	1	6	12	100	0	N
3.5	NC	NC	NR							
NR	2	1.9	NR	124	1	3.5	60	86.62	0	N
4	NR	NR	NR	42	1	3	12	100	2.5	Buccal bone fracture
	NR		NR	40				95		
3.2	NR	1.93 ± 0.93	NR	40	1	2	120	95	0	N
3.63 ± 0.82	7.66 ± 1.15	NR	4.03 ± 0.67	31	2	2.5	6	100	0	N
NR	NR	1	3.5	81	2	4	12	92.5	0	N
NR	NR	2	4.13 ± 3.13					93.3		
NR	NR	2	3.44 ± 1.44					94.4		
3.2 ± 0.34	5.57 ± 0.49	NR	2 ± 0.3	82	1	3	6	100	0	N
NR	NR	NR	NR	329	1	4.5	12	98.5	0	N
2.4	5.2	NR	NR	371	1	6	60	97	0	N
3	5.7	NR	NR	74	1/2	4	35	98.8	0	N

differences among studies. Forest plots were produced to graphically represent WM and 95% CI in primary/secondary outcomes for included studies. The number of implants placed was used as the analysis unit for primary outcome; the number of defects was used as the analysis unit for secondary outcome. Funnel plots were also examined for publication bias. In addition, heterogeneity among studies was assessed with the

chi-square test, with *P* < .05 representing significant heterogeneity. Regression analysis was also performed to analyze the potential impact of confounding factors, including the use of membrane or bone grafting materials, on primary and secondary outcomes. The findings of these meta-analyses were reported in adherence to the Prisma statement.²⁵

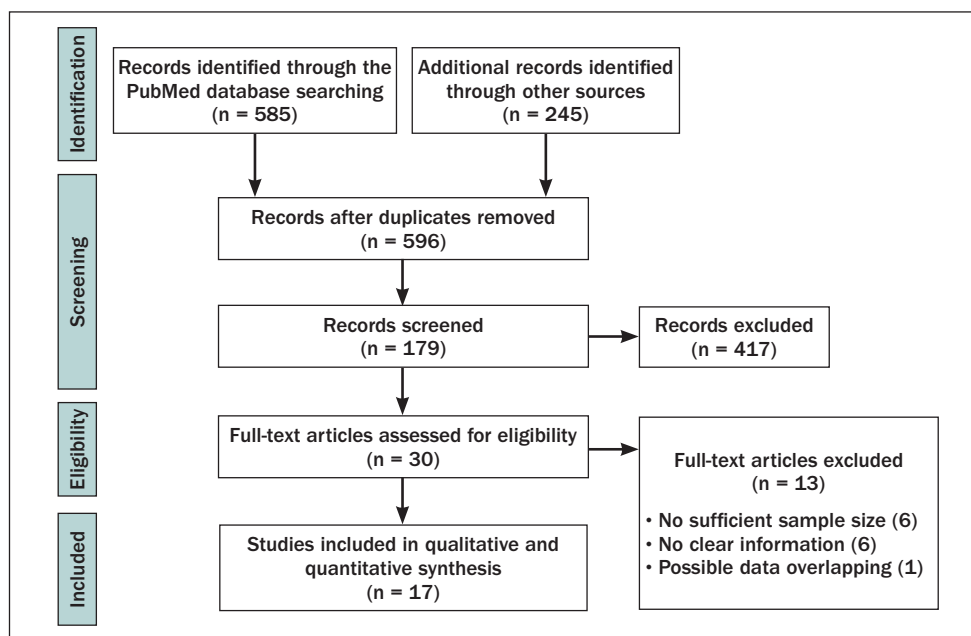


Fig 1 Flow chart of the screening process.

RESULTS

Study Selection

An initial screening yielded a total of 596 articles, of which 179 potentially relevant articles were selected after evaluation of their abstracts. Full texts of 30 articles were then obtained and reviewed. Of these, 17 articles met the inclusion criteria and subsequently were analyzed (Fig 1). Articles with case reports or fewer than 10 subjects were excluded.^{19,26–30} In addition, six studies were excluded because data provided were inadequate.^{31–36} Eventually, one more study was excluded after contacting the corresponding author because it had been included in two consecutive publications.²¹ This article was confirmed to have overlapping data and was excluded to avoid risk of bias. All the studies included were prospective^{37–45} and retrospective trials (ie, case series [evidence level 4] and cohort studies [evidence level 3]).^{20,44,46–52} Details of all included studies are summarized in Table 1.

Study Quality

The NOS was used to appraise the quality of included studies for a proper understanding of nonrandomized studies.²³ Because no nonrandomized controlled trials were found in the screening process, the 17 included studies were analyzed with NOS. A Cohen kappa interagreement rate of 0.82 was reached (labeled as “almost perfect”). After discussing the disagreements between the examiners (B.E. and A.M.) and a third consultant (J.G.A.), a mean NOS score of 5.23 ± 1.77 was obtained.

Implant Survival Rate

Of the studies that used FTF elevation for ARS, 10 studies^{37,38,42–45,47,49–51} provided survival data and could be included in the meta-analysis. The WM of survival rate was 97.0% (range, 94.4% to 100%; 95% CI = 95.8% to 97.9%; Table 2). Using the chi-square test, $P = .78$, representing no statistically significant heterogeneity among studies. Using PTF for ARS, seven studies^{20,39–41,46,47,52} provided survival data and could be included in the meta-analysis. The WM survival rate was 95.7% (range, 86.6% to 100%; 95% CI = 91.9% to 97.7%; Table 3). $P = .43$ with the chi-square test, which represented no statistically significant heterogeneity among studies.

Horizontal Bone Width Gain

The WM horizontal bone width gain was calculated for studies that used FTF for ARS. Four studies^{44,47,49,51} provided data and could be included in the meta-analysis. The WM bone width gain was 3.19 mm (range, 2.00 to 4.03 mm, with a 95% CI of 2.19 to 4.20 mm (Table 4). $P = .54$ with the chi-square test, which represented low heterogeneity among studies. For studies using PTF for ridge splitting, only one study⁴⁷ provided mean and standard deviation of horizontal bone width gain (4.13 ± 3.13 mm); hence, that study could not be included in the meta-analysis.

Publication Bias

To investigate potential publication bias, the funnel plots of meta-analyses are shown in Fig 2a (primary outcome, FTF), Fig 2b (primary outcome, PTF), and Fig 2c (secondary outcome, FTF).

Table 2 Meta-analysis of the Implant Survival Rate for the Studies that Used the FTF Procedure for Ridge Splitting*

	No. of implants	SR (%)	Lower limit	Upper limit		Weight %
Sethi and Kaus ⁴⁵ (2000)	371	97.0	94.7	98.3		36.7
Sohn et al ⁵⁰ (2010)	74	98.8	91.0	99.9		3.0
Basa et al ³⁷ (2004)	120	100.0	93.7	100.0		1.7
Danza et al ⁴⁸ (2009)	220	96.1	92.6	98.0		28.0
Jensen et al ⁴⁷ (2009)	3	94.4	69.3	99.2		3.2
Blus and Szmukler-Moncler ²¹ (2006)	180	97.2	93.5	98.0		16.7
Holtzclaw et al ⁴⁹ (2010)	31	97.0	80.4	99.6		3.1
Demetriades et al ⁴³ (2011)	34	96.2	81.4	99.3		4.2
Anitua et al ⁵¹ (2013)	37	100.0	82.2	99.9		1.7
Rahpeyma et al ⁴⁴ (2013)	82	100.0	91.1	100.0		1.7
All	1,152	97.0	95.8	97.9		100.0

*Weighted implant survival rate was 97% (95% CI = 95.8–97.9).
FTF = full-thickness flap; SE = standard error.

Table 3 Meta-analysis of the Implant Survival Rate for Studies that Used the PTF Procedure for Ridge Splitting*

	No. of implants	SR (%)	Lower limit	Upper limit		Weight %
Scipioni et al ²⁰ (1994)	329	98.5	96.4	99.4		16.0
Engelke et al ⁴¹ (1997)	124	86.6	79.4	91.6		19.7
Chiapasco et al ³⁹ (2006)	110	97.3	91.9	99.1		13.5
Bravi et al ⁴⁶ (2007)	1,715	95.7	94.6	96.6		21.8
Jensen et al ⁴⁷ (2009)	45	93.3	81.2	97.8		13.3
Ella et al ⁴⁰ (2014)	64	100.0	88.9	100.0		4.6
Garcez-Filho et al ⁵² (2014)	40	95.0	82.1	98.7		11.1
All	2,427	95.7	91.9	97.7		100.0

*Weighted mean implant survival rate was 95.7% (95% CI = 91.9–97.7%).
FTF = full-thickness flap; SE = standard error.

Table 4 Meta-analysis of Horizontal Bone Width Gain for Studies that Used the FTF Procedure for Ridge Splitting*

	No. of defects	Mean bone gain (mm)	SR (%)	Lower limit	Upper limit		Weight %
Jensen et al ⁴⁷ (2009)	13	3.44	0.40	2.66	4.22		22.5
Holtzclaw et al ⁴⁹ (2010)	17	4.03	0.16	3.71	4.35		25.5
Anitua et al ⁵¹ (2013)	17	3.35	0.08	3.19	3.51		26.0
Rahpeyma et al ⁴⁴ (2013)	21	2.00	0.07	1.87	2.13		26.0
All	68	3.19	0.26	2.19	4.20		100.0

*Weighted mean bone gain was 3.19 (95% CI = 2.19–4.20).
FTF = full-thickness flap; SE = standard error.

Role of Grafting Material and/or Membrane Usage on Final Outcome

Two confounding factors, the use of bone grafting materials or membranes, were analyzed using meta-regression. In the FTF group, the two confounding factors did not significantly influence the primary outcome in any subgroup or combined analysis ($P = .35$

for the use of bone grafting materials and $P = .73$ for the use of membrane). In the PTF group, the use of membranes was not considered as a confounding factor ($P = .08$). However, the use of bone grafting materials showed a significant difference compared with nongrafting procedures ($P < .0001$; Fig 3).

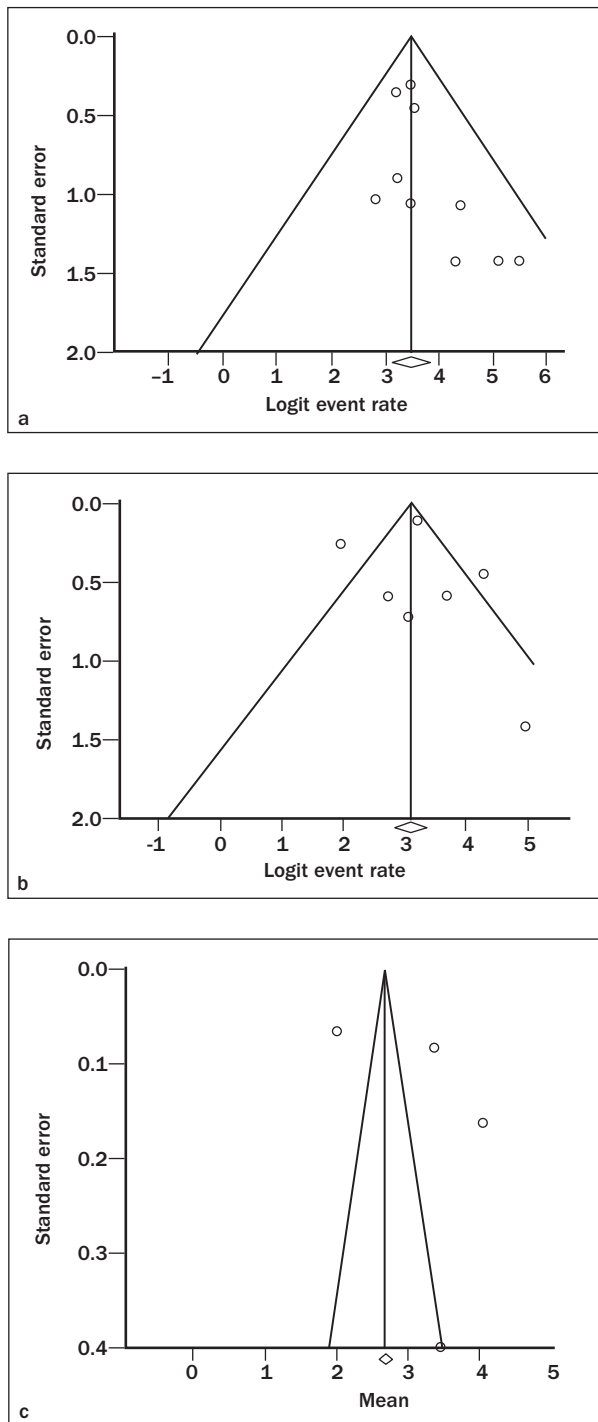


Fig 2 Funnel plots of meta-analyses displaying the risk of bias for the (a) primary outcome of FTF, (b) primary outcome of PTF, and (c) secondary outcome of FTF. The funnel plots are asymmetric and may have resulted from potential publication or selection bias.

Intra- and Postoperative Complications

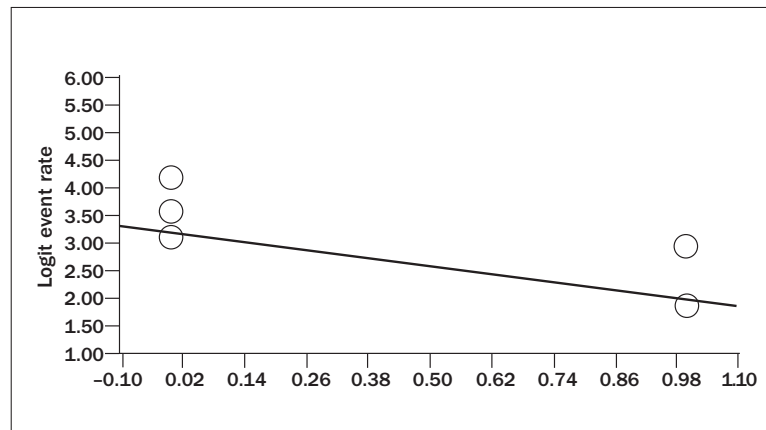
Overall, eight articles reported the presence of complications.^{20,39,40,42-44,47,50} The reasons are described below and summarized in Table 5.

- Bone fracture: Buccal wall fracture represented the most frequent postoperative complication. Ella et al⁴⁰ described 3-mm fractures in the crests of the buccal wall in 43% of cases. It was stressed that a narrower initial crest width increased the risk of fracture. Likewise, Sohn et al⁵⁰ reported five fractures of the buccal wall with the FTF procedure. Two patients with the PTF procedure had buccal wall fracture, whereas lingual wall fracture occurred in one case of FTF.⁴⁷ Ferrigno et al⁴² also noticed one fracture of the mandibular buccal plate. Rahpeyma et al,⁴⁴ on the other hand, reported one fracture of the lingual plate in the mandible at the time of implant placement (which did not extend beyond 5 mm in the apical direction).
- Bone resorption: Ella et al⁴⁰ found that 47% of the crests displayed bone resorption around the implants and had a much higher resorption rate (25%) in the more narrow ridges (3 mm). Jensen et al⁴⁷ described facial bone loss of 2 mm or more in 11 sites, of which 10 had the FTF procedure. Demetriades et al⁴³ reported only one case of total full resorption in the FTF group.
- Soft tissue recession: Jensen et al⁴⁷ found that 10 subjects had 2- to 3-mm recessions when undergoing FTF. Eight subjects who had PTF presented recessions of 2 mm. However, they reported only one case of 2-mm recession with a flapless approach.
- Prosthetic complications: Garcez-Filho et al⁵² reported six cases of abutment screw loosening and two cases of ceramic fracture. In addition, Jensen et al⁴⁷ found two cases in which the implants were tilted, thus leading to esthetic disharmony.
- Sensory disorders: Chiapasco et al³⁹ observed paresthesia in the region of the inferior alveolar nerve for 2 months in one subject and prolonged pain in the expanded area in another subject, which resolved spontaneously 1 month after surgery. Furthermore, Engelke et al⁴¹ reported postoperative pain in four patients because of the presence of hydroxyapatite between the mucosa and the membrane.

DISCUSSION

Unavoidable bone resorption occurs after tooth extraction for which bone augmentation approaches must be used when opting for oral rehabilitation with dental implants. Indeed, a wide variety of studies have described successful outcomes with numerous techniques/approaches. It is important to note that regardless of the approach, vertical augmentation is

Fig 3 Meta-regression showing bone grafting material placement at the ridge-splitting stage using a partial-thickness flap approach.



still considered unpredictable. However, horizontal bone gain is considered foreseeable; nonetheless, the best approach to use will rely on the initial clinical presentation. Simultaneous GBR might be claimed when primary stability is achieved in the pristine bone, but it may have esthetic concerns. On the other hand, more traumatic treatment alternatives (ie, bone block grafting or ARS) exist, which aim to augment osseous tissues in the severely resorbed maxillary ridges. ARS is shown to be reliable when there is a minimal amount of cortical bone (≥ 1 mm) on both sides, with an existing trabecular region in between. Recently, Milinkovic and Cordaro⁶ demonstrated that a mean implant survival rate of 97.4% could be obtained with minimal technical complications when using ARS. Our findings agreed with their results. We found that regardless of the approach (FTF vs PTF), ARS is a predictable technique ($> 95.7\%$ implant survival rate) to augment bone horizontally within the range of 3.19 to 4.13 mm, depending on the approach (Fig 4 and Table 6). In addition, the implant survival rate was found to be high. This was shown to be statistically indistinct for PTF (95.7%) vs FTF (97%). Our hypothesis indicates that this slight difference might be attributed to the reduced visibility when performing a PTF. Strikingly, Engelke et al⁴¹ showed the highest failure rate (13.3%). This higher failure rate may be attributed to the PTF approach that they adopted. In addition, the study was conducted in 1997, when the technique was premature.

Table 5 Intra- and Postoperative Biologic Complications Reported in the Included Studies

Authors (year)	Biologic complications related to ridge-split (number of cases)
Ella et al ⁴⁰ (2014)	Majority of resorption occurred in the expanded ridges that were not filled with SBS 60/40. Higher resorption rate (25% of cases) in the narrowest ridges (3 mm). Also, ridges presented a fracture 3 mm wide (43% of cases).
Chiapasco et al ³⁹ (2006)	Transient paresthesia (1), protracted pain (1), and cortical plate fracture (1)
Demetriades et al ⁴³ (2011)	Complete facial bone resorption and implant mobility 4 months after split ridge augmentation (1)
Ferrigno et al ⁴² (2005)	Fracture of the labial or palatal cortical plates for all patients treated with tapered effect implants Fracture of the labial plate occurred (1), the vestibular cortical plate was removed (2), minor fractures at the crest that did not extend beyond 3–4 mm occurred, fractures of the coronal part of the labial plate (3)
Rahpeyma et al ⁴⁴ (2013)	In mandible, inserted implants in more lingual position, and fracture of lingual plate (1)
Jensen et al ⁴⁷ (2009)	OPF = Recession of 2 mm (1) PTF = Recession of 2 mm (8) FTF = Recession of 2 or 3 mm (10)
Scipioni et al ²⁰ (1994)	Implant fracture (4) and implant loose (8)
Sohn et al ⁵⁰ (2010)	Fracture in simultaneous implant placement (21%), ossification of the osteotomy line (1), and malfractured buccal plates (5)

SBS = synthetic bone substitute; OPF = osteoperiosteal flap; PTF = partial thickness flap; FTF = full thickness flap.

With the improvements in the technique and implant surfaces, survival rates in both groups are much higher. In fact, survival rates obtained in the present study are within the standards for success in implant dentistry.^{53,54}

FTF reflection induces surface bone resorption and delayed bone repair. In other words, a PTF may preserve blood supply and thus achieve more bone gain and less bone resorption. However, Wood et al⁵⁵ found that crestal bone resorption could be minimized with FTF (0.62 mm) compared with PTF (0.98 mm). Nonetheless, owing to

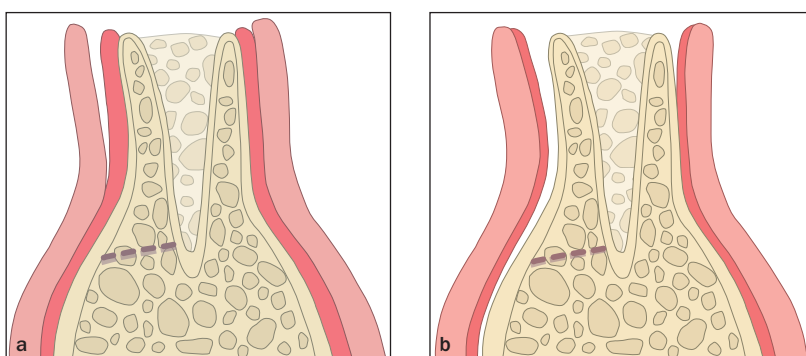


Fig 4 Graphic representation of the (a) partial-thickness flap approach and (b) full-thickness flap approach

Table 6 Clinical Outcomes for Each Group Studied

	PTF	FTF
Articles included (n)	7	10
Implant survival rate (%)	95.7	97
Horizontal bone gain (mm)*	4.13 ± 3.13	3.19 ± 1.19
Grafting material†	Yes	No
Barrier membrane‡	No	No

*Data are means ± standard deviations.

†Indicates whether it has a beneficial effect on primary outcome.

‡PTF = partial thickness flap; FTF = full thickness flap.

the small sample size, these findings cannot be reliably extrapolated. Staffileno⁵⁶ showed that the osteoclast activity is higher and collagen content is lower in FTF and hence, more bone resorption might be expected. Because of this high variability of findings among studies, the authors could not carry out a statistical analysis to compare both groups. Later, Jensen et al⁴⁷ in a retrospective cohort human study compared the horizontal bone gain achieved with both the FTF and PTF approaches. Results showed higher bone gain in the PTF group (4.13 ± 3.13 mm) compared with the FTF group (3.19 ± 1.19 mm). However, that study had only one individual in the PTF group, so the results must be interpreted cautiously. Recently, a study using a miniature pig model showed that 12 weeks after ARS, the buccal bone thickness in the mucosal flap group was 0 mm at implant shoulder and 2.56 mm at 4 mm apical to the same mark.⁵⁷ Keeping in mind the aforementioned studies, it is interesting to note that by reflecting FTF, the clinician is able to overbuild the outer cortical layer, which has been found to be very beneficial in horizontal bone gain.⁵⁸ This reconfirmed the study of Jensen et al⁴⁷ who also suggested that the FTF approach is more important for the initial ridge width of < 4 mm.

Biomaterials have been shown to be effective in assisting the process of GBR.^{59,60} Although bone substitutes such as xenogeneic grafts act as scaffolds for

osteogenic cell migration, some allogeneic grafts (ie, demineralized freeze-dried bone allografts) osteoinduce bone formation.⁶¹ In addition to these grafting materials, numerous biologic agents (ie, bone morphogenetic proteins or platelet-rich plasma) demonstrated acceleration of the different stages of bone healing.⁶² Accordingly, the findings of the present study showed that implant survival rate for PTF is improved when the void spaces are filled out with grafting materials. Likewise, owing to the high heterogeneity, it was not possible to perform a meta-analysis of the influence of material type on any of the outcomes studied. However, as pointed out earlier, placement of grafting material may assist in preserving/building three-dimensional bone morphology.⁶³ Interestingly, the present study did not find any beneficial effect of membrane placement during ARS, regardless of whether they used the FTF or PTF approach. Again, high heterogeneity was found in the studies analyzed.

Milinkovic and Cordaro⁶ reported a complication rate of 6.8%, with buccal wall fracture being the most frequent. Likewise, the present systematic review showed wall fracture (either the buccal or the lingual) to be the most prevalent intraoperative complication. Ella et al⁴⁰ showed that the vast majority of fractures occurred in crests narrower than 3 mm. Henceforth, if at least 1 mm of the spongiosa is not present between both cortical layers, a complete buccal wall fracture is more likely to occur.⁴⁷ Therefore, the ARS approach should be reserved only for ridges with a minimum diameter of 3 mm to minimize fracture incidence. Nonetheless, if a fracture is noted, it can be corrected by fixing the fracture plates with fixation screws.²¹ A factor that typically is not studied is the ridge shape. In this sense, if the base of the crest is narrow (< 3 mm) or if the walls have an “hourglass” morphology, a different approach should be considered because of the high incidence of wall fracture associated with this procedure. Lastly, but not of minor importance, is the implant geometry; a tapered-shape implant should be slightly better than the parallel design to not only minimize the fracture incidence but also achieve higher primary stability.

Future Directions

Although ARS for horizontal bone augmentation is a widely studied technique, more clinical trials should be conducted to investigate the factors that may increase the predictability of this approach. An example is to study the influence of flap reflection on ridge dimensions using digital images. It is worthwhile to explore the influence of grafting materials and use of membranes in conjunction with the ARS. The biologic behaviors of these materials could be studied further; thus far, only one clinical research included histologic analysis.³⁰ As a matter of fact, ARS might represent a potential model for studying grafting materials in a sealed cavity. With recent advances in tissue engineering for regenerative medicine,^{64–66} the application of different growth factors and biologics into customized scaffolds and carriers for ARS will possibly be another future research field.

CONCLUSIONS

In selected scenarios, ARS might be considered a predictable approach that demonstrates a high implant survival rate, adequate horizontal bone gain, and minimal intra- and postoperative complications. Further research is needed to determine the influence of grafting materials inserted, flap tissue biotype, and the anatomical characteristics on final bone augmentation outcomes.

ACKNOWLEDGMENTS

The authors do not have any financial interests, either directly or indirectly, in the products or information listed in this article. This study was partially supported by the University of Michigan Periodontal Graduate Student Research Fund, the Department of Oral Surgery and Implantology of the International University of Catalonia (Barcelona, Spain), and by the Foundation for the Study of the Implantology, Oral and Maxillofacial Surgery (Fedi-com, Badajoz, Spain). In addition, the authors thank Ms Marta Aguilà and Ms Vanessa Ruiz (Associate Professor, Department of Periodontics, International University of Catalonia, Barcelona, Spain) for designing the figures in this study.

REFERENCES

- Pietrokovski J, Massler M. Ridge remodeling after tooth extraction in rats. *J Dent Res* 1967;46:222–231.
- Pietrokovski J, Massler M. Alveolar ridge resorption following tooth extraction. *J Prosthet Dent* 1967;17:21–27.
- Schropp L, Wenzel A, Kostopoulos L, Karring T. Bone healing and soft tissue contour changes following single-tooth extraction: A clinical and radiographic 12-month prospective study. *Int J Periodontics Restorative Dent* 2003;23:313–323.
- Lekovic V, Kenney EB, Weinlaender M, et al. A bone regenerative approach to alveolar ridge maintenance following tooth extraction. Report of 10 cases. *J Periodontol* 1997;68:563–570.
- Bartee BK. Extraction site reconstruction for alveolar ridge preservation. Part 1: Rationale and materials selection. *J Oral Implantol* 2001;27:187–193.
- Milinkovic I, Cordaro L. Are there specific indications for the different alveolar bone augmentation procedures for implant placement? A systematic review. *Int J Oral Maxillofac Surg* 2014;43:606–625.
- Wang RE, Lang NP. Ridge preservation after tooth extraction. *Clin Oral Implants Res* 2012;23(suppl 6):147–156.
- Chen ST, Wilson TG Jr, Hammerle CH. Immediate or early placement of implants following tooth extraction: Review of biologic basis, clinical procedures, and outcomes. *Int J Oral Maxillofac Implants* 2004;19(suppl):12–25.
- Pieri F, Corinaldesi G, Fini M, Aldini NN, Giardino R, Marchetti C. Alveolar ridge augmentation with titanium mesh and a combination of autogenous bone and anorganic bovine bone: A 2-year prospective study. *J Periodontol* 2008;79:2093–2103.
- Zuffetti F, Esposito M, Capelli M, Galli F, Testori T, Del Fabbro M. Socket grafting with or without buccal augmentation with anorganic bovine bone at immediate post-extractive implants: 6-month after loading results from a multicenter randomised controlled clinical trial. *Eur J Oral Implantol* 2013;6:239–250.
- Monje A, Monje F, Galindo-Moreno P, Montanero-Fernandez J, Suarez F, Wang HL. Microstructural and densitometric analysis of extra oral bone block grafts for maxillary horizontal bone augmentation: A comparison between calvarial bone and iliac crest. *Clin Oral Implants Res* 2014;25:659–664.
- Monje A, Monje F, Hernandez-Alfaro F, et al. Horizontal bone augmentation using autogenous block grafts and particulate xenograft in the severe atrophic maxillary anterior ridges. *J Oral Implantol* 2014 April 4 [Epub ahead of print].
- Hernandez-Alfaro F, Sancho-Puchades M, Guijarro-Martinez R. Total reconstruction of the atrophic maxilla with intraoral bone grafts and biomaterials: A prospective clinical study with cone beam computed tomography validation. *Int J Oral Maxillofac Implants* 2013;28:241–251.
- Monje A, Monje F, Chan HL, et al. Comparison of microstructures between block grafts from the mandibular ramus and calvarium for horizontal bone augmentation of the maxilla: A case series study. *Int J Periodontics Restorative Dent* 2013;33:e153–161.
- Ortega-Oller I, Suarez F, Galindo-Moreno P, et al. The influence of implant diameter on its survival: A meta-analysis based on prospective clinical trials. *J Periodontol* 2014;85:569–580.
- Machtei EE. The effect of membrane exposure on the outcome of regenerative procedures in humans: A meta-analysis. *J Periodontol* 2001;72:512–516.
- Laino L, Iezzi G, Piattelli A, Lo Muzio L, Cicciu M. Vertical ridge augmentation of the atrophic posterior mandible with sandwich technique: Bone block from the chin area versus corticocancellous bone block allograft—clinical and histological prospective randomized controlled study. *Biomed Res Int* 2014;2014:982104.
- Herford AS, Tandon R, Stevens TW, Stoffella E, Cicciu M. Immediate distraction osteogenesis: The sandwich technique in combination with rhBMP-2 for anterior maxillary and mandibular defects. *J Craniofac Surg* 2013;24:1383–1387.
- Simion M, Baldoni M, Zaffe D. Jawbone enlargement using immediate implant placement associated with a split-crest technique and guided tissue regeneration. *Int J Periodontics Restorative Dent* 1992;12:462–473.
- Scipioni A, Bruschi GB, Calesini G. The edentulous ridge expansion technique: A five-year study. *Int J Periodontics Restorative Dent* 1994;14:451–459.
- Blus C, Szmukler-Moncler S. Split-crest and immediate implant placement with ultra-sonic bone surgery: A 3-year life-table analysis with 230 treated sites. *Clin Oral Implants Res* 2006;17:700–707.
- Liberati A, Altman DG, Tetzlaff J, et al. The PRISMA statement for reporting systematic reviews and meta-analyses of studies that evaluate health care interventions: Explanation and elaboration. *PLoS Med* 2009;6:e1000100.
- Stang A. Critical evaluation of the Newcastle-Ottawa scale for the assessment of the quality of nonrandomized studies in meta-analyses. *Eur J Epidemiol* 2010;25:603–605.

24. Khoshkam V, Chan HL, Lin GH, et al. Reconstructive procedures for treating peri-implantitis: A systematic review. *J Dent Res* 2013;92(suppl 12):1315–1385.
25. Liberati A, Altman DG, Tetzlaff J, et al. The PRISMA statement for reporting systematic reviews and meta-analyses of studies that evaluate health care interventions: Explanation and elaboration. *J Clin Epidemiol* 2009;62:e1–34.
26. Oikarinen KS, Sandor GK, Kainulainen VT, Salonen-Kemppi M. Augmentation of the narrow traumatized anterior alveolar ridge to facilitate dental implant placement. *Dental traumatology: Official publication of International Association for Dental Traumatology* 2003;19:19–29.
27. Enislidis G, Wittwer G, Ewers R. Preliminary report on a staged ridge splitting technique for implant placement in the mandible: A technical note. *Int J Oral Maxillofac Implants* 2006;21:445–449.
28. Calvo Guirado JL, Pardo Zamora G, Saez Yuguero MR. Ridge splitting technique in atrophic anterior maxilla with immediate implants, bone regeneration and immediate temporisation: A case report. *J Ir Dent Assoc* 2007;53:187–190.
29. Horrocks GB. The controlled assisted ridge expansion technique for implant placement in the anterior maxilla: A technical note. *Int J Periodontics Restorative Dent* 2010;30:495–501.
30. Gonzalez-Garcia R, Monje F, Moreno C. Alveolar split osteotomy for the treatment of the severe narrow ridge maxillary atrophy: A modified technique. *Int J Oral Maxillofac Surg* 2011;40:57–64.
31. Coatoam GW, Mariotti A. The segmental ridge-split procedure. *J Periodontol* 2003;74:757–770.
32. Siddiqui AA, Bashir SH. Giant pituitary macroadenoma at the age of 4 months: Case report and review of the literature. *Childs Nerv Syst* 2006;22:290–294.
33. Scipioni A, Calesini G, Micarelli C, Coppe S, Scipioni L. Morphogenic bone splitting: Description of an original technique and its application in esthetically significant areas. *Int J Prosthodont* 2008;21:389–397.
34. Nishioka RS, Souza FA. Bone spreader technique: A preliminary 3-year study. *J Oral Implantol* 2009;35:289–294.
35. Mazzocco F, Nart J, Cheung WS, Griffin TJ. Prospective evaluation of the use of motorized ridge expanders in guided bone regeneration for future implant sites. *Int J Periodontics Restorative Dent* 2011;31:547–554.
36. Amato F, Mirabella AD, Borlizzi D. Rapid orthodontic treatment after the ridge-splitting technique—a combined surgical-orthodontic approach for implant site development: Case report. *Int J Periodontics Restorative Dent* 2012;32:395–402.
37. Basa S, Varol A, Turker N. Alternative bone expansion technique for immediate placement of implants in the edentulous posterior mandibular ridge: A clinical report. *Int J Oral Maxillofac Implants* 2004;19:554–558.
38. Blus C, Szmukler-Moncler S, Vozza I, Rispoli L, Polastri C. Split-crest and immediate implant placement with ultrasonic bone surgery (piezosurgery): 3-year follow-up of 180 treated implant sites. *Quintessence Int* 2010;41:463–469.
39. Chiapasco M, Ferrini F, Casentini P, Accardi S, Zaniboni M. Dental implants placed in expanded narrow edentulous ridges with the Extension Crest device. A 1–3-year multicenter follow-up study. *Clin Oral Implants Res* 2006;17:265–272.
40. Ella B, Laurentjoye M, Sedarat C, Coutant JC, Masson E, Rouas A. Mandibular ridge expansion using a horizontal bone-splitting technique and synthetic bone substitute: An alternative to bone block grafting? *Int J Oral Maxillofac Implants* 2014;29:135–140.
41. Engelke WG, Diederichs CG, Jacobs HG, Deckwer I. Alveolar reconstruction with splitting osteotomy and microfixation of implants. *Int J Oral Maxillofac Implants* 1997;12:310–318.
42. Ferrigno N, Laureti M. Surgical advantages with ITI TE implants placement in conjunction with split crest technique. 18-month results of an ongoing prospective study. *Clin Oral Implants Res* 2005;16:147–155.
43. Demetriades N, Park JJ, Laskarides C. Alternative bone expansion technique for implant placement in atrophic edentulous maxilla and mandible. *J Oral Implantol* 2011;37:463–471.
44. Rahpeyma A, Khajehahmadi S, Hosseini VR. Lateral ridge split and immediate implant placement in moderately resorbed alveolar ridges: How much is the added width? *Dent Res J (Isfahan)* 2013;10:602–608.
45. Sethi A, Kaus T. Maxillary ridge expansion with simultaneous implant placement: 5-year results of an ongoing clinical study. *Int J Oral Maxillofac Implants* 2000;15:491–499.
46. Bravi F, Bruschi GB, Ferrini F. A 10-year multicenter retrospective clinical study of 1715 implants placed with the edentulous ridge expansion technique. *Int J Periodontics Restorative Dent* 2007;27:557–565.
47. Jensen OT, Cullum DR, Baer D. Marginal bone stability using 3 different flap approaches for alveolar split expansion for dental implants: A 1-year clinical study. *J Oral Maxillofac Surg* 2009;67:1921–1930.
48. Danza M, Guidi R, Carinci F. Comparison between implants inserted into piezo split and unsplit alveolar crests. *J Oral Maxillofac Surg* 2009;67:2460–2465.
49. Holtzclaw DJ, Toscano NJ, Rosen PS. Reconstruction of posterior mandibular alveolar ridge deficiencies with the piezoelectric hinge-assisted ridge split technique: A retrospective observational report. *J Periodontol* 2010;81:1580–1586.
50. Sohn DS, Lee HJ, Heo JU, Moon JW, Park IS, Romanos GE. Immediate and delayed lateral ridge expansion technique in the atrophic posterior mandibular ridge. *J Oral Maxillofac Surg* 2010;68:2283–2290.
51. Anitua E, Begona L, Orive G. Clinical evaluation of split-crest technique with ultrasonic bone surgery for narrow ridge expansion: status of soft and hard tissues and implant success. *Clin Implant Dent Relat Res* 2013;15:176–187.
52. Garcez-Filho J, Tolentino L, Sukekava F, Seabra M, Cesar-Neto JB, Araujo MG. Long-term outcomes from implants installed by using split-crest technique in posterior maxillae: 10 years of follow-up. *Clin Oral Implants Res* 2015;26:326–331.
53. Albrektsson T, Zarb G, Worthington P, Eriksson AR. The long-term efficacy of currently used dental implants: A review and proposed criteria of success. *Int J Oral Maxillofac Implants* 1986;1:11–25.
54. Misch CE, Perel ML, Wang HL, et al. Implant success, survival, and failure: The International Congress of Oral Implantologists (ICOI) Pisa Consensus Conference. *Implant Dent* 2008;17:5–15.
55. Wood DL, Hoag PM, Donnenfeld OW, Rosenfeld LD. Alveolar crest reduction following full and partial thickness flaps. *J Periodontol* 1972;43:141–144.
56. Staffileno H. Significant differences and advantages between the full thickness and split thickness flaps. *J Periodontol* 1974;45:421–425.
57. Stricker A, Fleiner J, Stubinger S, Schmelzeisen R, Dard M, Bosshard DD. Bone loss after ridge expansion with or without reflection of the periosteum. *Clin Oral Implants Res* 2014.
58. Poulas E, Greenwell H, Hill M, et al. Ridge preservation comparing socket allograft alone to socket allograft plus facial overlay xenograft: A clinical and histologic study in humans. *J Periodontol* 2013;84:1567–1575.
59. Hammerle CH, Jung RE. Bone augmentation by means of barrier membranes. *Periodontology* 2000 2003;33:36–53.
60. Hammerle CH, Jung RE, Feloutzis A. A systematic review of the survival of implants in bone sites augmented with barrier membranes (guided bone regeneration) in partially edentulous patients. *J Clin Periodontol* 2002;29(suppl 3):226–231; discussion 232–233.
61. Albrektsson T, Johansson C. Osteoinduction, osteoconduction and osseointegration. *Eur Spine J* 2001;10(suppl 2):S96–101.
62. Jung RE, Thoma DS, Hammerle CH. Assessment of the potential of growth factors for localized alveolar ridge augmentation: A systematic review. *J Clin Periodontol* 2008;35(suppl 8):255–281.
63. Hammerle CH, Araujo MG, Simion M, Osteology Consensus Group 2011. Evidence-based knowledge on the biology and treatment of extraction sockets. *Clin Oral Implants Res* 2012;23(suppl 5):80–82.
64. Taba M Jr, Jin Q, Sugai JV, Giannobile WV. Current concepts in periodontal bioengineering. *Orthod Craniofac Res* 2005;8:292–302.
65. Zhao M, Jin Q, Berry JE, Nociti FH Jr, Giannobile WV, Somerman MJ. Cementoblast delivery for periodontal tissue engineering. *J Periodontol* 2004;75:154–161.
66. Wei G, Jin Q, Giannobile WV, Ma PX. Nano-fibrous scaffold for controlled delivery of recombinant human PDGF-BB. *J Control Release* 2006;112:103–110.

Copyright of International Journal of Oral & Maxillofacial Implants is the property of Quintessence Publishing Company Inc. and its content may not be copied or emailed to multiple sites or posted to a listserv without the copyright holder's express written permission. However, users may print, download, or email articles for individual use.