



## Review

## Alveolar corticotomies for accelerated orthodontics: A systematic review



A.P.S. Gil <sup>a, b, \*</sup>, O.L. Haas Jr <sup>a, c</sup>, I. Méndez-Manjón <sup>a</sup>, J. Masiá-Gridilla <sup>a, b</sup>,  
A. Valls-Ontañón <sup>a, b</sup>, F. Hernández-Alfaro <sup>a, b</sup>, R. Guijarro-Martínez <sup>a, b</sup>

<sup>a</sup> Institute of Maxillofacial Surgery, (Director: Prof. F. Hernández-Alfaro, MD, DDS, PhD, FEBOMS. Staff surgeons: Dr. R. Guijarro-Martínez, Dr. A. Valls-Ontañón, Dr. J. Masiá-Gridilla. Staff dentist: I. Méndez-Manjón. Research fellows: Dr. A. Paredes, Dr. O.L. Haas Jr.), Teknon Medical Center, Barcelona, Spain

<sup>b</sup> Department of Oral and Maxillofacial Surgery, (Chair: Prof. F. Hernández-Alfaro, MD, DDS, PhD, FEBOMS. Assistant professors: Dr. R. Guijarro-Martínez, Dr. A. Valls-Ontañón, Dr. J. Masiá-Gridilla. PhD Student: Dr. A. Paredes), Universitat Internacional de Catalunya, Sant Cugat del Vallès, Barcelona, Spain

<sup>c</sup> Department of Oral and Maxillofacial Surgery, Pontifícia Universidade Católica do Rio Grande do Sul (PUCRS), Porto Alegre, Rio Grande do Sul, Brazil

## ARTICLE INFO

## Article history:

Paper received 26 June 2017

Accepted 27 December 2017

Available online 8 January 2018

## Keywords:

Accelerated orthodontics

Alveolar corticotomy

Rapid acceleratory phenomenon

## ABSTRACT

**Introduction:** It has been suggested that alveolar corticotomies may accelerate tooth movement, broaden the scope of malocclusion types that can be treated orthodontically, decrease the need for extractions, and support long-term stability. Several techniques have been proposed, although the indications, ideal design and technical characteristics, potential complications, and objective clinician and patient satisfaction remain unclear. This systematic review aimed to provide scientific support to validate alveolar corticotomies as a reliable approach to accelerated orthodontics.

**Material & methods:** A literature search was conducted using MEDLINE (via PubMed), Cochrane, and EMBASE electronic databases until December, 2016. Articles written in any language other than English, Spanish, French, German, and Portuguese were excluded. Randomized controlled trials, controlled clinical trials, and case series involving healthy adult patients, with a sample size of at least 5 patients, and using alveolar corticotomy techniques were included. Two reviewers extracted the data independently.

**Results:** Three randomized clinical trials, 2 prospective randomized clinical trials, 6 case series and 1 randomized controlled split-mouth study were included. No clinical trials were retrieved. Mean total treatment time in corticotomy-facilitated orthodontic cases was 8.85 months (range, 4–20 months); control groups treatment duration was 16.4 months (range, 7.8–28.3 months). Complications such as pain, swelling, and dentin hypersensitivity were reported. Few studies mentioned patient/clinician satisfaction. The faster and less invasive procedures appeared to be well tolerated. However, the methodological quality of the selected studies was low, with only low to moderate scientific evidence.

**Conclusions:** Corticotomy-facilitated orthodontics resulted in decreased treatment time. Few complications and low morbidity were found. More solid evidence-based research is required to support these results.

© 2018 European Association for Cranio-Maxillo-Facial Surgery. Published by Elsevier Ltd. All rights reserved.

## 1. Introduction

During the last decades, the number of orthodontic patients with esthetic concerns and time limitations for long treatments has increased significantly (Hernández-Alfaro and Guijarro-Martínez, 2012; İşeri et al., 2005). Simultaneously, substantial

advancements in the orthodontic field have broadened the range of potential tooth movement and increased treatment efficiency. In practical terms, for an adult this may imply a shift from a borderline extraction or orthognathic surgical case towards a more conservative approach (Einy et al., 2012).

A corticotomy is defined as a surgical procedure whereby only the cortical bone is cut, perforated, or mechanically altered (Murphy et al., 2009). Köle was the first to describe modern-day corticotomy-facilitated orthodontics. He used the term “bony block” to describe the suspected mode of movement after corticotomy (Kole, 1959). Years later, based on computed tomography

\* Corresponding author. Instituto Maxilofacial, Teknon Medical Center, Carrer Vilana, 12 (Off 185), 08022, Barcelona, Spain. Fax: +34 933 933 085.

E-mail address: [ariane.psgil@gmail.com](mailto:ariane.psgil@gmail.com) (A.P.S. Gil).

scans, Wilcko et al. demonstrated that the rapid tooth movement associated with corticotomy-facilitated orthodontics was more likely the result of a demineralization/remineralization process consistent with the initial phase of the so-called regional acceleratory phenomenon (RAP), characterized by an increase in cortical bone porosity and trabecular bone surface turnover due to augmented osteoclastic activity (Wilcko et al., 2011). This localized burst of hard tissue remodeling is reversible and results in osteopenia (Frost, 1989). Because osteopenia is characterized by reduced bone mass but no reduction in bone volume, the osteoid ingredient of bone increases while the mineral content decreases. In humans, RAP is suggested to begin within a few days of surgery, typically peaking at 1–2 months, and may take from 6 to more than 24 months to subside (Murphy et al., 2009). It may take at least one formation period of the remodeling cycle (lasting 3–4 months) after the last perturbation (Frost, 1989).

Selective alveolar corticotomy can be used in most cases in which traditional fixed orthodontic therapy is used. It has been shown to be effective in the treatment of class I malocclusion with moderate to severe crowding, class II malocclusion requiring moderate expansion or extraction, and mild class III malocclusion (Murphy et al., 2009). Close coordination between the surgeon and orthodontist is essential to achieve optimal results.

The aim of this study was to conduct a systematic review of the literature on alveolar corticotomies in order to answer the following questions:

1. Do corticotomy-facilitated orthodontics reduce treatment time in healthy adult patients, compared to conventional orthodontics?
2. Do the design of the cut and the amount of surgical trauma influence treatment outcome?
3. What is the morbidity associated to this procedure?
4. What is the degree of patient and clinician satisfaction?

## 2. Materials and methods

The eligibility criteria considered for this systematic review included: randomized controlled trials, controlled clinical trials, and case series on corticotomy-facilitated orthodontics involving healthy adult patients, with a sample size of at least 5 patients. Studies on accelerated tooth movement occurring as the result of any procedure other than corticotomies, such as orthognathic surgery, distraction osteogenesis, and pharmacological approaches, were excluded.

A comprehensive literature search was conducted using MEDLINE (accessed via PubMed), EMBASE, and Cochrane electronic databases until December 2016. No limits were applied for year of publication. Articles written in any language other than English, Spanish, Portuguese, German, and French were excluded. Only full-length articles were included. The reference lists of all selected articles were also hand searched to identify additional potentially relevant studies.

### 2.1. Search strategy

The following search strategy using Medical Subject Headings (MeSH) was applied in MEDLINE/PubMed: (“Surgical Procedure, Operative”[MeSH terms]) AND (“Alveolar Process”[MeSH terms]) AND (Tooth Movement Techniques”[MeSH terms] OR “Orthodontic”).

This search strategy was adapted for the Cochrane database using the following MeSH terms: “surgical procedures, operative” AND “alveolar process” AND (“orthodontic” OR “tooth movement techniques”).

The EMBASE database was searched using the Emtree terms ‘surgical technique’, ‘alveolar bone’, and ‘orthodontics’ for the following specific search: ‘surgical technique’/syn AND ‘alveolar bone’/syn AND ‘orthodontics’/syn.

### 2.2. Study selection

The literature search was conducted by one of the authors (1), and articles were selected independently by two authors (1,2) based on titles and abstracts. Publications that were not related to the topic or did not meet the required search strategy were excluded. Cohen’s kappa coefficient ( $\kappa$ ) was used to measure inter-rater agreement for title and abstract selection (Landis and Koch, 1977). Studies whose titles and abstracts were evaluated and were accepted in the first round of the selection process were screened for eligibility.

The same two authors performed the eligibility assessment independently, applying the inclusion criteria separately. Disagreements were resolved by discussion with a third, more experienced author (3).

### 2.3. Data extraction

Standardized data extraction tables were created for collecting selected information and findings from included studies. Data on type of surgical intervention, number of participants, reduction in total treatment time (if stated), incidence of complications (root resorption or vitality loss, periodontal problems), mean duration of the procedure, and patient/clinician satisfaction were extracted.

### 2.4. Quality assessment

Both investigators assessed the methodological quality of the included studies independently. The quality of the papers was assessed using an adaptation of the bias analysis proposed by Haas Jr et al. (2015). The criteria used by these authors are related to the randomization of the sample, statistical analysis, the definition of inclusion and exclusion criteria, and whether sample loss was reported in the postoperative period. In addition to these items, analysis of comparison data between interventions and blinding assessment were included as criteria. The item validation of measurements was excluded, as it was not applicable to this study.

With respect to the risk of bias for each study analyzed, papers containing all the above-mentioned items were considered low risk, those for which one or two items were missing were deemed medium risk, and investigations that did not include three or more items were considered high risk.

## 3. Results

### 3.1. Study selection

A total of 1,203 studies were identified in the electronic databases. After exclusion of duplicated studies, irrelevant titles and abstracts, 49 studies were selected and read in full, 46 from the main search and 3 from the manual search. At the end of the eligibility assessment, 13 articles were included in this systematic review. The search results are depicted in a Flowchart (Fig. 1).

The level of agreement between the two authors for the eligibility assessment was measured at  $k = 0.86$ .

### 3.2. Reported inclusion-exclusion criteria

#### 3.2.1. Inclusion criteria

Most patients selected for corticotomy-facilitated orthodontics were adults (Akay et al., 2009; Choo et al., 2011; Ahn et al., 2012;

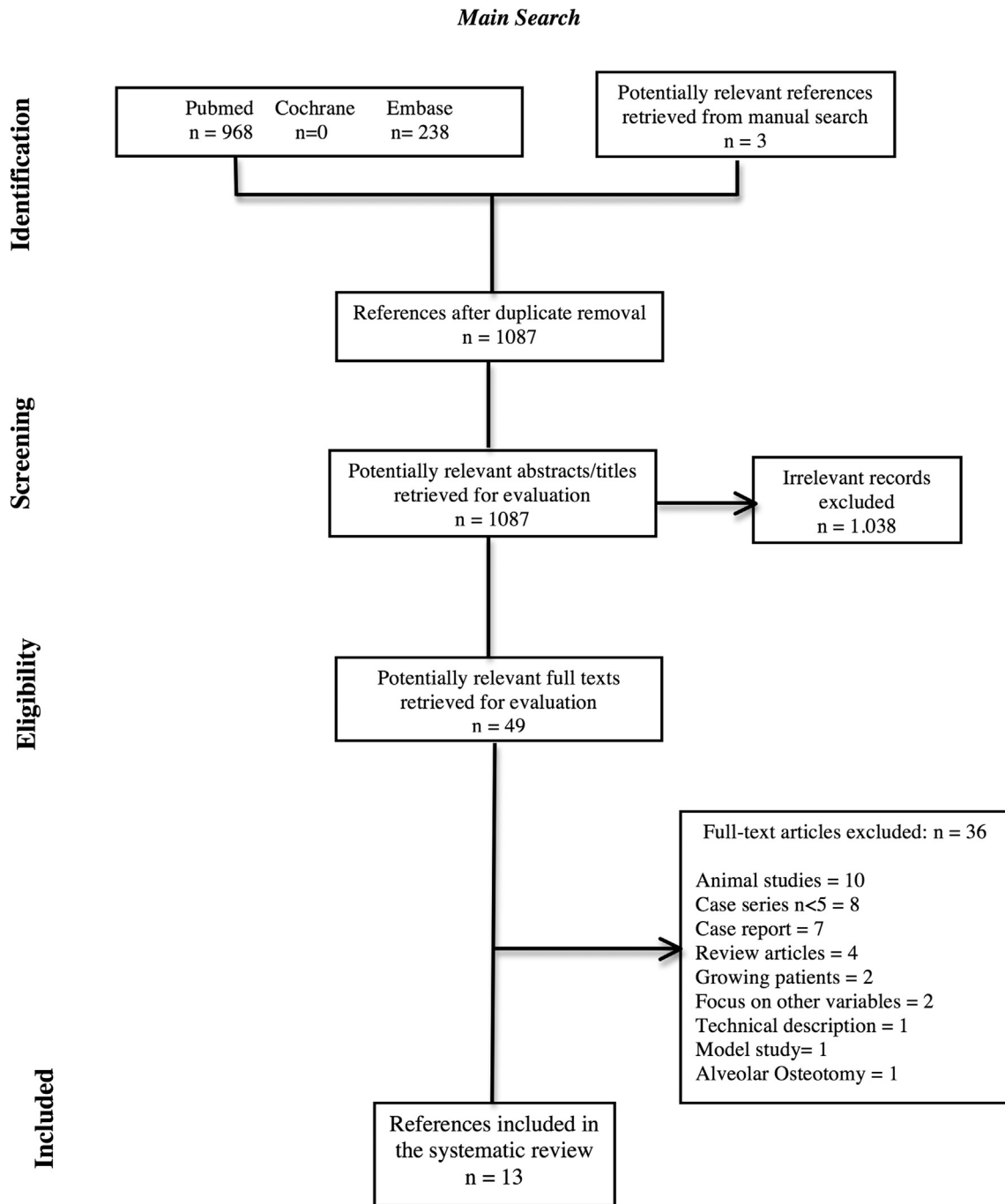


Fig. 1. Diagram flow chart.

Hernandez-Alfaro and Gujjarro-Martinez, 2012; Shoreibah et al., 2012a, 2012b; Coscia et al., 2013; Wang et al., 2012; Bhattacharya et al., 2014; Ma et al., 2016), with occlusal problems such as deep bite, posterior crossbite, open bite, and anterior crowding (Hernandez-Alfaro and Gujjarro-Martinez, 2012). The most common inclusion criteria were no signs or symptoms of temporomandibular joint disorder (Choo et al., 2011), no restorable carious teeth or congenitally missing teeth (Choo et al., 2011; Ahn et al., 2012; Al-Naoum et al., 2014; Ma et al., 2016), no craniomaxillofacial deformities affecting the normal palatal anatomy (Coscia et al., 2013; Wang et al., 2012), no history of surgery or treatment that could have caused facial soft-tissue changes (Choo et al., 2011;

Coscia et al., 2013; Al-Naoum et al., 2014; Ma et al., 2016), no systemic diseases (Choo et al., 2011; Coscia et al., 2013), and healthy periodontal tissues or well controlled periodontal health (Gantes et al., 1990; Choo et al., 2011; Coscia et al., 2013; Wang et al., 2012; Al-Naoum et al., 2014).

### 3.2.2. Exclusion criteria

Patients reporting long-term corticosteroid therapy and individuals taking medications that slow down bone metabolism, such as bisphosphonates and nonsteroidal anti-inflammatory drugs (Bhattacharya et al., 2014) were the most reported exclusion criteria.

### 3.3. Data extraction

A total of 13 publications were ultimately included in the systematic review (Table 1). Of these, 6 were case series (Akay et al., 2009; Choo et al., 2011; Ahn et al., 2012; Hernandez-Alfaro and Guijarro-Martinez, 2012; Coscia et al., 2013; Ma et al., 2016), 1 was a randomized controlled split-mouth study (Al-Naoum et al., 2014), 1 was a controlled trial (Aboul-Ela et al., 2011) and 5 were randomized clinical trials (Shoreibah et al., 2012a, 2012b; Wang et al., 2012; Bhattacharya et al., 2014).

### 3.4. Patients

Taking into account the 13 selected papers, a total of 282 patients with a mean age of 31.8 years at the time of surgery were treated with corticotomy-facilitated orthodontics. Individually, sample size ranged from 5 to 60 participants and patient age ranged from 20 to 37 years. Although Al-Naoum et al., 2014 reported an age range of 15–24 years old, it was not clinically relevant for the results presented. The study was included in this revision after discussion with the more experienced author.

The findings referred to different types of malocclusion, including skeletal class I (Shoreibah et al., 2012a, 2012b), class II division 1 and division 2 (Gantes et al., 1990; Aboul-Ela et al., 2011), class III (Ahn et al., 2012; Coscia et al., 2013; Wang et al., 2012; Bhattacharya et al., 2014; Ma et al., 2016), maxillary and mandibular protrusion (Choo et al., 2011; Ma et al., 2016) and open bite (Akay et al., 2009). Two studies assessed canine retraction (Shoreibah et al., 2012a; Al-Naoum et al., 2014). One study did not describe malocclusion characteristics (Hernandez-Alfaro and Guijarro-Martinez, 2012).

### 3.5. Type of surgical procedure

All patients treated with corticotomies received local anesthesia, except for a group that underwent corticotomies simultaneously with orthognathic surgery (Hernandez-Alfaro and Guijarro-Martinez, 2012).

Full-thickness flap retraction was performed in 65 cases on buccal or labial sites (Aboul-Ela et al., 2011; Choo et al., 2011; Ahn et al., 2012; Hernandez-Alfaro and Guijarro-Martinez, 2012; Bhattacharya et al., 2014) and in 79 cases on both sites (Gantes et al., 1990; Hernandez-Alfaro and Guijarro-Martinez, 2012; Coscia et al., 2013; Wang et al., 2012). A split-thickness flap was used in 11 patients (Ma et al., 2016). A vertical incision and tunneling dissection was performed with endoscopic assistance in a group of 9 patients (Hernandez-Alfaro and Guijarro-Martinez, 2012).

Corticotomies were performed with fissure and/or round burs (Gantes et al., 1990; Aboul-Ela et al., 2011; Ahn et al., 2012; Coscia et al., 2013; Wang et al., 2012; Al-Naoum et al., 2014) and using piezoelectric devices (Choo et al., 2011; Ahn et al., 2012; Hernandez-Alfaro and Guijarro-Martinez, 2012; Coscia et al., 2013; Ma et al., 2016). Only the cortical bone was cut in all studies. In general, corticotomies were performed as a one-stage procedure, except for 24 patients who underwent a two-stage procedure (Choo et al., 2011). Seven studies reported bone augmentation at the same time; reconstruction materials included hydroxyapatite ceramic granules, deproteinized bovine bone mineral, demineralized bovine bone particles, and autogenous bone graft with and without collagen membrane (Choo et al., 2011; Ahn et al., 2012; Hernandez-Alfaro and Guijarro-Martinez, 2012; Shoreibah et al., 2012a; Coscia et al., 2013; Bhattacharya et al., 2014; Ma et al., 2016).

### 3.6. Total treatment time

Mean total treatment time in corticotomy-facilitated orthodontic cases was 8.85 months (range, 4–20 months). When compared to conventional orthodontic treatment, the corticotomy groups had a shorter treatment time. In control groups, the mean treatment duration was 16.4 months (range, 7.8–28.3 months).

### 3.7. Complications

No periodontal damage or loss of tooth vitality was reported. Only one study reported dentin hypersensitivity in one patient (Hernandez-Alfaro and Guijarro-Martinez, 2012), who recovered without complications after 5 weeks.

One study reported moderate to severe pain and swelling within the first 7 postoperative days (Al-Naoum et al., 2014). Another study reported subcutaneous hematomas of the face and the neck (Gantes et al., 1990).

### 3.8. Quality assessment

The risk of bias was considered high in 7 studies and medium in 6 studies. No low risk studies were retrieved. The main absent quality criteria were sample randomization, blind assessment, comparison between treatments and report of follow-up (Table 2).

## 4. Discussion

In this systematic review, most of the included studies were of low to medium methodological quality and scientific evidence, resulting in several risks of bias. A meta-analysis of combined data was not possible due to the heterogeneity and low level of evidence of the retrieved articles and wide variety of outcome variables. The 12 studies included in this systematic review were selected based on strict criteria. However, there are other case reports, descriptions of techniques, systematic reviews (Hoogveen et al., 2014; Fleming et al., 2015) and opinion papers that can provide valuable clinical information, such as the case series published by Wilcko et al. (2005; 2008; 2009; 2011), Dibart and Sebaun (Sebaum et al., 2007; Dibart et al., 2009), and Vercelotti and Podesta (Vercelotti and Podesta, 2007; Bertossi et al., 2011), who describe the most common and current orthodontic techniques.

There are many indications for the use of alveolar corticotomies in orthodontic treatment. They can be used to accelerate corrective orthodontic treatment, as a whole, to facilitate the implementation of mechanically challenging orthodontic movements, and to enhance the correction of moderate to severe malocclusion.

Shortened treatment time was a common finding in the corticotomy groups (Gantes et al., 1990; Aboul-Ela et al., 2011; Choo et al., 2011; Ahn et al., 2012; Coscia et al., 2013; Wang et al., 2012; Bhattacharya et al., 2014). Mean treatment time in patients undergoing conventional orthodontic treatment was 16.4 months, while in the intervention groups it was 8.85 months. Although some studies did not report total treatment time (Aboul-Ela et al., 2011; Hernandez-Alfaro and Guijarro-Martinez, 2012; Ma et al., 2016), they measured rates of tooth movement and found that tooth movement was faster in corticotomy groups than in control groups (Akay et al., 2009; Aboul-Ela et al., 2011) or achieved results that would be hard to achieve without the use of corticotomies (Choo et al., 2011).

All corticotomy techniques focus primarily on weakening the cortical bone-tooth interface. Kole suggested that the greatest resistance to tooth movement is generated by the cortical bone of the alveolus (Kole, 1959). A smaller extent jaw bone osteotomy induces a regional, but not systemic, increase in the alveolar bone

**Table 1**  
Data extraction.

Author/year	Type of study	Mean Age	S	C	Intervention	TTT	Complications	Morbidity	Satisfaction
Ma et al., 2016	CS	Older than 18 years	11	-	Split-thickness flap until the mental region, when periosteum was incised and reflected coronally only in labial site; selective alveolar decortication with piezoelectric surgical device; vertical and horizontal cuts + deproteinized bovine bone mineral with or without autogenous bone; 1-stage procedure	Not mentioned	Not mentioned	Low	Not mentioned
Bhattacharya et al., 2014	RCT	19.3 years	20	10	Full-thickness flap retraction on buccal and palatine sites; local anesthesia; decortication with round bur from 14 to 24; vertical and horizontal cuts + demineralized freeze dried bone allograft; 1-stage procedure	4.3 months (3.5 months less than control group)	Not mentioned	Moderate	Not mentioned
Al-Naoum et al., 2014	RCT, split-mouth	20 years <sup>a</sup>	30	15	Full-thickness flap retraction on buccal and palatine sites; local anesthesia; cortical cuts with fissure and round bur in canine area; 1-stage procedure	4 months	Moderate to severe pain and swelling	Moderate	Patient: moderate; clinician: not mentioned
Coscia et al., 2013	CS	26.14 years	14	-	Full-thickness flap retraction on anterior mandible; selective alveolar decortication with piezo; vertical and horizontal corticotomies + hidroxiapatita ceramic granules + collagen membrane; luxation movement with chisel 15°; 1-stage procedure	8 ± 2 months	Not mentioned	Low	Clinician: high; patient not mentioned
Wang et al., 2012	RCT	24.15 years	56	30	Full-thickness flap preserving the papillae in labial site; vertical releasing incisions; selective alveolar decortication + deproteinized bovine bone mineral + trimmed collagen membrane; 1-stage procedure	7.8 months (5.5 months less than control group)	Not mentioned	Low	Not mentioned
Hernandez-Alfaro and Guijarro-Martinez, 2012	CS	37 years	9	-	Full-thickness vertical incision + tunneling subperiosteal dissection; local or general anesthesia; selective alveolar decortication with piezoelectric microsaw + endoscopic assistance; vertical and horizontal cuts ± demineralized bovine bone particles; 1-stage-procedure	Not mentioned	Dentary hypersensitivity (1 patient)	Low	Not mentioned
Shoreibah et al., 2012a	PRCT	22 years	20	10	Full-thickness flap retraction on labial site; local anesthesia; decortication with small round stainless steel surgical bur; vertical cuts; 1-stage procedure	4.4 months (7.8 months less than control group)	Not mentioned	Low	Clinician: high; patient not mentioned
Shoreibah et al., 2012b	PRCT	24 years	20	10	Full-thickness flap retraction on labial site; local anesthesia; decortication with small round stainless steel surgical bur; vertical cuts; 1-stage procedure; Group I received only corticotomies and Group II received corticotomies + bioactive glass	Average 4.2 months for both groups; Group II had an increased bone density of 25.8%	Not mentioned	Low	Clinician: high; patient not mentioned
Ahn et al., 2012	CS	25.15 years	15	-	Full-thickness flap retraction on labial site; local anesthesia; decortication with round bur or piezoelectric surgical device; vertical and horizontal cuts + deproteinized and mineralized bovine bone mineral; 1-stage procedure	7.43 months	-	Low	Not mentioned
Choo et al., 2011	CS	27.3 years	24	-	Full-thickness flap retraction on buccal and palatine sites; local anesthesia; cortical cuts with round bur; 2-stage procedure	20 months (3–6 months to complete retraction)	-	Moderate	Not mentioned
Aboul-Ela et al., 2011	CT	19 years	13	13	Full-thickness flap retraction on labial site; local anesthesia; cortical cuts with round bur; 1-stage procedure	Not mentioned	-	Low	Not mentioned
Akay et al., 2009	CS	15–25 years	10	-	Full-thickness flap retraction on buccal and palatine sites; local anesthesia; vertical cuts were made on the mesial side of the most anterior teeth and on the distal side of the most posterior teeth; horizontal cuts 2–4 mm wide; zigoma anchors and palatal titanium screws for teeth intrusion; 1-stage procedure	4–5 months	-	Moderate	Not mentioned
Gantes et al., 1990	RCT	21–32 years	10	5	Full-thickness flap retraction on buccal and palatine sites; vertical releasing; local anesthesia; decortication with fissure and round bur on both sites; buccal and palatine cortical bone was removed over the extraction sites; 1-stage procedure	14.8 (13.5 months less than control group)	Subcutaneous hematoma (1 patient)	Moderate	Patient: less traumatic than expected; clinician: not mentioned

\*CS: Case series; CT: Controlled trial; RCT: Randomized Clinical Trial; PRCT: Prospective Randomized Clinical Trial; S: patients included; C: presence or absence of control groups; TTT: Total Treatment Time.

<sup>a</sup> Al-Naoum et al. reported an age range from 15 to 24 years.

**Table 2**  
Quality assessment.

Author/year	Sample Randomization	Comparison between treatments <sup>a</sup>	Blind Assessments	Statistical Analysis	Defined inclusion/exclusion criteria	Report of follow-up <sup>b</sup>	Risk of bias assessment
Ma et al., 2016	No	No	No	Yes	Yes	No	High
Bhattacharya et al., 2014	Yes	Yes	No	Yes	Yes	Yes	Medium
Al-Naoum et al., 2014	Yes	Yes	No	Yes	Yes	Yes	Medium
Coscia et al., 2013	No	No	No	Yes	Yes	Yes	High
Wang et al., 2012	No	Yes	No	Yes	Yes	Yes	Medium
Hernandez-Alfaro and Guijarro-Martinez, 2012	No	No	No	No	Yes	No	High
Shoreibah et al., 2012a	Yes	Yes	No	Yes	Yes	Yes	Medium
Shoreibah et al., 2012b	Yes	Yes	No	Yes	Yes	Yes	Medium
Ahn et al., 2012	No	No	No	Yes	Yes	Yes	High
Aboul-Ela et al., 2011	Yes	Yes	No	Yes	Yes	No	Medium
Choo et al., 2011	No	No	No	Yes	Yes	Yes	High
Akay et al., 2009	No	No	No	Yes	Yes	Yes	High
Gantes et al., 1990	No	No	No	No	Yes	Yes	High

Risk of bias assessment: high = 0–3 'Yes'; medium = 4–5 'Yes'; low = 6 'Yes'.

<sup>a</sup> Comparison between 'gold standard' treatment (control group) and the treatment being tested (experimental group), in this case, patients receiving or not selective alveolar corticotomy.

<sup>b</sup> Mean treatment time.

turnover rate and bone porosity. This indicates that more extensive jaw bone surgeries might induce a more intense increase in bone turnover and porosity (Teng and Loui, 2014). In the same vein, Frost (1989) suggested that the duration and intensity of the RAP are proportional to the extent of injury and soft tissue involvement in the injury. However, whether the extent of mucoperiosteal flap affects the intensity of alveolar bone reactions remains unclear and needs further investigation (Teng and Loui, 2014).

A total of 5 studies reported procedures with mucoperiosteal flaps including both buccal/labial and palatal sites (Choo et al., 2011; Ahn et al., 2012; Hernandez-Alfaro and Guijarro-Martinez, 2012; Bhattacharya et al., 2014; Ma et al., 2016). Only one study reported increased discomfort and pain associated with the use of mucoperiosteal flap within the first 7 postoperative days (Al-Naoum et al., 2014). In another study, although this technique resulted in some discomfort, patients felt that the procedure was less traumatic than tooth extraction (Gantes et al., 1990). None of the studies described the specific duration of the procedures, but these flaps are associated with increased operative time, implying increased morbidity and discomfort (Hernandez-Alfaro and Guijarro-Martinez, 2012).

The box-shaped corticotomy, with horizontal and vertical cuts, was commonly used by the selected groups, being performed in the anterior mandible (Gantes et al., 1990; Akay et al., 2009; Hernandez-Alfaro and Guijarro-Martinez, 2012; Coscia et al., 2013; Wang et al., 2012) and anterior and/or posterior maxilla (Choo et al., 2011; Ahn et al., 2012; Hernandez-Alfaro and Guijarro-Martinez, 2012; Shoreibah et al., 2012a, 2012b; Al-Naoum et al., 2014; Bhattacharya et al., 2014; Ma et al., 2016). Al-Naoum et al. and Aboul-Ela et al. limited the corticotomies to the canine region. Akay et al. made vertical cuts on the mesial side of the most anterior teeth and on the distal side of the most posterior teeth to maximize intrusion of the anterior segment. All authors made the cuts through the cortical bone until reaching the medullary bone, without fracture or damage to the medullary bone.

The use of burs (Gantes et al., 1990; Aboul-Ela et al., 2011; Ahn et al., 2012; Cassetta et al., 2012; Coscia et al., 2013) or piezoelectric (Akay et al., 2009; Wilcko et al., 2011; Ahn et al., 2012; Hernandez-Alfaro and Guijarro-Martinez, 2012; Coscia et al., 2013; Ma et al., 2016) devices was frequently reported, but indications for the use of one or another instrument were not specified. Piezosurgery allows safe performance of corticotomies around the root. Bone regeneration is thus more likely and healing appears to be better (Wilcko et al., 2005). Cutting bone with burs implies potential

damage to the teeth attributable to close root proximity and impaired bone regeneration as a result of excessive heat (piezocision). In this review, there was no increased morbidity associated with the use of burs. In 2012, Casseta et al. reported that there was no statistically significant difference in the duration of the procedure when comparing the use of piezoelectric devices versus burs, and that in both groups discomfort and pain were present regardless of the cutting technique used.

The periodontally accelerated osteogenic orthodontics (PAOO) technique proposed by Wilcko (Wilcko et al., 2005, 2009) has the additional advantage of increased bone width when bone grafting is performed. Alveolar bone grafting is believed to be responsible for the increased alveolar bone width after treatment, which may contribute to improved long-term stability (Frost, 1989). It has been shown that connective tissue grafting for root coverage is feasible with full-thickness flap reflection and bone activation and can be included in the surgical procedure or performed after the debracketing (Wilcko et al., 2005). A total of 7 studies included in this review reported concomitant bone grafting/augmentation (Ahn et al., 2012; Shoreibah et al., 2012a; Coscia et al., 2013; Wang et al., 2012; Bhattacharya et al., 2014; Ma et al., 2016). The materials used varied according to the surgeon's preference, and the advantages and disadvantages of each material in this context were not mentioned.

Surgical complications appear to be minimal, but there are no available controlled data to support this assumption. Corticotomies may lead to gingival recession (Wilcko et al., 2005). In the maxilla, the use of hammer and chisel increases the risk of benign paroxysmal positional vertigo, which has been documented in many cases (Al-Naoum et al., 2014). No periodontal damage or loss of tooth vitality was reported in this review. Only one study reported dentin hypersensitivity in one patient (Hernandez-Alfaro and Guijarro-Martinez, 2012), who recovered without complications after 5 weeks.

Some procedures can take more than 3 h and increase morbidity (Murphy et al., 2009). Overall, there were no details regarding the duration of the procedure in the included studies, only one reported a mean duration of 26 min (Hernandez-Alfaro and Guijarro-Martinez, 2012) and was associated with excellent postoperative recovery. There was one case of severe pain and swelling within the first 7 postoperative days (Al-Naoum et al., 2014) and a report of subcutaneous hematomas of the face and the neck (Gantes et al., 1990). In the studies included in this systematic review, there were few complications with low to moderate morbidity.

Alveolar corticotomies can be problematic in, but not limited to, situations where the patient has been on long-term corticosteroid therapy and may have devitalized areas within the bone, which makes them not good candidates for treatment (Wilcko et al., 2009). In addition, patients who are taking any of many medications that slow bone turnover are not suitable for this treatment (Bell and Levy, 1970). Bisphosphonates can have a half-life exceeding a decade, and even after cessation of therapy these patients are not good candidates for this approach (Wilcko et al., 2009). NSAIDs are prostaglandin inhibitors, and their use will lead to decreased osteoclastic activity. Therefore, the use of NSAIDs in the amount needed for pain control should be avoided during active treatment, but analgesics can be prescribed for the first week after surgery (Bell and Levy, 1970). Any pre-existing oral infections should be resolved before initiating treatment (Wilcko et al., 2009). Retaining teeth with unresolved endodontic problems can be particularly problematic and must be avoided. All the above-mentioned risk factors were used as exclusion criteria for patient selection in the included studies. Careful patient selection is probably a critical factor for clinical success and may have been related to the positive findings reported in this systematic review.

Only 5 studies mentioned patient/clinician satisfaction (Gantes et al., 1990; Shoreibah et al., 2012a, 2012b; Coscia et al., 2013; Al-Naoum et al., 2014). Coscia et al. reported high clinician satisfaction, stating that corticotomy associated with bone augmentation and periodontal reconstruction can overcome the patient's anatomical limitations and improve the entire treatment design. Al-Naoum et al. did not allow the use of NSAIDs at any time after surgery and reported high levels of pain and discomfort within the first 7 postoperative days. However, when asked, patients reported more discomfort with premolar extraction than with the corticotomy procedure. Gantes et al. reported good patient outcome perception, and the level of discomfort during and after surgery was much lower than expected.

## 5. Conclusion

There has been a growing interest in the use of alveolar corticotomies as an adjunct to orthodontic treatment due to a deeper understanding of its effects and more solid evidence-based research. The biological stimulus produced by corticotomies is reflected in the trabecular bone structure and thus provides an opportunity to enhance certain orthodontic movements. The design of the corticotomy cuts and perforations seems to be irrelevant, but it seems clear they must perforate the cortical layer of bone and extend only into the superficial aspect of the medullary bone. In the context of adequate patient selection, corticotomies can be a powerful and safe tool to improve the quality and duration of orthodontic treatments.

## Ethical approval

Not required.

## Funding

This study received no funding.

## Conflicts of interest

None of the authors have financial interest in any of the products, devices, or drugs mentioned in this manuscript.

## References

Aboul-Ela SMBE, El-Beialy AR, El-Sayed KMF, Selim EMN, EL-Mangoury NH, Mostafa YA: Miniscrew implant-supported maxillary canine retraction with and

- without corticotomy-facilitated orthodontics. *Am J Orthod Dentofac Orthop* 139: 252–259, 2011
- Ahn HW, Lee DY, Park YG, Kim SH, Chung KR, Nelson G: Accelerated decompensation of mandibular incisors in surgical skeletal Class III patients by using augmented corticotomy: a preliminary study. *Am J Orthod Dent Ortho* 142(2): 199–206, 2012
- Akay MC, Aras A, Günbay T, Akyalçın S, Koyuncue BO: Enhanced effect of combined treatment with corticotomy and skeletal anchorage in open bite correction. *J Oral Maxillofac Surg* 67: 563–569, 2009
- Al-Naoum F, Hajeer MY, Al-Jundi A: Does alveolar corticotomy accelerate orthodontic tooth movement when retracting upper Canines? A split-mouth design randomized controlled trial. *J Oral Maxillofac Surg* 72: 1880–1889, 2014
- Bell WH, Levy BM: Healing after anterior maxillary osteotomy. *J Oral Surg* 28: 728–734, 1970
- Bertossi D, Vercellotti T, Podesta A, Nocini PF: Orthodontic microsurgery for rapid dental repositioning in dental malpositions. *J Oral Maxillofac Surg* 69: 747–753, 2011
- Bhattacharya P, Bhattacharya H, Anjum A, Bhandari R, Agarwal DK, Gupta A, et al: Assessment of corticotomy facilitated tooth movement and changes in alveolar bone thickness - a CT scan study. *J Clin Diagn Res* 8(10): ZC26–ZC30, 2014
- Cassetta M, Di Carlo S, Giansanti M, Pompa V, Pompa G, Barbato E: The impact of osteotomy technique for corticotomy-assisted orthodontic treatment (CAOT) on oral health-related quality of life. *Eur Rev Med Pharmacol Sci* 16: 1735–1740, 2012
- Choo HR, Heo HA, Yoon HJ, Chung KR, Kim SH: Treatment outcome analysis of speedy surgical orthodontics for adults with maxillary protrusion. *Am J Orthod Dent Ortho* 140(6): e251–e262, 2011
- Coscia G, Coscia V, Peluso V, Addabbo F: Augmented corticotomy combined with accelerated orthodontic forces in class III orthognathic patients: morphologic aspects of the mandibular anterior ridge with cone-beam computed tomography. *J Oral Maxillofac Surg* 71: 1760.e1–1760.e9, 2013
- Dibart S, Sebaoun JD, Surmenian J: Piezocision: a minimally invasive periodontally accelerated orthodontic tooth movement procedure. *Compen Cont Edu Dent* 30(6): 342–350, 2009
- Einy S, Horwitz J, Aizenbud D: Wilckodonticis – an alternative adult orthodontic treatment method: rational and application. *Alpha Omega* 3–4: 102–111, 2012
- Fleming PS, Fedorowicz Z, Johal A, El-Angbawi A, Pandis N: Surgical adjunctive procedures for accelerating orthodontic treatment - review. *Cochrane Lib* 6: 1–40, 2015
- Frost HM: The biology of fracture healing. An overview for clinicians. Part I. *Clin Orthop Relat Rest*: 283–293, 1989
- Gantes B, Rathbun E, Anholm M: Effects on the periodontium following corticotomy-facilitated orthodontics. Case reports. *J Periodont* 61: 234–238, 1990
- Haas Jr OL, Becker OE, Oliveira RB: Computer-aided planning in orthognathic surgery—systematic review. *Int J Oral Maxillofac Surg* 44: 329–342, 2015
- Hernandez-Alfaro F, Guijarro-Martinez R: Endoscopically assisted tunnel approach for minimally invasive corticotomies: a preliminary report. *J Periodontol* 83: 574–580, 2012
- Hoogveen EJ, Jansma J, Ren Y: Surgically facilitated orthodontic treatment: a systematic review. *Am J Orthod Dentofac Orthop* 145: S51–S64, 2014
- İşeri H, Kişniçi R, Bzizi N, Tüz H: Rapid canine retraction and orthodontic treatment with dentoalveolar distraction osteogenesis. *Am J Orthod Dentofac Orthop* 127(5): 533–541, 2005
- Kole H: Surgical operations of the alveolar ridge to correct occlusal abnormalities. *Oral Surg Oral Med Oral Pathol* 12: 515–529, 1959
- Landis JR, Koch GG: The measurement of observer agreement for categorical data. *Biometrics* 33(1): 159–174, 1977
- Ma ZG, Yang C, Xi OY, Ye ZX, Zhang SY, Abdelrehem A: A novel surgical technique for augmented corticotomy-assisted orthodontics: bone grafting with periosteum. *J Oral Maxillofac Surg* 74(1): 170–180, 2016
- Murphy KG, Wilcko MT, Wilcko WM, Ferguson DJ: Periodontal accelerated osteogenic orthodontics: a description of the surgical technique. *J Oral Maxillofac Surg* 67: 2160–2166, 2009
- Sebaum JD, Ferguson DJ, Wilcko MT, Wilcko WM: Alveolar osteotomy and rapid orthodontic treatments. *Orthod Fr* 78: 217–225, 2007
- Shoreibah EA, Ibrahim SA, Attia MS, Diab MM: Clinical and radiographic evaluation of bone grafting in corticotomy-facilitated orthodontics in adults. *J Int Acad Periodontol* 14(4): 105–113, 2012a
- Shoreibah EA, Salama AE, Attia MS, Abu-Seida SM: Corticotomy-facilitated orthodontics in adults using a further modified technique. *J Int Acad Periodontol* 14(4): 97–104, 2012b
- Teng GYY, Loui ERJ: Interdental osteotomies induce regional acceleratory phenomenon and accelerate orthodontic tooth movement. *J Oral Maxillofac Surg* 72: 19–29, 2014
- Vercellotti T, Podesta A: Orthodontic microsurgery. A new surgically guided technique for dental movement. *Int J Periodontics Restor Dent* 27: 325–331, 2007
- Wang B, Shen GF, Fang B, Yu HB, Wu Y: Augmented corticotomy-assisted presurgical orthodontics of class III malocclusions: a cephalometric and cone-beam computed tomography study. *J Craniofac Surg* 24: 1886–1890, 2012

- Wilcko MT, Wilcko WM, Bissada NF: An evidence-based analyses of periodontally accelerated orthodontic and osteogenic techniques: a synthesis of scientific perspectives. *Semin Orthod* 14: 305–316, 2008
- Wilcko MT, Wilcko WM, Murphy KG, Carrol WJ, Ferguson DJ, Milley DD, et al: Full thickness flap/subepithelial connective tissue grafting with intramarrow penetrations: three case reports of lingual root coverage. *Int J Periodont Restor Dent* 2: 561–569, 2005
- Wilcko MT, Wilcko WM, Pulver JJ, Bissada NF, Bouquot JE: Accelerated osteogenic orthodontics technique: a 1-stage surgically facilitated rapid orthodontic technique with alveolar augmentation. *J Oral Maxillofac Surg* 67: 2149–2159, 2009
- Wilcko WM, Wilcko T, Bouquot JE, Ferguson DJ: Rapid orthodontics with alveolar reshaping: two cases reports of decrowding. *Int J Periodontics Rest Dent* 21: 9–19, 2011