

## Systematic Review Orthognathic Surgery

# Three-dimensional analysis of nasolabial soft tissue changes after Le Fort I osteotomy: a systematic review of the literature

**A. Paredes de Sousa Gil**<sup>1,2,3a</sup>,  
**R. Guijarro-Martínez**<sup>1,2,a</sup>,  
**O. L. Haas Jr.**<sup>1,2,3</sup>,  
**F. Hernández-Alfaro**<sup>1,2</sup>

<sup>1</sup>Institute of Maxillofacial Surgery, Teknon Medical Centre, Barcelona, Spain; <sup>2</sup>Department of Oral and Maxillofacial Surgery, Universitat Internacional de Catalunya, Sant Cugat del Vallès, Barcelona, Spain; <sup>3</sup>Department of Oral and Maxillofacial Surgery, Pontifícia Universidade Católica do Rio Grande do Sul (PUCRS), Porto Alegre, Rio Grande do Sul, Brazil

*A. Paredes de Sousa Gil, R. Guijarro-Martínez, O.L. Haas Jr., F. Hernández-Alfaro: Three-dimensional analysis of nasolabial soft tissue changes after Le Fort I osteotomy: a systematic review of the literature. Int. J. Oral Maxillofac. Surg. 2018; xxx: xxx–xxx. © 2019 International Association of Oral and Maxillofacial Surgeons. Published by Elsevier Ltd. All rights reserved.*

**Abstract.** A systematic review was conducted to investigate the three-dimensional (3D) effect of Le Fort I osteotomy on the nasolabial soft tissues. The literature search was conducted using the MEDLINE (accessed via PubMed), Embase, and Cochrane electronic databases until January 2018. A total of 333 studies were identified (PubMed,  $n = 292$ ; Embase,  $n = 41$ ; Cochrane Library,  $n = 0$ ). Seventeen met the inclusion criteria. The studies were essentially retrospective. The risk of bias was considered high in 15 studies, medium in one study, and low in one study. 3D soft tissue analysis was performed at least 6 months after surgery (mean 8.3 months). The main image acquisition technique reported was cone beam computed tomography (CBCT), associated or not with 3D photography. Approximately 50% of the studies performed two-jaw surgery, 25% performed maxillary surgery only, and the other 25% included heterogeneous intervention groups. The most reported nasolabial changes were anterior and lateral movements of the nasomaxillary soft tissues and upper lip, together with anterior and superior movement of the nasal tip. The alar cinch suture and V–Y closure technique seemed to have little effect in counteracting the undesirable postoperative nasolabial changes. CBCT superimposition presented a reliable 3D assessment for simultaneous measurement of skeletal and soft tissue changes.

**Key words:** three-dimensional analysis; Le Fort I osteotomy; soft tissue analysis; virtual planning.

Accepted for publication 31 January 2019

The treatment goals of orthognathic surgery have changed. With the growing importance of aesthetic outcomes from surgery, clinician's are now focusing on the adaptation of the soft tissues to the

skeletal movements<sup>1</sup>. Indeed, skeletal repositioning, particularly in Le Fort I osteotomy, can generate undesirable changes in the soft tissues around the nasolabial region, which include upturn-

<sup>a</sup> Ariane Paredes de Sousa Gil and Raquel Guijarro-Martínez contributed equally to this work.

ing of the nasal tip, widening of the alar base, flattening and thinning of the upper lip, down-turning of the commissures of the mouth, and loss of vermilion of the upper lip<sup>2</sup>. Common strategies aimed at preventing these unwanted effects include V–Y closure of the soft tissues and the alar cinch suture. Although the counteracting effect and stability of these techniques have been studied, their effectiveness remains controversial<sup>2–4</sup>.

A comprehensive treatment plan that seeks optimal functional and aesthetic results should be based on reliable prognostic methods<sup>5</sup>. The assessment of soft tissue changes after orthognathic surgery requires three-dimensional (3D) analysis due to the complexity of the soft tissue behaviour and because asymmetric areas cannot be measured accurately using two-dimensional (2D) Images<sup>6</sup>. Many protocols for 3D soft tissue analysis have been developed, including the methods of moiré stripes<sup>7</sup>, stereophotogrammetry<sup>8</sup>, 3D computed tomography<sup>9</sup>, and 3D laser scanning<sup>10,11</sup>. This 3D assessment involves obtaining a volume to be processed by dedicated software via algorithms that establish the soft tissue response to hard tissue changes<sup>12</sup>. Although research has indicated that the current software packages perform clinically satisfactory predictions, most also accept errors (sometimes significant) in soft tissue prediction<sup>5,12,13</sup>.

Numerous studies exist regarding 2D assessment of facial changes and soft tissue response ratios associated with Le Fort I osteotomy<sup>4,14–17</sup>. Conversely, few studies in which a comprehensive 3D evaluation of the hard and soft tissues has been performed have been published<sup>13</sup>. This systematic review was conducted to investigate the 3D effect of the Le Fort I osteotomy on the facial soft tissues. The three specific questions for which answers were sought were the following: (1) Are there validated protocols to three-dimensionally analyze soft tissue changes after orthognathic surgery? (2) Are the main facial changes after a Le Fort I osteotomy related to the direction of the maxillary movement? (3) Are the procedures aimed at counteracting the detrimental effects on soft tissue effective?

## Materials and methods

A comprehensive literature search was conducted using the MEDLINE (accessed via PubMed), Embase, and Cochrane electronic databases until January 2018. The PICO strategy was defined as follows: population (P): dentofacial deformity or orthognathic surgery; intervention (I): Le

Fort I osteotomy; comparison (C): direction of maxillary movement, V–Y closure and/or alar cinch suture; outcome (O): 3D soft tissue changes in the nasolabial area. No limits were applied for year of publication or language. Only full-length articles were included.

The reference lists of all selected articles were also hand-searched to identify additional potentially relevant studies.

## Search strategy

For the main search, the following strategy using medical subject headings (MeSH) was applied in MEDLINE/PubMed: (“Orthognathic Surgery” OR “Orthognathic Surgeries” OR “Orthognathic Surgery” OR “Surgeries, Orthognathic” OR “Orthognathic Surgery” OR “Surgery, Orthognathic” OR “Orthognathic Surgery” OR “Maxillofacial Orthognathic Surgery” OR “Orthognathic Surgery” OR “Maxillofacial Orthognathic Surgeries” OR “Orthognathic Surgery” OR “Orthognathic Surgeries, Maxillofacial” OR “Orthognathic Surgery” OR “Orthognathic Surgery, Maxillofacial” OR “Orthognathic Surgery” OR “Surgeries, Maxillofacial Orthognathic” OR “Orthognathic Surgery” OR “Surgery, Maxillofacial Orthognathic” OR “Orthognathic Surgery” OR “Jaw Surgery” OR “Orthognathic Surgery” OR “Jaw Surgeries” OR “Orthognathic Surgery” OR “Surgeries, Jaw” OR “Surgery, Jaw” AND “Osteotomy, Le Fort” OR “Le Fort Osteotomy” OR “Osteotomy, Le Fort” OR “Osteotomy, LeFort” OR “Osteotomy, Le Fort” OR “LeFort osteotomy” AND “Soft Tissue”).

This search strategy was adapted for the Cochrane database using the following MeSH terms: “orthognathic surgery” AND “Le fort osteotomy” AND “soft tissue”.

The Embase database was searched using the Emtree terms and their synonyms ‘orthognathic surgery’ and ‘Le Fort osteotomy’ for the following specific search query: ‘orthognathic surgery’/syn AND ‘Le Fort osteotomy’/syn AND ‘soft tissue’.

The reference lists of all articles retrieved through the main search were hand-searched for additional relevant papers.

## Study selection

The systematic literature search was conducted by one author (A.P.S.G.), and articles were selected for full-text reading

independently by two authors (A.P.S.G., O.L.H.J.) based on titles and abstracts. Inclusion criteria were: (1) studies performed on an adult, non-growing and non-syndromic population; (2) clinical trials and case series with 15 or more subjects; (3) single- or two-jaw surgery using rigid internal fixation; (4) studies referring to soft tissue changes in the paranasal area and lips after Le Fort I osteotomy; (5) studies performing 3D soft tissue analysis; (6) studies presenting objective data regarding the soft tissue response to skeletal movements; (7) studies with at least 6 months of follow-up.

Cohen’s kappa coefficient ( $\kappa$ ) was used to measure inter-rater agreement for title and abstract selection<sup>18</sup>. Articles for which the title and abstract were evaluated and were accepted in the first round of the selection process were screened for eligibility. The same two authors performed the eligibility assessment independently, applying the inclusion criteria separately. Disagreements were resolved by discussion with a more experienced author (R.G.M.). Publications that were not related to the topic or did not meet the required search strategy criteria were excluded, and the reason for exclusion was recorded.

## Data extraction

Standardized data extraction tables were created to organize the information from the selected studies. The same two authors (A.P.S.G and O.L.H.J.) independently extracted demographic data, methodological data, and outcomes for the nasolabial area. In the event of disagreement, the article was discussed with a third author (R.G.M.); if doubts persisted, the corresponding author of the study in question was contacted via e-mail.

## Three-dimensional soft tissue analysis

Soft tissues changes after Le Fort I osteotomy were assessed by comparing the 3D soft tissue data of the nasolabial area before surgery (T0) with those obtained after 6 months of postoperative follow-up (T1). The specific surgical movement of the maxilla in the sagittal, vertical, and transverse planes was taken into account. Data regarding additional procedures such as alar base cinch suture, V–Y soft tissue closure, and anterior nasal spine (ANS) removal or reshaping were also recorded.

## Quality assessment

Both investigators assessed the methodological quality of the included studies

independently. The quality of the papers was assessed using an adaptation of the bias analysis proposed by Haas Jr et al.<sup>19</sup>. The criteria used by these authors are related to sample randomization, comparison between intervention effects (control group), blinding of outcome assessors, validation of measurements, definition of inclusion and exclusion criteria, statistical analysis, and postoperative follow-up.

With respect to the risk of bias for each study analyzed, papers containing all the above-mentioned items were considered 'low risk', those for which one or two items were missing were deemed 'medium risk', and investigations that did not include three or more items were considered 'high risk'.

## Results

### Search strategy

The main search of the major databases was performed in January 2018. A total of 333 studies were identified (PubMed,  $n = 292$ ; Embase,  $n = 41$ ; Cochrane Library,  $n = 0$ ). After the exclusion of duplicates and those with non-relevant titles and abstracts, 141 studies were selected. Once eligible papers were identified, a manual search of their reference lists was performed. This search retrieved five additional articles<sup>20–24</sup>; however, none of them were included in this systematic review.

### Study selection

The titles and abstracts of the 141 articles retrieved were read independently by two authors (A.P.S.G. and O.L.H.J.). At the end of the eligibility assessment, 107 articles were selected for full-text reading. The level of agreement between the two authors in the eligibility assessment was measured at  $\kappa = 0.87$ .

### Study eligibility

Out of the 107 studies selected for full-text reading, 17 met the inclusion criteria and were included in this systematic review<sup>2–41</sup>. All of them were found in the main search. The remaining 90 studies (85 from the main search and five from the manual search) were excluded for the following reasons: the study was based on 2D facial analysis ( $n = 40$ )<sup>20,42–81</sup>, the study did not present objective data regarding the soft tissue response to hard tissue movement ( $n = 8$ )<sup>82–89</sup>, the study was a case report ( $n = 6$ )<sup>90–95</sup> or was a case series with  $n < 15$  ( $n = 15$ )<sup>21–24,96–110</sup>, the study was

performed on cleft patients ( $n = 5$ )<sup>111–115</sup>, the study was a model study ( $n = 4$ )<sup>116–119</sup>, the study was a review article ( $n = 4$ )<sup>120–123</sup>, osteotomies other than a Le Fort I were performed ( $n = 4$ )<sup>124–127</sup>, and soft tissue changes in the nasolabial area after Le Fort I osteotomy were not the main topic of the paper ( $n = 4$ )<sup>128–131</sup>. The level of inter-rater agreement was  $\kappa = 0.865$  (95% confidence interval 0.661–1). A flowchart of the search and selection process is given in Fig. 1.

### Demographic data

Data refer to Table 1. The studies were essentially retrospective (only two used a prospective design<sup>27,40</sup>) and had been published in the last 9 years (2008–2017). During this period, Lee et al. published two clinical trials reporting the effects of Le Fort I osteotomy and bimaxillary surgery in class III patients<sup>32,33</sup>. Likewise, Kim et al. published two clinical trials reporting facial changes after one-jaw and two-jaw surgery<sup>30,31</sup>.

A total of 576 patients underwent surgical correction of a midfacial deformity through Le Fort I osteotomy. Most patients were female (59.5%), and mean age ranged from 16.7 years<sup>34</sup> to 33.9 years<sup>36</sup>. The most commonly reported facial anomaly was class III skeletal deformity<sup>25–27,30–38,41</sup> ( $n = 356$ ), which was associated with facial asymmetry in some cases<sup>35</sup>. Two studies did not report the type of facial deformity<sup>28,29</sup>, and two did not stratify the patients into subgroups<sup>39,40</sup>.

### Imaging acquisition and method of facial analysis

Data refer to Table 2. All studies included in this systematic review performed a 3D analysis of the soft tissues at least 6 months after surgery (mean 8.3 months). The main image acquisition technique reported was cone beam computed tomography (CBCT)<sup>25,27,29,30–33,37–39</sup>, which was associated with 3D photography in two studies<sup>27,39</sup>. Several other image acquisition methods were reported, such as computed tomography (CT)<sup>35</sup>, lateral cephalogram associated with 3D optical scanning<sup>36</sup>, and 3D laser scanning<sup>26</sup>. Wermker et al.<sup>40</sup> reported the use of plaster dental models to assess dental and skeletal jaw movements and 3D optical scanning for facial analysis.

Three-dimensional soft tissue data collected at T0 and T1 were mostly compared and superimposed using voxel-based superimposition<sup>31–33,37–39</sup>, followed by

surface-based superimposition<sup>25–27,40,41</sup> and best-fit registration methods<sup>36</sup>. Soft tissue changes were quantified using 3D surface linear measurements in eight studies<sup>26,28,29,32,35,36,39,41</sup>, 3D distance mapping in four studies<sup>25,31,37,40</sup>, and 3D photogrammetry in two studies<sup>27,34</sup>. The use of a  $10 \times 27$  grid map was reported by Kim et al.<sup>30</sup>. Surgical planning and soft tissue analysis were performed with a great variety of software, the most commonly reported being OnDemand (Cybermed Co., Seoul, South Korea)<sup>25,32,33,38</sup>, 3D – Rapid Form 2006 (INUS Technology Inc., Seoul, South Korea)<sup>26,41</sup>, and In Vivo Dental Software 6.6, V-Ceph Software 5.5, and CMF Application Software<sup>31,37</sup>.

### Surgical outcome analysis

Data refer to Tables 3 and 4. Most orthognathic procedures were bimaxillary<sup>25,26,29–33,35,37–39,41</sup>, followed by isolated Le Fort I osteotomy<sup>27,28,34,36</sup>. Wermker et al.<sup>40</sup> reported groups containing patients who were submitted to surgically assisted rapid maxillary expansion (SARME) procedures. The most commonly reported maxillary movements were advancement<sup>27,28,34,36,40,41</sup> and impaction<sup>25,30,31,33,37,38</sup>, and a combination of these<sup>26,31,33</sup>. Only one study reported maxillary setback<sup>32</sup>. Alar base cinch procedures were performed in 242 patients<sup>27–29,32,33,35,37,38</sup>. Chen et al.<sup>27</sup> compared the soft tissue effect after conventional alar cinching and a modified alar cinch technique. V–Y closure was performed in 70 patients<sup>32,37,38</sup>; most of the studies included in the review did not report whether this was used or not<sup>25,26,28–31,33–36,40,41</sup>. van Loon et al.<sup>39</sup> removed or reshaped the ANS when necessary. None of the studies reported data regarding upper lip thickness.

### Maxillary advancement

Nasolabial changes related to maxillary advancement are illustrated in Fig. 2. The upper lip moved forward, and an increase in height and transverse prominence was observed<sup>26,31,33,36,41</sup>. Labrale superius correlated to upper incisor movement by 1%<sup>27</sup> to 98%<sup>33</sup>, and to the A-point by 23%<sup>40</sup> to 52%<sup>31</sup>. Nkenke et al.<sup>36</sup> found more pronounced changes in the malar and midfacial regions than in the upper lip. Anterior and lateral displacement of the nasomaxillary soft tissues was detected, together with anterior and superior repositioning of the nasal tip, which followed the anterior movement of A-point by 30%<sup>26</sup> to 96%<sup>27</sup>. Alar base widening

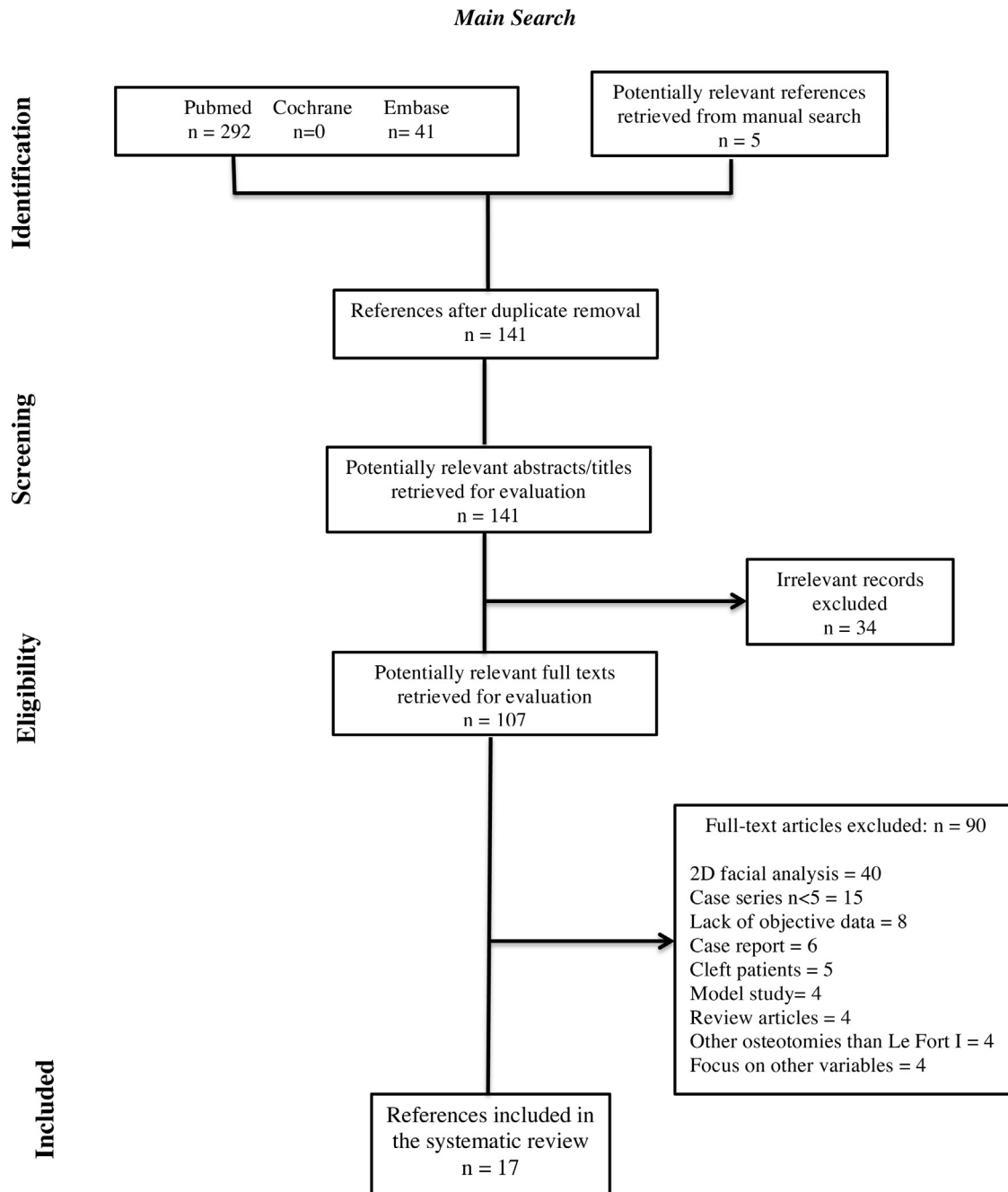


Fig. 1. Flowchart of the study selection procedure.

was a common finding, even when an alar cinch suture was used<sup>29,33,37,38</sup>.

#### Maxillary impaction

In the upper lip, a more convex profile and an increase in lip prominence was noted<sup>31,33,37</sup>. A forward movement was registered in the nasal tip and subnasal areas<sup>25,30,31,33,37,38</sup>. Alar base widening was also observed. Kim et al.<sup>30</sup> found that the nasolabial grooves moved anteriorly,

and that this change was more pronounced in the female group. Soft tissue around the Le Fort I osteotomy line followed maxillary movement by 57.8% in men and 80.8% in women<sup>30</sup>.

#### Maxillary setback

Changes in the nasolabial region related to maxillary setback are illustrated in Fig. 3. In the region of the upper lip, the midline seemed to move backwards<sup>32</sup>. The para-

nasal and subnasal areas seemed to move forward by 10% when alar base cinching was performed<sup>32</sup>. Increased soft tissue thickness at A-point was noted<sup>32</sup>.

#### Maxillary advancement with impaction

The upper lip was reported to move forward, as much as 98% when correlated to the upper incisor<sup>33</sup>, and its transverse prominence increased<sup>26</sup>. In addition, labrale superius (Ls) moved inferiorly<sup>26,33</sup>. In

Table 1. Demographic data.

Author, year Country of origin	Type of study	Sample <sup>a</sup>	Mean age (years)	Sex <sup>a</sup>	Type of facial deformity <sup>a</sup>
Nkenke et al., 2008 <sup>36</sup> Germany	CT	20	33.9	M = 10 F = 10	Class III = 20
Kim et al., 2010 <sup>30</sup> South Korea	CT	22	25.19	M = 12 F = 10	Class III = 22
Baik and Kim, 2010 <sup>26</sup> South Korea	CT	20	>18	NR	Class III = 20
Howley et al., 2011 <sup>28</sup> UK	RCT	28	NR	NR	NR
Park et al., 2012 <sup>38</sup> South Korea	CT	30	22.4	M = 15 F = 15	Class III = 30
Yuan et al., 2013 <sup>41</sup> China	CT	27	24	M = 11 F = 16	Class III = 27
Oh et al., 2013 <sup>37</sup> South Korea	CT	25	22.6	M = 11 F = 14	Class III = 25
Lee et al., 2013 <sup>32</sup> South Korea	CT	15	22.8	M = 6 F = 9	Class III = 15
Kim et al., 2013 <sup>31</sup> South Korea	CT	25	23.7	M = 16 F = 9	Class III = 25
Wermker et al., 2014 <sup>40</sup> Germany	P-CT	104	>18	M = 42 F = 62	NS
Moroi et al., 2014 <sup>35</sup> Japan	CT	40	27.65	M = 17 F = 23	Class III with and without asymmetry
Lee et al., 2014 <sup>33</sup> South Korea	CT	18	23.5	M = 9 F = 9	Class III = 18
Metzler et al., 2014 <sup>34</sup> USA	CT	44	16.7	NR	Class III = 44
van Loon et al., 2015 <sup>39</sup> Netherlands	CT	36	26.9	M = 12 F = 24	NS
Chen et al., 2015 <sup>27</sup> Taiwan	P-RCT	48	23.78	M = 15 F = 33	Class III = 48
Jeong et al., 2017 <sup>29</sup> South Korea	CT	52	21.9	M = 14 F = 38	NR
Seo et al., 2017 <sup>25</sup> South Korea	CT	22	21.6	M = 6 F = 16	Class III = 22

CT, clinical trial; F, female; M, male; NR, not reported; NS, not stratified in subgroups of patients; P-CT, prospective clinical trial; P-RCT, prospective randomized clinical trial; RCT, randomized clinical trial.

<sup>a</sup>Number of patients.

the paranasal area, the nasal tip, lateral walls, and alar base were reported to move forward<sup>26,31,33</sup>. An increase in transverse nasal prominence and alar base width was also noted<sup>26,31,33</sup>.

#### Quality assessment

The risk of bias was considered high in 15 studies, medium in one study, and low in one study. The main methodological criteria that were not met were sample randomization<sup>25,26,29-41</sup>, comparison between treatments<sup>25,26,29-41</sup>, and blind assessment<sup>25,26,29-33,35-41</sup> (Table 5). Chen et al.<sup>27</sup> were the only group who reported all required criteria successfully. Howley et al.<sup>28</sup> did not report the statistical analysis and this study was considered to carry a medium risk of bias. All studies included in this review reported a postoperative follow-up of at least 6 months.

#### Discussion

There are two main reasons to conduct a systematic review. First, the authors want to find an answer to their question, and second, the authors want to understand the risk of bias of the studies included to answer this question. Taking this into account, the present authors were able to answer the three questions posed, but the risk of bias was considered high in almost all of the 17 studies included in the sample. Only one study presented a low risk of bias<sup>27</sup> and one presented a medium risk of bias<sup>28</sup>, but this latter study failed to perform a statistical analysis. Sample randomization and blind assessment of the results appear to be the most important items required to limit the risk of bias of the research and present reliable conclusions. However, these items were missing in 15 studies<sup>25,26,29-41</sup> and in 14

studies<sup>25,26,29-33,35-41</sup>, respectively (Table 5). Even the clinical results found must be interpreted with caution because of limited quality; nevertheless, the authors are confident that the best evidence published on the issue is presented in this systematic review.

Beyond the poor methodological quality, another common mistake made in the analysis of facial soft tissues is the use of a combination of 2D and 3D parameters, as reported by Olate et al.<sup>13</sup>. This entails an enormous risk of bias, since a 2D lateral cephalogram may be unrelated to a 3D bone or soft tissue image. Three studies using this mixed methodology employed lateral cephalograms to assess skeletal movements and 3D image capture systems to assess soft tissue changes<sup>26,31,35</sup>. Olate et al. also suggested that it was necessary to establish research protocols to validate relationships, as well as to study the im-



Table 2. Imaging acquisition and method of facial analysis.

Author, year	Imaging method <sup>a</sup>	Imaging superimposition	Method of analysis	3D analysis <sup>b</sup>	Follow-up (months)
Nkenke et al., 2008 <sup>36</sup>	X-ray = 20 3D optical scan = 20	Best-fit registration	3D surface linear measurements	Dentofacial Planner SLIM <sup>3D</sup>	12
Kim et al., 2010 <sup>30</sup>	CBCT = 22	NR	3D cephalometry 10 × 27 grid map <sup>c</sup>	3D Dental Imaging Software	8.3
Baik and Kim, 2010 <sup>26</sup>	X-ray = 20 3D laser scan = 20	Surface-based registration	2D cephalometry 3D surface linear measurements	3D – Rapid Form 2006	6
Howley et al., 2011 <sup>28</sup>	3D optical scan = 28	NR	3D surface linear measurements	NR	6
Park et al., 2012 <sup>38</sup>	CBCT = 30	Voxel-based registration	3D cephalometry	OnDemand Software	12
Yuan et al., 2013 <sup>41</sup>	3D laser scan = 27	Surface-based registration	3D surface linear measurements	3D – Rapid Form 2006	>6
Oh et al., 2013 <sup>37</sup>	CBCT = 25	Voxel-based registration	3D cephalometry 3D distance mapping	InVivo Dental Software 6.6 V-Ceph Software 5.5 CMF Application Software	6
Lee et al., 2013 <sup>32</sup>	CBCT = 15	Voxel-based registration	3D cephalometry 3D surface linear measurements	OnDemand Software	6
Kim et al., 2013 <sup>31</sup>	CBCT = 25	Voxel-based registration	2D cephalometry 3D distance mapping	InVivo Dental Software 6.6 V-Ceph Software 5.5 CMF Application Software	6
Wermker et al., 2014 <sup>40</sup>	Plaster dental models = 104 3D optical scan = 104	Surface-based registration	3D distance mapping	KD-MMS	>6
Moroi et al., 2014 <sup>35</sup>	CT = 40	NR	2D cephalometry 3D surface linear measurements	Aquarius Net Software Image Software CephaloMetrics AtoZ Software	12
Lee et al., 2014 <sup>33</sup>	CBCT = 18	Voxel-based registration	3D cephalometry	OnDemand Software	6
Metzler et al., 2014 <sup>34</sup>	3D photo = 44	NR	3D photogrammetry	3D Vectra Photosystem	7.8
van Loon et al., 2015 <sup>39</sup>	CBCT = 36 3D photo = 36	Voxel-based registration	3D surface linear measurements	3D Maxilim	12
Chen et al., 2015 <sup>27</sup>	CBCT = 48 3D photo = 48	Surface-based registration	3D cephalometry 3D photogrammetry	Vultus Software	6
Jeong et al., 2017 <sup>29</sup>	CBCT = 52	NR	3D surface linear measurements	Mimics 16.0 Simplant 14.0	12
Seo et al., 2017 <sup>25</sup>	CBCT = 22	Surface-based registration	3D distance mapping	OnDemand Software Geomagic Control 2014.0	12

2D, two-dimensional; 3D, three-dimensional; CT, computed tomography; CBCT, cone beam computed tomography; NR, not reported.

<sup>a</sup> Number of patients.

<sup>b</sup> Software used to perform the soft tissue three-dimensional analysis: Dentofacial Planner System (Gemetek Com, Erding, Germany); SLIM<sup>3D</sup> (3D-shape GmbH, Erlangen, Germany); 3D Dental Imaging Software (Ez3D2009; E-WOO Technology Co., Seoul, Korea); 3D – Rapid Form 2006 (INUS Technology Inc., Seoul, Korea); OnDemand (Cybermed Co., Seoul, South Korea); InVivo Dental Software (Anatomege, San Jose, CA, USA); V-Ceph Software (Osstem, Seoul, South Korea); CMF Application Software (ME Müller Institute for Surgical Technology and Biomechanics, University of Bern, Bern, Switzerland – Co-Me Network); KD-MMS (The University of Münster Model Surgery System for Orthognathic Surgery); Aquarius Net (TeraRecon, Foster City, CA, USA); ImageJ (Research Services Branch, National Institute of Mental Health, Bethesda, MD, USA); CephaloMetrics AtoZ Software (Yasunaga Computer Systems Inc., Fukui, Japan); 3D Vectra Photosystem (Canfield Imaging Systems, Fairfield, NJ, USA); 3D Maxilim (Medicin NV, Mechelen, Belgium); Vultus Software (3dMD, Atlanta, GA, USA); Mimics 16.0 (Materialise Dental NV, Leuven, Belgium); Simplant 14.0 (Materialise Dental NV, Leuven, Belgium); Geomagic Control (Geomagic, Morrisville, NY, USA).

<sup>c</sup> 10 × 27 grids at 4.5 mm (vertical) and 5 mm (horizontal) intervals.

Table 3. Qualitative data regarding labial and paranasal changes.

Author, year	Intervention <sup>a</sup>	Type of movement <sup>a</sup>	V-Y closure <sup>b</sup>	Alar cinch <sup>c</sup>	Removal of ANS <sup>d</sup>	Upper lip thickness	Labial changes	Paranasal changes
Nkenke et al., 2008 <sup>36</sup>	LFO = 20	MA = 20	NR	NR	NR	NR	Upper lip moved forward 80% of the incisor superior movement; in horizontal plane, it exceeded 95%	The effect of MA was more pronounced in the malar and midfacial area than in the upper lip
Kim et al., 2010 <sup>30</sup>	LFO + BSSO = 22	MI = 22	NR	NR	NR	NR	In both male and female patients, MI increased upper lip prominence; it was more clinically distinguishable in the female group	In both male and female patients, MI increased nasolabial groove prominence; it was more clinically distinguishable in the female group
Baik and Kim, 2010 <sup>26</sup>	LFO + BSSO = 10 LFO + BSSO + GE = 10	MAPI + Mand setback = 20	NR	NR	NR	NR	Ls moved inferiorly, although hard tissues moved superiorly; transverse lip prominence increased	Changes in paranasal area were 74% of the hard tissue movement; nasal width increased by 2 mm; transverse nasal prominence increased
Howley et al., 2011 <sup>28</sup>	LFO = 28	MA = NR MAI = NR	NR	14	NR	NR	NR	The alar cinch group showed slightly less widening of the alar base at 6 months, but it was not statistically significant
Park et al., 2012 <sup>38</sup>	LFO + BSSO = 30	MAI = 30 Mand setback = 30	30	30	NR	NR	NR	Nasal tip rotated anterior-superiorly; nasal supratip became more prominent; the nose protrusion was diminished; nasal base and nostril area were extended
Yuan et al., 2013 <sup>41</sup>	LFO + BSSO = 12 BSSO = 15	MA = 12 Mand setback = 27	NR	NR	NR	NR	Anterior movement of the upper lip	Anterior and lateral movements of nasomaxillary soft tissue; the midface width increased more in the bimaxillary surgery group
Oh et al., 2013 <sup>37</sup>	LFO + BSSO = 25	MPI + Mand setback = 25	25	25	NR	NR	Upper lip changes were positively related to SNA; more convex profile of upper lip after bimaxillary surgery	Alar base widening; Pn and Sn moved forward
Lee et al., 2013 <sup>32</sup>	LFO + BSSO = 15	MS + Mand setback = 15	15	15	NR	NR	Midline at upper lip area moved backwards	Paranasal and subalar areas moved forward; increase of the soft tissue thickness at A-point; no significant changes at Sn
Kim et al., 2013 <sup>31</sup>	LFO + BSSO = 17 BSSO = 8	MAPI = 17 Mand setback = 8	NR	NR	NR	NR	Upper and lower lips moved backwards after BSSO; upper lip moved about 1.5 mm forward with bimaxillary surgery	Sn moved back about 0.3 mm with BSSO; anterior and superior movement of the tip of the nose, anterior movement of paranasal area and widening of the alar base were noted after bimaxillary surgery
Wermker et al., 2014 <sup>40</sup>	LFO = 53 BSSO = 89 SARME = 10	MA = 51 Mand Adv = 58 Mand setback = 31	NR	NR	NR	NR	Soft tissues changes of the upper lip and Sn area only slightly followed the dental and skeletal movement of maxilla between 3% and 34% without statistical correlations	Soft tissues changes of the upper lip and Sn area only slightly followed the dental and skeletal movement of maxilla between 3% and 34% without statistical correlations

Table 3 (Continued)

Author, year	Intervention <sup>a</sup>	Type of movement <sup>a</sup>	V-Y closure <sup>b</sup>	Alar cinch <sup>c</sup>	Removal of ANS <sup>d</sup>	Upper lip thickness	Labial changes	Paranasal changes
Moroi et al., 2014 <sup>35</sup>	LFO + BSSO = 39	NS	NR	Yes = 40	NR	NR	No significant differences were found between symmetric and asymmetric patients <sup>e</sup>	Increasing in alar width was more pronounced in the asymmetry group <sup>e</sup>
Lee et al., 2014 <sup>33</sup>	LFO + IVRO = 1 + IVRO = 18	MAPI = 18	NR	Yes = 18	NR	NR	The vertical height of the upper lip increased and the upper lip became better supported by the upper incisor; upper lip prominence increased	Nasolabial angle increased; Sn, Pn, and both alae moved anteriorly
Metzler et al., 2014 <sup>34</sup>	LFO = 44	MA = 44	NR	NR	NR	NR	Upper lip advanced 50% of the amount of the maxilla advancement; upper lip widening was recorded	Average projection of nasal tip was 10% of maxilla advancement; intrinsic nasal tip projection decreased; mean transverse widening of alae and alar base of 50% of maxilla advancement; nostril width increased, vertical dimension decreased, and lateral nostril display increased
van Loon et al., 2015 <sup>39</sup>	LFO = 12 LFO + BSSO = 24	NS	No	No	When necessary	NR	Anterior translation and pitching of the maxilla influenced lip volume	Cranial translation of the maxilla led to an alar width increase
Chen et al., 2015 <sup>27</sup>	LFO = 48	MA = 48	No	M = 24 <sup>f</sup> C = 24 <sup>f</sup>	No	NR	In group M, the upper lip cutaneous height increased, the lower labial width decreased, and the upper lip protrusion decreased	In group C, Sn moved downwards and backwards and columella length increased; in group M, Sn moved upwards and forwards and the nasolabial angle increased
Jeong et al., 2017 <sup>29</sup>	LFO + BSSO = 52	Maxilla = NR Mand Adv = 4 Mand setback = 48	NR	52	NR	NR	NR	Alar base width widening occurred in all patients regardless of the vector of surgical maxillary movement; shortening of the nose was found
Seo et al., 2017 <sup>25</sup>	LFO + IVRO = 22 GE = 22	MPI = 22 Mand setback = 22	NR	NR	NR	NR	NR	Alar base widening; Pn and Sn moved forwards; paranasal and cheek area moved forwards and this was correlated to vertical movement of B-point

Adv, advancement; ANS, anterior nasal spine; BSSO, bilateral sagittal split osteotomy; GE, genioplasty; IVRO, intraoral vertical ramus osteotomy; LFO, conventional Le Fort I osteotomy; Ls, labrale superius; MA, maxillary advancement; MAI, maxillary advancement with impaction; Mand, mandible; MAPI, maxillary advancement with posterior impaction; MI, maxillary impaction; MPI, maxillary posterior impaction; MS, maxillary setback; NR, not reported; NS, not stratified in subgroups of patients; Pn, pronasale; SARME, surgically assisted rapid maxillary expansion; Sn, subnasale; SNA, sella-nasion-A-point angle.

<sup>a</sup> Number of patients.

<sup>b</sup> Patients who received V-Y closure.

<sup>c</sup> Patients who received alar cinch suture.

<sup>d</sup> Patients who had the ANS removed.

<sup>e</sup> Different impactions for left and right sides.

<sup>f</sup> M, modified alar cinch suture (attachment of nasal muscles and dermis of alar base, passing the suture through a hole in ANS); C, conventional alar cinch suture (attachment of nasal muscles, passing the suture through a hole in ANS).



Table 4. Quantitative data regarding hard-to-soft tissue ratio and alar base widening.

Author, year	V-Y closure <sup>a</sup>	Alar cinch <sup>b</sup>	Removal of ANS <sup>c</sup>	Hard-to-soft tissue ratios	Alar base widening (transverse plane) (mm)
Nkenke et al., 2008 <sup>36</sup>	NR	NR	NR	Ls/Is 80 ± 94%; Preg R/Is: 97 ± 79%; Preg L/Is: 98 ± 89% (sagittal plane)	NR
Kim et al., 2010 <sup>30</sup>	NR	NR	NR	Osteotomy line ratio: 57.8% men and 80.8% women (sagittal plane)	NR
Baik and Kim, 2010 <sup>26</sup>	NR	NR	NR	Pn/A: 30% to 31%; Sn/A: 54% to 57%; subalar/A: 59% to 68%; Ls/A: 33% to 34%; Par/A: 67% to 74% (sagittal plane)	NR
Howley et al., 2011 <sup>28</sup>	NR	14	NR	NR	Cinch group: 2.2 mm (1 month) and 1.9 mm (6 months) Control group: 2.6 mm (1 month) and 2.7 mm (6 months)
Park et al., 2012 <sup>38</sup>	30	30	NR	Pn/A: 39%; nasal height: 87%; Sn/A: 110%; columella length: 35% (sagittal plane; 3.41 mm posterior impaction)	2.45 ± 1.52 mm
Yuan et al., 2013 <sup>41</sup>	NR	NR	NR	NR	4.56 mm (male); 3.97 mm (female)
Oh et al., 2013 <sup>37</sup>	25	25	NR	Philtrum/A: 61% to 69%; cheilion/A: 41% to 50%; Sn/A: 36% (sagittal plane)	2.9 mm to 3.3 mm
Lee et al., 2013 <sup>32</sup>	15	15	NR	Sn/A: 10%; Ls/A: 162%; cheilion/A: 45% to 72% (sagittal plane)	2.97 ± 1.49 mm to 3.8 ± 5 mm
Kim et al., 2013 <sup>31</sup>	NR	NR	NR	Ls/A: 45% to 52%; cheilion/A: 41%; Pn/A: 49%; Sn/A: 23% (sagittal plane)	1.69 mm to 2.54 mm
Wermker et al., 2014 <sup>40</sup>	NR	NR	NR	Sn/A: 2% to 58%; Ls/A: 23% to 35% (sagittal plane)	NR
Moroi et al., 2014 <sup>35</sup>	NR	Yes = 40	NR	NR	Alar base width: 1.34 mm; alar width: 1.82 mm (symmetric group) Alar base width: 1.14 mm; alar width: 2.34 mm (non-symmetric group)
Lee et al., 2014 <sup>33</sup>	NR	Yes = 18	NR	Pn/A: 65%; Sn/A: 96%; Ls/U1: 98%; ala: 2.57 ± 1.17 mm to 3.18 ± 1.14 mm (symmetric group) Pn/A: 39%; Sn/A: 55%; Ls/U1: 81%; ala: 2.56 ± 1.16 mm to 2.61 ± 0.98 mm (non-symmetric group)	2.57 ± 1.17 mm to 3.18 ± 1.14 mm (symmetric group) 2.56 ± 1.16 mm to 2.61 ± 0.98 mm (non-symmetric group)
Metzler et al., 2014 <sup>34</sup>	NR	NR	NR	Pn/A: 10.2%; columella/A: 16.1%; Sn/A: 28.8%; Ls/A: 51.2% (sagittal plane) Pn/A: -31.8%; columella/A: -9.9%; philtrum/A: 6.6% (vertical plane) Alar base width: 54%; alar width: 54.5%; columella width: -2.9%; philtrum width: 18.7% to 19.6% (transverse plane)	NR
van Loon et al., 2015 <sup>39</sup>	No	No	When necessary	NR	1.76 ± 1.02 mm

Table 4 (Continued)

Author, year	V-Y closure <sup>a</sup>	Alar cinch <sup>b</sup>	Removal of ANS <sup>c</sup>	Hard-to-soft tissue ratios	Alar base widening (transverse plane) (mm)
Chen et al., 2015 <sup>27</sup>	No	M = 24 <sup>d</sup> C = 24 <sup>d</sup>	No	M: Pn/ANS: 4%; Sn/A: 65%; Ls/UI: 94% (sagittal plane) M: Pn/ANS: 12%; Sn/A: 65%; Ls/UI: 94% (vertical plane) M: Pn/ANS: 63%; Sn/A: 22%; Ls/UI: 0 (transverse plane) C: Pn/ANS: 96%; Sn/A: 97%; Ls/UI: 1% (sagittal plane) C: Pn/ANS: 30%; Sn/A: 13%; Ls/UI: 193% (vertical plane) C: Pn/ANS: 36%; Sn/A: 54%; Ls/UI: 86% (transverse plane) Pn/A: 83% (sagittal plane) Pn/A: 42% (transverse plane) Par/ANS: 150%; Par/UI: 70%; anterior cheek/ANS: 16%; anterior cheek/UI: 25% (sagittal plane) Par/B: 69% (sagittal plane)	M = 0.62 ± 2.08 mm C = 0.26 ± 1.85 mm
Jeong et al., 2017 <sup>29</sup>	NR	52	NR		-1.67 ± 2.41 mm
Seo et al., 2017 <sup>25</sup>	NR	NR	NR		Alar width: 0.87 ± 1.38 mm

A, A-point; ANS, anterior nasal spine; B, B-point; Is/UI, incision superior; Ls, labrale superius; NR, not reported; Par, parasagittal region; Pn, pronasale; Preg, parasagittal region (L, left; R, right); Sn, subnasale.

<sup>a</sup> Patients who received V-Y closure.

<sup>b</sup> Patients who received alar cinch suture.

<sup>c</sup> Patients who had the ANS removed.

<sup>d</sup> M, modified alar cinch suture (attachment of nasal muscles and dermis of alar base, passing the suture through a hole in ANS); C, conventional alar cinch suture (attachment of nasal muscles, passing the suture through a hole in ANS)

pect of certain software in virtual orthognathic surgery planning<sup>13</sup>.

Several imaging-based software programs for the evaluation of facial soft tissue after orthognathic surgery were applied in the studies retrieved in this systematic review (Table 2). The accuracy of computerized 3D soft tissue simulation relies on the ability of computing algorithms to predict soft tissue movements. The most frequently used are the mass spring model, finite element model (FEM), and mass tensor model (MTM)<sup>24,128</sup>. These all require a database that enables soft tissue mobilization when performing virtual orthognathic surgery<sup>13</sup>. The main 3D soft tissue databases identified in this review were acquired by CT<sup>35</sup>, CBCT<sup>25,27,29,30-33,37-39</sup>, 3D laser<sup>26,41</sup> and optical scanning<sup>28,36,40</sup>, and 3D photogrammetry<sup>27,34</sup>. Kim et al.<sup>31</sup> pointed out that 3D laser and optical scanners and stereophotogrammetry-based imaging systems tend to avoid ionizing radiation and provide more accurate soft tissue colour and texture. On the other hand, Lee et al.<sup>33</sup> claim that these techniques have important disadvantages, such as the inability to visualize hard and soft tissues simultaneously, frequent use of mixed 2D and 3D methods, need for additional processing in order to merge surface scan data and 3D CT data, and the inability to register images over time because of different head positions and sizes. CBCT provides a concurrent and accurate representation of both the hard and soft tissues with low radiation and greater dimensional accuracy<sup>31</sup>.

The approach to facial outcomes after a Le Fort I osteotomy requires a comprehensive comparison between the preoperative and postoperative conditions of both the hard and soft tissues. Usually, linear and angular measurements are used to assess these outcomes; however, the determination of postoperative changes in the facial contours and soft tissue volume is important for achieving a more complete evaluation of the facial shape. Several methods of 3D image superimposition have been proposed to quantify facial changes after orthognathic surgery<sup>23-41</sup>. Among these, best-fit registration, surface-based registration, and voxel-based registration were the most cited methods in the studies retrieved for this systematic review. In best-fit and surface-based registration, images acquired by laser or optical scans are matched using the regions of the facial surface that have not been altered by surgery<sup>36</sup>. By selecting sets of corresponding points, an optimization algorithm minimizes the remaining devia-

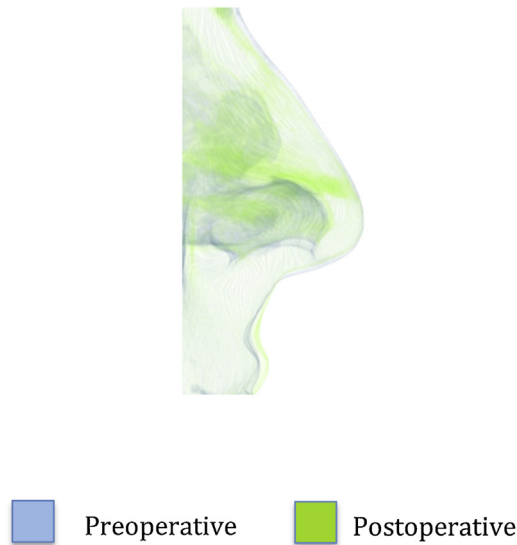


Fig. 2. Nasolabial profile changes following maxillary advancement: before surgery and after surgery.

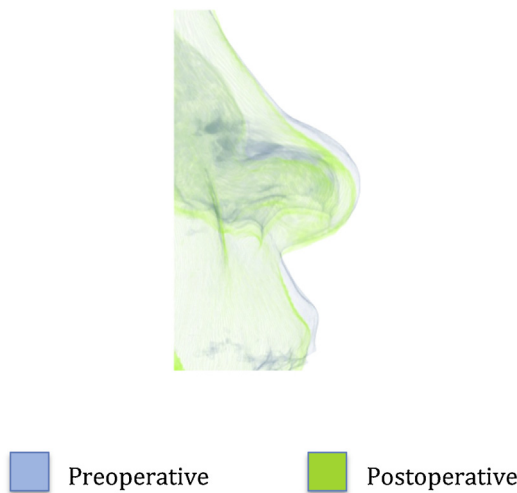


Fig. 3. Nasolabial profile changes following maxillary setback: before surgery and after surgery.

tions automatically. In their validation protocol, Nkenke et al.<sup>132</sup> reported measurement errors of only 3%. The 3D models constructed from CBCT scans can be superimposed manually by registering common stable landmarks or best fit of stable anatomical regions<sup>6</sup>. The other option available is voxel-based registration, an automated registration technique whereby CBCT scans are superimposed by comparing the grey values in a defined volume of interest in two scans to compute the rotation and translation required to align the two datasets<sup>6</sup>. One study reported the association of best-fit registration and 3D scanning for outcome assessment<sup>36</sup>. Baik and Kim<sup>26</sup> and Wermker et al.<sup>40</sup> demonstrated significant errors using su-

perimposition of the T0 and T1 images based on facial landmarks. Voxel-based superimposition based on skeletal and facial CBCT images was used in six studies that evaluated nasolabial soft tissue changes directly related to maxillary skeletal movements<sup>31–33,37–39</sup>. Data provided by CBCT imaging enables a standardized analysis of the relationships between the soft tissues and the underlying skeletal and dental structures by permitting the use of stable references for the superimposition process<sup>6</sup>. Therefore, voxel-based superimposition based on stable skeletal references is a validated protocol<sup>133</sup> and seems to be a reliable method to assess treatment outcomes related to orthognathic surgery<sup>6,129,130</sup>.

Other related factors can influence the analysis of facial soft tissue changes and their relationships with skeletal movements. These include postoperative oedema<sup>37</sup>, weight loss or gain<sup>131</sup>, postoperative orthodontic changes, removal of devices, and upper lip thickness<sup>85</sup>. With regard to postoperative oedema, the timing of postoperative soft tissue analysis is critical because of swelling and soft tissue remodelling and relocation<sup>32,33,89</sup>. Some study groups recommend waiting as long as 6 months to 1 year after surgery<sup>17,24</sup>. Although some authors have reported stable results at 3 months and up to 6 months after surgery<sup>128</sup>, Park et al.<sup>38</sup> and Oh et al.<sup>37</sup> noted considerable soft tissue changes between 2 months and 6 months after surgery. Taking this into account, this review included studies with at least 6 months of follow-up. None of the studies included in this systematic review provided information about lip thickness.

The Le Fort I osteotomy allows maxillary repositioning in all three planes of space. The soft tissue response to these movements may vary according to the amount of skeletal movement, complexity of the procedure<sup>85</sup>, soft tissue thickness, and technique of soft tissue closure<sup>118</sup>. Stella et al.<sup>67</sup> investigated the correlation between the amount of maxillary advancement and postoperative bony-to-soft tissue changes, classifying their sample according to the degree of advancement (more than 5 mm vs. less than 5 mm). These authors found that the correlation decreases as the amount of movement increases. Moreover, for a given amount of advancement it was not possible to predict the soft tissue response.

Approximately 50% of the studies in this review performed two-jaw surgery<sup>25,26,29,30,32,33,35,37,38</sup>, 25% performed maxillary surgery only<sup>27,28,34,36</sup>, and the other 25% had heterogeneous intervention groups<sup>31,39–41</sup>. Table 4 summarizes the hard-to-soft tissue ratios extracted from the included studies. In fact, care was taken to select only those studies that presented quantitative data regarding the facial changes after maxillary movement. Although not included in this systematic review, the study performed by Verdenik and Ihan Hren<sup>88</sup> found that isolated Le Fort I osteotomy produced an average volumetric change of 2 mm in the nasolabial area, whereas bimaxillary surgery produced an average 1.8 mm change. When only the mandible was submitted to surgery, a mean change of 1 mm was noted. No statistically significant results regarding the differences between two-jaw and one-jaw surgery and their effects

Table 5. Risk of bias assessment.

Author, year	Sample randomization	Comparison between treatments <sup>a</sup>	Blind assessments	Validation of measurements <sup>b</sup>	Defined inclusion/exclusion criteria	Statistical analysis	Report of follow-up <sup>c</sup>	Risk of bias assessment <sup>d</sup>
Nkenke et al., 2008 <sup>36</sup>	No	No	No	Yes	Yes	Yes	Yes	High
Kim et al., 2010 <sup>30</sup>	No	No	No	Yes	Yes	Yes	Yes	High
Baik and Kim, 2010 <sup>26</sup>	No	No	No	Yes	Yes	Yes	Yes	High
Howley et al., 2011 <sup>28</sup>	Yes	Yes	Yes	Yes	Yes	No	Yes	Medium
Park et al., 2012 <sup>38</sup>	No	No	No	Yes	Yes	Yes	Yes	High
Yuan et al., 2013 <sup>41</sup>	No	No	No	Yes	Yes	Yes	Yes	High
Oh et al., 2013 <sup>37</sup>	No	No	No	Yes	Yes	Yes	Yes	High
Lee et al., 2013 <sup>32</sup>	No	No	No	Yes	Yes	Yes	Yes	High
Kim et al., 2013 <sup>31</sup>	No	No	No	Yes	Yes	Yes	Yes	High
Wermker et al., 2014 <sup>40</sup>	No	No	No	Yes	Yes	Yes	Yes	High
Moroi et al., 2014 <sup>35</sup>	No	No	No	Yes	Yes	Yes	Yes	High
Lee et al., 2014 <sup>33</sup>	No	No	No	Yes	Yes	Yes	Yes	High
Metzler et al., 2014 <sup>34</sup>	No	No	Yes	No	Yes	Yes	Yes	High
van Loon et al., 2015 <sup>39</sup>	No	No	No	Yes	Yes	Yes	Yes	High
Chen et al., 2015 <sup>27</sup>	Yes	Yes	Yes	Yes	Yes	Yes	Yes	Low
Jeong et al., 2017 <sup>29</sup>	No	No	No	No	Yes	Yes	Yes	High
Seo et al., 2017 <sup>25</sup>	No	No	No	Yes	Yes	Yes	Yes	High

<sup>a</sup> Comparison between 'gold standard' treatment (control group) and the treatment being tested (experimental group), in this case, patients receiving or not alar cinch suture, V-Y closure, and ANS removal.

<sup>b</sup> Validated protocol for 2D or 3D facial analysis.

<sup>c</sup> At least 6 months.

<sup>d</sup> Risk of bias assessment: high = 0-4 'yes'; medium = 5-6 'yes'; low = 7 'yes'.

on the nasolabial area were found by this study. However, Kim et al.<sup>31</sup> found that isolated mandibular setback surgery moved both the upper and lower lips backwards, as well as the subnasal area. They also concluded that the overall soft tissue changes in the midfacial area were more evident in the two-jaw surgery group than in the one-jaw surgery group, but the correlated patterns were more evident in the lower third of the face<sup>31</sup>.

In the context of maxillary advancement, the most commonly reported labial changes were a forward movement of the upper lip<sup>29-31,33,34,36,40,41</sup>, together with an increase in transverse width<sup>26,34</sup> and height<sup>27</sup>. Sagittally, the upper lip followed the forward movement of the upper incisor by up to 94%<sup>27,36</sup> when conventional or modified alar cinch sutures were performed. Metzler et al.<sup>34</sup> and Wermker et al.<sup>40</sup> reported lower ratios when comparing upper lip to ANS advancement; correlation values ranged from 23% to 58%. Upper lip width seemed to increase by 18.7% to 19.6%<sup>34</sup>. Likewise, anterior and lateral movements of the nasomaxillary soft tissues<sup>26,31</sup>, together with anterior and superior movement of the nasal tip<sup>27,31,33,34,37,38</sup> were the most commonly reported nasal changes. According to Nkenke et al.<sup>36</sup>, the nasal tip can follow the forward movement of the upper incisor by as much as 98%, while Chen et al.<sup>27</sup> reported a forward movement of nasal tip of 96% of the ANS sagittal movement. Metzler et al.<sup>34</sup> found 54% of alar base widening and 54.4% of alar widening in maxillary advancement. Only one study reported changes related to maxillary backward movement<sup>32</sup>, which seemed to cause a backward movement of the upper lip and about 10% forward movement of the paranasal and subnasal areas. The forward movement of these regions, even when maxilla was moved backwards, was attributed to the use of V-Y closure and alar cinch suture techniques in all of these patients<sup>32</sup>.

Following maxillary impaction, a more convex profile of the upper lip was noted, together with an increase in lip prominence ranging from 61% to 69% when V-Y closure and alar cinch sutures were performed<sup>37</sup>. The nasal tip and subnasal area moved forward<sup>25,31,33,37,38</sup>. Alar base widening was also found<sup>25,26,28,31,37,38</sup>. Kim et al.<sup>30</sup> found 57.8% and 80.8% of soft tissue forward movement at the osteotomy line in men and women, respectively. The combination of superior and anterior repositioning of the maxilla accounted for 16% of the orthognathic procedures included in this re-



view<sup>26,21,27,28</sup>. Liebrechts et al.<sup>85</sup> suggested that the complexity of the surgical intervention might influence the soft tissue prediction. Baik and Kim<sup>26</sup> noted a slight upper lip length increase when maxillary advancement was associated with impaction. The paranasal area seemed to suffer lateral expansion and forward movement, the latter ranging from 67% to 74%<sup>26</sup>. No information about maxillary inferior repositioning was retrieved.

The use of a V–Y closure and some type of alar cinching technique are common strategies to control undesirable nasolabial changes after a Le Fort I osteotomy procedure. The aim of the V–Y closure is to counteract the tendency for upper lip shortening and to allow some eversion of the vermilion border<sup>118</sup>. The alar cinch suture is primarily used to stabilize alar width after surgery. Therefore, it is not expected to influence the soft tissue profile of the upper lip significantly, regardless of whether V–Y closure is used or not<sup>14</sup>. Although alar base widening was a common finding even when alar base cinching was performed<sup>29,33,37,38</sup>, Howley et al.<sup>28</sup> noted that the alar cinch group showed slightly less widening of the alar base at 6 months. Although statistical significance was not reached, values for the cinch group and the control group were 1.9 mm and 2.7 mm, respectively. In a multi-part systematic review, Moragas et al.<sup>118</sup> reported that the upper lip tends to follow the skeletal movement more closely if both an alar cinch suture and V–Y closure are performed. Similarly, the amount of vermilion exposure can be influenced by V–Y closure. Lee et al.<sup>32</sup> found that the upper lip followed the anterior movement of ANS by up to 162% when alar cinch and V–Y closure were performed. Similarly, Oh et al.<sup>37</sup> found that upper lip vermilion exposure increased up to 45% when both alar cinch and V–Y closure were performed. Nasal tip movement does not seem to vary depending on whether a V–Y closure or alar cinch suture are performed. However, Park et al.<sup>38</sup> found that the nasal tip followed 39% of ANS anterior movement and that nasal height increased 87% when both alar cinch and V–Y closure were performed.

A better understanding of the relationship between skeletal movement and the response of the overlying soft tissue is essential to improve the predictability of aesthetic soft tissue results after maxillary surgery. The number of validated protocols for facial soft tissue analysis in the context of orthognathic surgery is still limited. More prospective studies with a

higher level of evidence are required. Among the 3D methodologies evaluated in this systematic review, CBCT superimposition enables 3D assessment of nasal and labial morphological changes, and could therefore be an effective tool for the simultaneous measurement of skeletal and soft tissue changes.

#### Funding

None.

#### Competing interests

None.

#### Ethical approval

Not required.

#### Patient consent

Not required.

#### References

- Ackerman JL, Proffit WR, Sarver DM. The emerging soft tissue paradigm in orthodontic diagnosis and treatment planning. *Clin Orthod Res* 1999;**2**:49–52.
- Shams MG, Motamedi MHK. A more effective alar cinch technique. *J Oral Maxillofac Surg* 2002;**60**:712–5.
- Stewart A, Edler RJ. Efficacy and stability of the alar base cinch suture. *Br J Oral Maxillofac Surg* 2011;**49**:623–6.
- Shoji T, Muto T, Takahashi M, Akizuki K, Tsuchida Y. The stability of an alar cinch suture after Le Fort I and mandibular osteotomies in Japanese patients with class III malocclusions. *Br J Oral Maxillofac Surg* 2012;**50**:361–4.
- Aboul-Hosn Centenero S, Hernandez-Alfaro F. 3D planning in orthognathic surgery: CAD/CAM surgical splints and prediction of the soft and hard tissues results: our experience in 16 cases. *J Craniomaxillofac Surg* 2012;**40**:162–8.
- Cevidanes LH, Motta A, Proffit WR, Ackerman JL, Styner M. Cranial base superimposition for 3-dimensional evaluation of soft-tissue changes. *Am J Orthod Dentofacial Orthop* 2010;**137**:S120–9.
- Kawai T, Natsume N, Shibata H, Yamamoto T. Three-dimensional analysis of facial morphology using moiré stripes. Part I. Method. *Int J Oral Maxillofac Surg* 1990;**19**:356–8.
- Ayoub A, Garrahy A, Hood C, White J, Bock M, Siebert JP, Spencer R, Ray A. Validation of a vision-based, three-dimensional facial imaging system. *Cleft Palate Craniofac J* 2003;**40**:523–9.
- Kim NK, Lee C, Kang SH, Park JW, Kim MJ, Chang YI. A three-dimensional analysis of soft and hard tissue changes after a mandibular setback surgery. *Comput Methods Programs Biomed* 2006;**83**:178–87.
- Soncul M, Bamber MA. Evaluation of facial soft tissue changes with optical surface scan after surgical correction of class III deformities. *J Oral Maxillofac Surg* 2004;**62**:1331–40.
- Day CJ, Lee RT. Three-dimensional assessment of the facial soft tissue changes that occurs postoperatively in orthognathic patients. *World J Orthod* 2006;**7**:15–26.
- Shafi MI, Ayoub A, Ju X, Khambay B. The accuracy of three-dimensional prediction planning for the surgical correction of facial deformities using Maxilim. *Int J Oral Maxillofac Surg* 2013;**42**:801–6.
- Olate S, Zaror C, Mommaerts MY. A systematic review of soft to hard tissue ratios in orthognathic surgery. Part IV: 3D analysis—is there evidence? *J Craniomaxillofac Surg* 2017;**45**:1278–86.
- Peled M, Ardekian L, Krausz AA, Aizenbud D. Comparing the effects of V–Y advancement versus simple closure on upper lip aesthetics after Le Fort I advancement. *J Oral Maxillofac Surg* 2004;**62**:315–9.
- Moragas JSM, van Cauteren W, Mommaerts MY. A systematic review on soft-to-hard tissue ratios in orthognathic surgery part I: maxillary repositioning osteotomy. *J Craniomaxillofac Surg* 2014;**42**:1341–51.
- Stella JP, Streater MR, Epker BN, Sinn DP. Predictability of upper lip soft tissue changes with maxillary advancement. *J Oral Maxillofac Surg* 1989;**47**:697–703.
- Rosen HM. Lip-nasal aesthetics following Le Fort I osteotomy. *Plast Reconstr Surg* 1988;**81**:171–82.
- Landis JR, Koch GG. The measurement of observer agreement for categorical data. *Biometrics* 1977;**33**:159–74.
- Haas Jr OL, Oliveira OE, Becker OE, Oliveira RB. Computer-aided planning in orthognathic surgery: systematic review. *Int J Oral Maxillofac Surg* 2015;**44**:329–42.
- Ryckman MS, Harrison S, Oliver D, Sander C, Boryor AA, Hohmann AA, Kilic F, Kim KB. Soft-tissue changes after maxillomandibular advancement surgery assessed with cone-beam computed tomography. *Am J Orthod Dentofacial Orthop* 2010;**137**:S86–93.
- Nadimi N, Tehranchi A, Azami N, Saedi B, Mollemans W. Comparison of soft-tissue profiles in Le Fort I osteotomy patients with Dolphin and Maxilim softwares. *Am J Orthod Dentofacial Orthop* 2013;**144**:654–62.
- Khambay B, Ullah R. Current methods of assessing the accuracy of three-dimensional soft tissue facial predictions: technical and clinical considerations. *Int J Oral Maxillofac Surg* 2015;**44**:132–8.



23. Marchetti C, Bianchi A, Muyldermans L, Di Martino M, Lancellotti L, Sarti A. Validation of new soft tissue software in orthognathic surgery planning. *Int J Oral Maxillofac Surg* 2011;**40**:26–32.
24. Mollemans W, Schutyser F, Nadjmi N, Maes F, Suetens P. Predicting soft tissue deformations for a maxillofacial surgery planning system: from computational strategies to a complete clinical validation. *Med Image Anal* 2007;**11**:282–301.
25. Seo SW, Jung YS, Baik HS. Three-dimensional analysis of midfacial soft tissue changes after maxillary posterior impaction and intraoral vertical ramus osteotomy for mandibular setback in class III patient. *J Craniofac Surg* 2017;**28**:1789–96.
26. Baik HS, Kim SY. Facial soft-tissue changes in skeletal class III orthognathic surgery patients analyzed with 3-dimensional laser scanning. *Am J Orthod Dentofacial Orthop* 2010;**138**:167–78.
27. Chen CYH, Lin CCH, Ko EWC. Effects of two alar base suture techniques on nasolabial changes after bimaxillary orthognathic surgery in Taiwanese patients with class III malocclusions. *Int J Oral Maxillofac Surg* 2015;**44**:816–22.
28. Howley C, Ali N, Lee R, Cox S. Use of the alar base cinch suture in Le Fort I osteotomy: is it effective? *Br J Oral Maxillofac Surg* 2011;**49**:127–30.
29. Jeong HI, Lee HS, Jung YS, Park HS, Jung HD. Nasal soft tissue change following bimaxillary orthognathic surgery. *J Craniofac Surg* 2017;**28**:e605–8.
30. Kim YI, Kim JR, Park SB. Three-dimensional analysis of midfacial soft tissue changes according to maxillary superior movement after horizontal osteotomy of the maxilla. *J Craniofac Surg* 2010;**21**:1587–90.
31. Kim BR, Oh KM, Cevidan L, Park JE, Sim HS, Seo SK, Kim YJ, Park YH. Analysis of 3D soft tissue changes after 1- and 2-jaw orthognathic surgery in mandibular prognathism patients. *J Oral Maxillofac Surg* 2013;**71**:151–61.
32. Lee JY, Kim YI, Hwang DS, Park SB. Effect of setback Le Fort I osteotomy on midfacial soft-tissue changes as evaluated by cone-beam computed tomography superimposition for cases of skeletal class III malocclusion. *Int J Oral Maxillofac Surg* 2013;**42**:790–5.
33. Lee TY, Kim KH, Yu HS, Kim KD, Jung YS, Baik HS. Correlation analysis of three-dimensional changes of hard and soft tissues in class III orthognathic surgery patients using cone-beam computed tomography. *J Craniofac Surg* 2014;**25**:1530–40.
34. Metzler P, Geiger EJ, Chang CC, Sirisoon-torn I, Steinbacher DM. Assessment of three-dimensional nasolabial response to Le Fort I advancement. *J Plast Reconstr Aesthet Surg* 2014;**67**:756–63.
35. Moroi A, Ishihara Y, Sotobori M, Nakazawa R, Higuchi M, Nakano Y, Marukawa K, Ueki K. Evaluation of soft tissue morphologic changes after using the alar base cinch suture in Le Fort I osteotomy in mandibular prognathism with and without asymmetry. *J Craniofac Surg* 2014;**42**:718–24.
36. Nkenke E, Vairaktaris E, Kramer M, Schlegel A, Holst A, Hirschfelder U, Wiltfang J, Newkan FW, Stamminger M. Three-dimensional analysis of changes of the malar-midfacial region after Le Fort I osteotomy and maxillary advancement. *Oral Maxillofac Surg* 2008;**12**:5–12.
37. Oh KM, Seo SK, Park JE, Sim HS, Cevidan L, Kim YJR, Park YH. Post-operative soft tissue changes in patients with mandibular prognathism after bimaxillary surgery. *J Craniofac Surg* 2013;**41**:204–11.
38. Park SB, Yoon JK, Kim YI, Hwang DS, Cho BH, Son WS. The evaluation of the nasal morphologic changes after bimaxillary surgery in skeletal class III malocclusion by using the superimposition of cone-beam computed tomography (CBCT) volumes. *J Craniofac Surg* 2012;**40**:e87–92.
39. van Loon B, van Heerbeek N, Bierebroodspot F, Verhamme L, Xi T, de Koning MJJ, Ingels KJAO, Berge RJ, Maal TJJ. Three-dimensional changes in nose and upper lip volume after orthognathic surgery. *Int J Oral Maxillofac Surg* 2015;**44**:83–9.
40. Wermker K, Kleinheinz J, Jung S, Dirksen D. Soft tissue response and facial symmetry after orthognathic surgery. *J Craniofac Surg* 2014;**42**:339–45.
41. Yuan L, Shen G, Wu Y, Jiang L, Yang Z, Liu J, Mao L, Fang B. Three-dimensional analysis of soft tissue changes in full-face view after surgical correction of skeletal class III malocclusion. *J Craniofac Surg* 2013;**24**:725–30.
42. Jakobsone G, Stenvik A, Espeland L. Soft tissue response after class III bimaxillary surgery. Impact of surgical change in face height and long-term skeletal relapse. *Angle Orthod* 2013;**83**:533–9.
43. Rustemeyer J, Martin A. Soft tissue response in orthognathic surgery patients treated by bimaxillary osteotomy: cephalometry compared with 2-D photogrammetry. *Oral Maxillofac Surg* 2013;**17**:33–41.
44. Abeltins A, Jakobsone G. Soft tissue thickness changes after correcting class III malocclusion with bimaxillary surgery. *Stomatologija* 2011;**13**:87–91.
45. Gassmann CJ, Nishioka GJ, Van Sickels JE, Thrash WJ. A lateral cephalometric analysis of nasal morphology following Le Fort I osteotomy applying photometric analysis techniques. *J Oral Maxillofac Surg* 1989;**47**:926–30.
46. Mansour S, Burstone C, Legan H. An evaluation of soft-tissue changes resulting from Le Fort I maxillary surgery. *Am J Orthod* 1983;**84**:37–47.
47. Marşan G, Hocaoglu E, Cura N, Emekli U. Nasal profile changes with Le Fort I maxillary advancement surgery. *Cleft Palate Craniofac J* 2015;**52**:152–6.
48. Aydil B, Özer N, Marşan G. Bimaxillary surgery in class III malocclusion: soft and hard tissue changes. *J Craniofac Surg* 2013;**41**:254–7.
49. Peled M, Ardekian L, Krausz AA, Aizenbud D. Comparing the effects of V–Y advancement versus simple closure on upper lip aesthetics after Le Fort I advancement. *J Oral Maxillofac Surg* 2004;**62**:315–9.
50. Chandra L, Sapru BL, Rai KK, Bhagwath S, Dagur R, Chandra S. Efficacy of V–Y closure of upper lip after Le Fort I osteotomy advancement and superior repositioning on facial esthetics in comparison to simple continuous closure: a statistical analysis. *J Maxillofac Oral Surg* 2013;**12**:366–71.
51. Esenlik E, Kaya B, Gülsen A, Çukurluoglu O, Özmen S, Yavuzer R. Evaluation of the nose profile after maxillary advancement with impaction surgeries. *J Craniofac Surg* 2011;**22**:2072–9.
52. Aydil B, Özer N, Marşan G. Facial soft tissue changes after maxillary impaction and mandibular advancement in high angle class II cases. *Int J Med Sci* 2012;**9**:316–21.
53. Altug-Atac AT, Bolatoglu H, Memikoglu UT. Facial soft tissue profile following bimaxillary orthognathic surgery. *Angle Orthod* 2008;**78**:50–7.
54. Hackney FL, Nishioka GJ, Van Sickels JE. Frontal soft tissue morphology with double V–Y closure following Le Fort I osteotomy. *J Oral Maxillofac Surg* 1988;**46**:850–6.
55. Hemmatpour S, Kadkhodaei Oliadarani F, Hasani A, Rakhshan V. Frontal-view nasolabial soft tissue alterations after bimaxillary orthognathic surgery in class III patients. *J Orofac Orthop* 2016;**77**:400–8.
56. Bailey LJ, Dover AJ, Proffit WR. Long-term soft tissue changes after orthodontic and surgical corrections of skeletal class III malocclusions. *Angle Orthod* 2007;**77**:389–96.
57. Hack GA, de Mol van Otterloo JJ, Nanda R. Long-term stability and prediction of soft tissue changes after Le Fort I surgery. *Am J Orthod Dentofacial Orthop* 1993;**104**:544–55.
58. Yen CY, Kuo CL, Liu IH, Su WC, Jiang HR, Huang IG, Liu SY, Lee SY. Modified alar base cinch suture fixation at the bilateral lower border of the piriform rim after a maxillary Le Fort I osteotomy. *Int J Oral Maxillofac Surg* 2016;**45**:1459–63.
59. Rosenberg A, Muradin MS, van der Bilt A. Nasolabial esthetics after Le Fort I osteotomy and V–Y closure: a statistical evaluation. *Int J Adult Orthodon Orthognath Surg* 2002;**17**:29–39.
60. Misir AF, Manisali M, Egrioglu E, Naini FB. Retrospective analysis of nasal soft tissue profile changes with maxillary surgery. *J Oral Maxillofac Surg* 2011;**69**:e190–4.

61. Marşan G, Cura N, Emekli U. Soft and hard tissue changes after bimaxillary surgery in Turkish female class III patients. *J Cranio-maxillofac Surg* 2009;**37**:8–17.
62. Becker OE, Avelar RL, Dolzan Ado N, Haas Jr OL, Scolari N, Oliveira RB. Soft and hard tissue changes in skeletal class III patients treated with double-jaw orthognathic surgery—maxillary advancement and mandibular setback. *Int J Oral Maxillofac Surg* 2014;**43**:204–12.
63. Jokić D, Jokić D, Ugleić V, Macan D, Kneević P. Soft tissue changes after mandibular setback and bimaxillary surgery in class III patients. *Angle Orthod* 2013;**83**:817–23.
64. Lee HJ, Park HS, Kyung HM, Kwon TG. Soft tissue changes and skeletal stability after modified quadrangular Le Fort I osteotomy. *Int J Oral Maxillofac Surg* 2015;**44**:356–61.
65. Louis PJ, Austin RB, Waite PD, Mathews CS. Soft tissue changes of the upper lip associated with maxillary advancement in obstructive sleep apnea patients. *J Oral Maxillofac Surg* 2001;**59**:151–6.
66. Rahpeyma A, Khajehahmadi S. Effects of bimax and segmental surgeries for correction of bimaxillary dentoalveolar protrusion class I on soft tissue parameters: upper lip thickness and curvature, nasolabial angle and nasal prominence. *J Contemp Dent Pract* 2013;**14**:1087–93.
67. Stella JP, Streater MR, Epker BN, Sinn DP. Predictability of upper lip soft tissue changes with maxillary advancement. *J Oral Maxillofac Surg* 1989;**47**:697–703.
68. Chew MT. Soft and hard tissue changes after bimaxillary surgery in Chinese class III patients. *Angle Orthod* 2005;**75**:959–63.
69. Lin SS, Kerr WJ. Soft and hard tissue changes in class III patients treated by bimaxillary surgery. *Eur J Orthod* 1998;**20**:25–33.
70. Fernández Sanromán J, Costas López A, Fernández Ferro M, Arenaz Bua J, López de Sánchez A. Subnasal modified Le Fort I osteotomy: indications and results. *J Craniomaxillofac Surg* 2014;**42**:347–50.
71. Schendel SA, Eisenfeld JH, Bell WH, Epker BN. Superior repositioning of the maxilla: stability and soft tissue osseous relations. *Am J Orthod* 1976;**70**:663–74.
72. de Lira Ade L, de Moura WL, Artese F, Bittencourt MA, Nojima LI. Surgical prediction of skeletal and soft tissue changes in treatment of class II. *J Craniomaxillofac Surg* 2013;**41**:198–203.
73. Muradin MS, Rosenberg A, van der Bilt A, Stoelinga PJ, Koole R. The effect of alar cinch sutures and V–Y closure on soft tissue dynamics after Le Fort I intrusion osteotomies. *J Craniomaxillofac Surg* 2009;**37**:334–40.
74. Konstantos KA, O'Reilly MT, Close J. The validity of the prediction of soft tissue profile changes after Le Fort I osteotomy using the dentofacial planner (computer software). *Am J Orthod Dentofacial Orthop* 1994;**105**:241–9.
75. Al-Gunaid T, Yamaki M, Takagi R, Saito I. Soft and hard tissue changes after bimaxillary surgery in Japanese class III asymmetric patients. *J Orthod Sci* 2012;**1**:69–76.
76. Upton PM, Sadowsky PL, Sarver DM, Heaven TJ. Evaluation of video imaging prediction in combined maxillary and mandibular orthognathic surgery. *Am J Orthod Dentofacial Orthop* 1997;**112**:656–65.
77. Steinhäuser S, Richter U, Richter F, Bill J, Rudzki-Janson I. Profile changes following maxillary impaction and autorotation of the mandible. *J Orofac Orthop* 2008;**69**:31–41.
78. Donatsky O, Björn-Jørgensen J, Hermund NU, Nielsen H, Holmqvist-Larsen M, Nerder PH. Immediate postoperative outcome of orthognathic surgical planning, and prediction of positional changes in hard and soft tissue, independently of the extent and direction of the surgical corrections required. *Br J Oral Maxillofac Surg* 2011;**49**:386–91.
79. Bailey LJ, Collie FM, White Jr RP. Long-term soft tissue changes after orthognathic surgery. *Int J Adult Orthodon Orthognath Surg* 1996;**11**:7–18.
80. Proffit WR, Phillips C. Adaptations in lip posture and pressure following orthognathic surgery. *Am J Orthod Dentofacial Orthop* 1988;**93**:294–302.
81. Almkhtar A, Ayoub A, Khambay B, McDonald J, Ju X. State-of-the-art three-dimensional analysis of soft tissue changes following Le Fort I maxillary advancement. *Br J Oral Maxillofac Surg* 2016;**54**:812–7.
82. Hajeer MY, Ayoub AF, Millet DT. Three-dimensional assessment of facial soft-tissue asymmetry before and after orthognathic surgery. *Br J Oral Maxillofac Surg* 2004;**42**:396–404.
83. Hwang DS, Kim YI, Park SB, Lee JY. Midfacial soft tissue changes after leveling Le Fort I osteotomy with differential reduction: cone-beam computed tomography volume superimposition. *Angle Orthod* 2011;**82**:424–31.
84. Kim YI, Park SB, Son WS, Hwang DS. Midfacial soft-tissue changes after advancement of maxilla with Le Fort I osteotomy and mandibular setback surgery: comparison of conventional and high Le Fort I osteotomies by superimposition of cone-beam computed tomography volumes. *J Oral Maxillofac Surg* 2011;**69**:225–33.
85. Liebrechts J, Xi T, Timmermans M, de Koning M, Berge S, Hoppenreijts T, Maal T. Accuracy of three-dimensional soft tissue simulation in bimaxillary osteotomies. *J Craniomaxillofac Surg* 2015;**43**:329–35.
86. McCance AM, Moss JP, Wright WR, Linney AD, James DR. A three-dimensional soft tissue analysis of 16 skeletal class III patients following bimaxillary surgery. *Br J Oral Maxillofac Surg* 1992;**30**:221–32.
87. Ubaya T, Sherriff A, Ayoub A, Khambay B. Soft tissue morphology of the nasomaxillary complex following surgical correction of maxillary hypoplasia. *Int J Oral Maxillofac Surg* 2012;**41**:727–32.
88. Verdenik M, Ihan Hren N. Differences in three-dimensional soft tissue changes after upper, lower, or both jaw orthognathic surgery in skeletal class III patients. *Int J Oral Maxillofac Surg* 2014;**43**:1345–51.
89. Schendel SA, Hazan-Molina H, Aizenbud D. Combined orthognathic distraction procedure: Le Fort I maxillary osteotomy and mandibular curvilinear distraction osteogenesis. A new technique for craniofacial management. *Plast Reconstr Surg* 2016;**2014**(133):874–7.
90. Conley RS, Legan HL. Correction of severe obstructive sleep apnea with bimaxillary transverse distraction osteogenesis and maxillomandibular advancement. *Am J Orthod Dentofacial Orthop* 2006;**129**:283–92.
91. Im J, Kang SH, Lee JY, Kim MK, Kim JH. Surgery-first approach using a three-dimensional virtual setup and surgical simulation for skeletal class III correction. *Korean J Orthod* 2014;**44**:330–41.
92. Ahn HW, Cho IS, Cho KC, Choi JY, Chung JW, Baek SH. Surgical treatment modality for facial esthetics in an obstructive sleep apnea patient with protrusive upper lip and acute nasolabial angle. *Angle Orthod* 2013;**83**:355–63.
93. Zahrani AA. Correction of vertical maxillary excess by superior repositioning of the maxilla. *Saudi Med J* 2010;**31**:695–702.
94. Sabuncuoglu F, Varol A, Sençimen M, Olmez H. Onlay iliac bone grafting as an ancillary augmentation procedure for paranasal rejuvenation during bimaxillary surgery. *Oral Surg Oral Med Oral Pathol Oral Radiol Endod* 2010;**109**:e13–9.
95. Sforza C, Peretta R, Grandi G, Ferronato G, Ferrario VF. Soft tissue facial volumes and shape in skeletal class III patients before and after orthognathic surgery treatment. *J Plast Reconstr Aesthet Surg* 2007;**60**:130–8.
96. Ullah R, Turner PJ, Khambay BS. Accuracy of three-dimensional soft tissue predictions in orthognathic surgery after Le Fort I advancement osteotomies. *Br J Oral Maxillofac Surg* 2015;**53**:153–7.
97. Gerbino G, Bianchi FA, Verzé L, Ramieri G. Soft tissue changes after maxillo-mandibular advancement in OSAS patients: a three-dimensional study. *J Craniomaxillofac Surg* 2014;**42**:66–72.
98. Gallagher DM, Bell WH, Storum KA. Soft tissue changes associated with advancement genioplasty performed concomitantly with superior repositioning of the maxilla. *J Oral Maxillofac Surg* 1984;**42**:238–42.
99. Metzler P, Geiger EJ, Chang CC, Steinbacher DM. Surgically assisted maxillary expansion imparts three-dimensional nasal

- change. *J Oral Maxillofac Surg* 2014;**72**:2005–14.
100. Shafi MI, Ayoub A, Ju X, Khambay B. The accuracy of three-dimensional prediction planning for the surgical correction of facial deformities using Maxilim. *Int J Oral Maxillofac Surg* 2013;**42**:801–6.
  101. Suzuki-Okamura E, Higashihori N, Kawamoto T, Moriyama K. Three-dimensional analysis of hard and soft tissue changes in patients with facial asymmetry undergoing 2-jaw surgery. *Oral Surg Oral Med Oral Pathol Oral Radiol* 2015;**120**:299–306.
  102. Ferrario VF, Sforza C, Schmitz JH, Santoro F. Three-dimensional facial morphometric assessment of soft tissue changes after orthognathic surgery. *Oral Surg Oral Med Oral Pathol Oral Radiol Endod* 1999;**88**:549–56.
  103. Ulusoy I, Akagunduz E, Sabuncuoglu F, Gorgulu S, Ucoğ O. Use of the dynamic volume spline method to predict facial soft tissue changes associated with orthognathic surgery. *Oral Surg Oral Med Oral Pathol Oral Radiol Endod* 2010;**110**:e17–23.
  104. Miller L, Morris DO, Berry E. Visualizing three-dimensional facial soft tissue changes following orthognathic surgery. *Eur J Orthod* 2007;**29**:14–20.
  105. Kolokitha OE, Athanasiou AE, Tuncay OC. Validity of computerized predictions of dentoskeletal and soft tissue profile changes after mandibular setback and maxillary impaction osteotomies. *Int J Adult Orthodon Orthognath Surg* 1995;**11**:137–54.
  106. Enacar A, Taner T, Toroğlu S. Analysis of soft tissue profile changes associated with mandibular setback and double-jaw surgeries. *Int J Adult Orthodon Orthognath Surg* 1998;**14**:27–35.
  107. Eales EA, Jone ML, Newton C, Sugar AW. A study of the accuracy of predicted soft tissue changes produced by a computer software package (COG 3. 4) in a series of patients treated by the Le Fort I osteotomy. *Br J Oral Maxillofac Surg* 1995;**33**:362–9.
  108. Vasudavan S, Jayaratne YSN, Padwa BL. Nasolabial soft tissue changes after Le Fort I advancement. *J Oral Maxillofac Surg* 2012;**70**:e270–7.
  109. Verzé L, Bianchi FA, Ramieri G. Three-dimensional laser scanner evaluation of facial soft tissue changes after Le Fort I advancement and rhinoplasty surgery: patients with cleft lip and palate vs patients with nonclefted maxillary retrognathic dysplasia (control group). *Oral Surg Oral Med Oral Pathol Oral Radiol* 2014;**117**:416–23.
  110. Leshem D, Tompson B, Phillips JH. Segmental Le Fort I surgery: turning a predicted soft-tissue failure into a success. *Plast Reconstr Surg* 2006;**118**:1213–6.
  111. Eales EA, Newton C, Jones ML, Sugar A. The accuracy of computerized prediction of the soft tissue profile: a study of 25 patients treated by means of the Le Fort I osteotomy. *Int J Adult Orthodon Orthognath Surg* 1994;**9**:141–52.
  112. Terajima M, Furuich Y, Aoki Y, Goto TK, Tokumori K, Nakasima A. A 3-dimensional method for analyzing facial soft-tissue morphology of patients with jaw deformities. *Am J Orthod Dentofacial Orthop* 2009;**135**:715–22.
  113. Lee HJ, Suh HY, Lee YS, Lee SJ, Donatelli RE, Dolce C, Wheeler TT. A better statistical method of predicting postsurgery soft tissue response in class II patients. *Angle Orthod* 2014;**84**:322–8.
  114. Sykes JM, Amin SH, Hatcher DC, Kim J. 3D analysis of dentofacial deformities: a new model for clinical application. *Facial Plast Surg Clin North Am* 2011;**19**:767–71.
  115. Marchetti C, Bianchi A, Bassi M, Gori R, Lamberti C, Sarti A. Mathematical modeling and numerical simulation in maxillofacial virtual surgery (VISU). *J Craniofac Surg* 2006;**17**:661–7.
  116. Kaipatur N, Flores-Mir C. Accuracy of computer programs in predicting orthognathic surgery soft tissue response. *J Oral Maxillofac Surg* 2009;**67**:751–9.
  117. Khamashta-Ledezma L, Naini FB. Systematic review of changes in maxillary incisor exposure and upper lip position with Le Fort I type osteotomies with or without cinch sutures and/or VY closures. *Int J Oral Maxillofac Surg* 2014;**43**:46–61.
  118. Moragas JSM, Van Cauteren W, Mommaerts MY. A systematic review on soft-to-hard tissue ratios in orthognathic surgery part I: maxillary repositioning osteotomy. *J Craniofac Surg* 2014;**42**:1341–51.
  119. Altman JI, Oeltjen JC. Nasal deformities associated with orthognathic surgery: analysis, prevention, and correction. *J Craniofac Surg* 2007;**18**:734–9.
  120. Jayaratne YSN, Zwahlen RA, Lo J, Cheung LK. Facial soft tissue response to anterior segmental osteotomies: a systematic review. *Int J Oral Maxillofac Surg* 2010;**39**:1050–8.
  121. McCance AM, Moss JP, Fright WR, James DR, Linney AD. A three dimensional analysis of soft and hard tissue changes following bimaxillary orthognathic surgery in skeletal III patients. *Br J Oral Maxillofac Surg* 1992;**30**:305–12.
  122. Berger JL, Pangrazio-Kulbersh V, Thomas BW, Kaczynski R. Photographic analysis of facial changes associated with maxillary expansion. *Am J Orthod Dentofacial Orthop* 1999;**116**:563–71.
  123. Nevzatoglu Ş, Küçükkeleş N. Long-term results of surgically assisted maxillary protraction vs regular facemask. *Angle Orthod* 2014;**84**:1002–9.
  124. Ko EWC, Huang CS, Chen YR. Characteristics and corrective outcome of face asymmetry by orthognathic surgery. *J Oral Maxillofac Surg* 2009;**67**:2201–9.
  125. Shetty V, Mohan A. A prospective, randomized, double-blind, placebo-controlled clinical trial comparing the efficacy of systemic enzyme therapy for edema control in orthognathic surgery using ultrasound scan to measure facial swelling. *J Oral Maxillofac Surg* 2013;**71**:1261–7.
  126. Yu CC, Bergeron L, Lin CH, Chu YM, Chen YR. Single-splint technique in orthognathic surgery: intraoperative checkpoints to control facial symmetry. *Plast Reconstr Surg* 2009;**124**:879–86.
  127. Upton PM, Sadowsky PL, Sarver DM, Heaven TJ. Evaluation of video imaging prediction in combined maxillary and mandibular orthognathic surgery. *Am J Orthod Dentofacial Orthop* 1997;**112**:656–65.
  128. Schendel SA, Jacobson R, Khalessi S. 3-Dimensional facial simulation in orthognathic surgery: is it accurate? *J Oral Maxillofac Surg* 2013;**71**:1406–14.
  129. Choi JH, Mah J. A new method for superimposition of CBCT volumes. *J Clin Orthod* 2010;**44**:303–12.
  130. Maes F, Collignon A, Vandermeulen D, Marchal G, Suetens P. Multimodality image registration by maximization of mutual information. *IEEE Trans Med Imaging* 1997;**16**:187–98.
  131. Kuvat SV, Güven E, Hocaoglu E, Basaran K, Marsan G, Cura N, Emekli U. Body fat composition and weight changes after double-jaw osteotomy. *J Craniofac Surg* 2010;**21**:1516–8.
  132. Nkenke E, Langer A, Laboureaux X, Benz M, Maier T, Kramer M, Häusler G, Kessler P, Wiltfang J, Neukam FW. Validation of in vivo assessment of facial soft tissue volume changes and clinical application in midfacial distraction: a technical report. *Plast Reconstr Surg* 2003;**112**:367–80.
  133. Cevidanes LHC, Heymann G, Cornelis MA, DeClerck HJ, Tulloch JFC. Superimposition of 3-dimensional cone-beam computed tomography models of growing patients. *Am J Orthod Dentofacial Orthop* 2009;**136**:94–9.

## Address:

Ariane Paredes de Sousa Gil  
 Instituto Maxilofacial  
 Teknon Medical Centre  
 Carrer Vilana  
 12 (Off 185)  
 08022 Barcelona  
 Spain  
 Tel.: +34 933 933 185; Fax: +34 933 933 085  
 E-mail: ariane.psgil@gmail.com