

Technical Note
Orthognathic Surgery

Minimally invasive intraoral proportional condylectomy with a three-dimensionally printed cutting guide

O. L. Haas Junior, R. Fariña, F. Hernández-Alfaro, R. B. de Oliveira: Minimally invasive intraoral proportional condylectomy with a three-dimensionally printed cutting guide. *Int. J. Oral Maxillofac. Surg.* 2019; xxx: xxx-xxx. © 2020 International Association of Oral and Maxillofacial Surgeons. Published by Elsevier Ltd. All rights reserved.

O. L. Haas Junior^{1,2}, R. Fariña^{3,4,5},
F. Hernández-Alfaro^{6,7},
R. B. de Oliveira^{1,2}

¹Department of Oral and Maxillofacial Surgery, Pontificia Universidade Católica do Rio Grande do Sul, Porto Alegre, Brazil; ²Oral and Maxillofacial Surgery, Hospital São Lucas, Porto Alegre, Brazil; ³Department of Oral and Maxillofacial Surgery, Hospital del Salvador, Providencia, Región Metropolitana, Chile; ⁴Department of Oral and Maxillofacial Surgery, Hospital San Borja Arriarán, Santiago, Chile; ⁵Oral and Maxillofacial Surgery, Universidad de Chile, Santiago, Chile; ⁶Department of Oral and Maxillofacial Surgery, Universitat Internacional de Catalunya, Sant Cugat del Vallès, Barcelona, Spain; ⁷Institute of Maxillofacial Surgery, Teknon Medical Centre, Barcelona, Spain

Abstract. The aim of this study was to describe the steps of a minimally invasive surgical technique used to perform a proportional intraoral condylectomy with a three-dimensionally (3D) printed cutting guide. The technique consists of two steps: virtual surgical planning and intraoral condylectomy. During virtual surgical planning, the mandibular ramus was measured bilaterally, the height of the proportional condylectomy was planned virtually, and a cutting guide was 3D printed. In the intraoral condylectomy, the mandibular condyle was approached intraorally, the 3D printed cutting guide was positioned in the sigmoid notch, and the proportional condylectomy was performed. The protocol reported in this technical note is the sum of knowledge acquired from a series of studies published previously by the authors, who have jointly developed a surgical technique that is both minimally invasive and accurate for the treatment of condylar hyperplasia.

Key words: temporomandibular joint; condylar hyperplasia; intraoral; computer-assisted; CAD/CAM; minimally invasive surgery.

Accepted for publication 26 June 2020

Condylar hyperplasia is a condition that causes excessive growth of the mandibular condyle, occurring unilaterally or bilaterally, with consequences that result in deformities and facial asymmetry^{1,2}. According to Wolford et al.², this hyperplastic growth can be classified into four types (1, 2, 3, and 4), with types 1 and 2 showing a higher prevalence.

Methods for the treatment of condylar hyperplasia have been described widely in

the literature, and the following may be indicated: orthognathic surgery alone; high, low, or proportional condylectomy alone; or a combination of these techniques^{3,4}. Currently, computer-aided design and computer-aided manufacturing (CAD/CAM) technology is an important tool to assist in the planning of these surgical techniques^{5,6}.

The aim of this study was to describe the steps of a minimally invasive surgical

technique used to perform a proportional intraoral condylectomy with a three-dimensionally (3D) printed cutting guide.

Technique

The surgical protocol described here is indicated mainly for cases of condylar hyperplasia types 1 and 2 (Wolford classification²) requiring condylectomy,

which may be combined or not with orthognathic surgery.

Virtual surgical planning

DICOM data files obtained from full-face cone beam computed tomography scans (CBCT) (i-CAT; Imaging Sciences International, Inc., Hatfield, PA, USA) were imported into Dolphin 3D Imaging software, version 11.95 (Dolphin Imaging and Management Solutions, Chatsworth, CA, USA). The vertical CBCT scans were performed in 'extended field' mode with a field of view (FOV) of 17 cm diameter, 22 cm height; the scan time was 2×20 s, the voxel size was 0.4 mm, and settings were 120 kV and 48 mA.

Proportional condylectomy (3D planning stage)

The difference in vertical size between the side with condylar hyperplasia and the unaffected side was determined by performing bilateral linear measurements from the mandibular angle to the highest point in the condyle region. The vertical difference between the two sides was used as a reference for the height of the proportional condylectomy on the hyperplastic side^{1,7,8}

(Fig. 1A). An osteotomy was planned in the condylar neck region, extending from the highest point of the condyle towards the sigmoid notch, a distance covering the vertical difference between the two mandibular rami (Fig. 1B).

3D printed cutting guide

The DICOM images of the mandibular ramus with condylar hyperplasia were converted into stereolithography (STL) format in Dolphin 3D Imaging software. The STL file was then imported and opened in the free 3D Builder software (Windows 10; Microsoft Corporation, Redmond, WA, USA) to model a cutting guide that anatomically fits the condylar neck and covers the area from the sigmoid notch to the previously defined osteotomy line of the proportional condylectomy (Fig. 1C).

As the last step of the CAD/CAM protocol, the cutting guide modelled in 3D Builder was fabricated using a 3D printer.

Intraoral condylectomy

Intraoral approach

An electrocautery incision was made in the buccal mucosa region in contact with

the ascending mandibular ramus, followed by total mucoperiosteal flap elevation to expose the coronoid process, osteotomy of the coronoid process to better visualize the sigmoid notch, sub-periosteal access to the condylar process to dissect off the lateral pterygoid muscle and articular capsule, and intermaxillary fixation of a locking screw (above the osteotomy region) with braided steel wire⁹.

Proportional condylectomy (surgical stage)

After access to the condylar region, the cutting guide was positioned on the anatomical surface corresponding to its surface-best-fit, as delimited during the 3D process of the proportional condylectomy (Fig. 2A). A horizontal osteotomy was performed using a piezoelectric surgery device at the rear end of the cutting guide and the upper portion of the mandibular condyle was separated from the rest of the mandible (Fig. 2B). The steel wire fixed with a locking screw was then pulled to remove the surgical specimen (Fig. 2C). Suture was performed with continuous stitches using absorbable suture material.

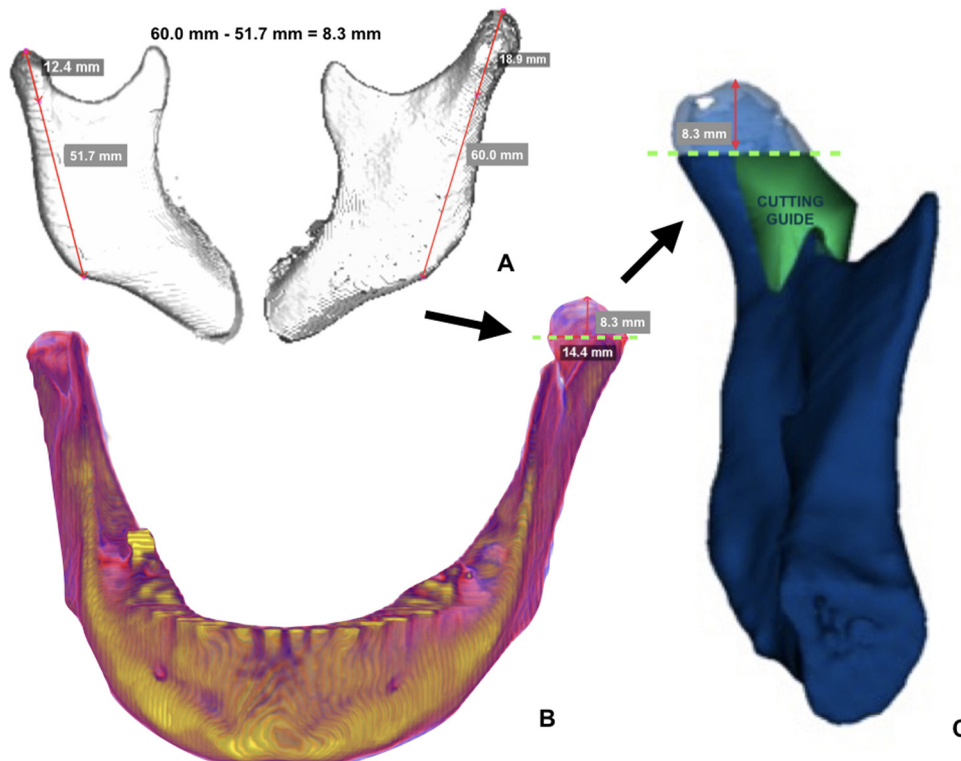


Fig. 1. (A) Proportional condylectomy virtual planning. (B) Confirming that the entire diseased area will be removed. (C) Proportional condylectomy cutting guide.

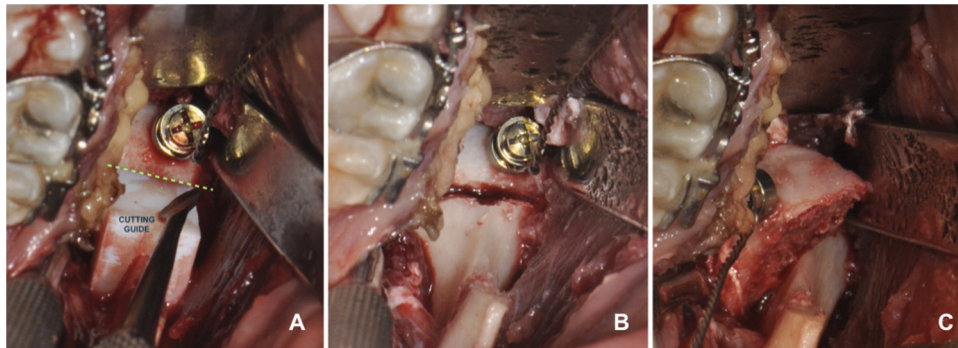


Fig. 2. (A) Cutting guide in surgical position. (B) Osteotomy. (C) Proportional condylectomy with intraoral approach.

Discussion

The combination of techniques, such as intraoral access to the condyle⁹ and proportional condylectomy^{1,7,8}, helps further develop the concept of a minimally invasive surgical procedure. This provides an approach that results in less damage to the articular soft tissue region and an osteotomy technique that allows removal of the diseased condylar bone as early as possible, in order to maintain the vertical balance of the mandibular rami and avoid a more invasive surgical intervention in the future in the case of dentofacial deformities, such as asymmetry, as a sequela of condylar hyperplasia.

To improve the minimally invasive concept and give more precision to the surgical procedure of proportional condylectomy with an intraoral approach, a cutting guide was fabricated using CAD/CAM technology. The cutting guide has reduced dimensions compatible with a limited surgical approach and no prominent structures for its fixation, and it can be anatomically fitted using the surface-best-fit method. This tool fits the sigmoid notch and extends to the area where the osteotomy must be performed using a piezoelectric surgery device, thus providing safety and accuracy in removing the diseased tissue and ensuring the vertical balance of the mandibular rami. The condylar height where the osteotomy must be performed is always determined using a Hounsfield unit colour scale¹⁰, to ensure that the region of proportional condylectomy will cover the entire pathological area or the hyperplastic area. After this step, the cutting guide can easily be modelled virtually in a free software that does not require specialized 3D modelling skills, avoiding the need to use specialized software.

Given the reliability of this combination of techniques, it can also be used in cases where both a condylectomy and orthognathic surgery are performed in the same surgical session. The cutting guide provides precision with respect to the height of the mandibular rami⁶, increasing the ability to reproduce the virtual planning of orthognathic surgery to correct facial asymmetry, which is known to be accurate⁵. When only a condylectomy is performed, the technique described here takes no longer than 25 minutes, as it allows a rapid and direct approach to the hyperplastic region⁹. Therefore, when performed in combination with orthognathic surgery, this short period of time is added to the total intervention time. Also, this combination reduces the chance of infection, because both procedures are performed through the same intraoral access, avoiding communication between the intraoral and extraoral environment, as reported previously with similar techniques⁶.

The technique described here has already been used by the authors in condylar hyperplasia types 1 and 2², either combined or not with orthognathic surgery. Whenever both interventions are performed at the same time, the same surgical sequence is followed to ensure reliability between the virtual planning and surgical stage. The following surgical steps are performed: condylectomy, mandible first with bilateral sagittal split ramus osteotomy (to have the maxilla as a fixed reference point), and maxilla last.

Several studies were published previously by the authors of this article^{1,5,7,8,9,10}, before the collaborative development of this surgical technique for the treatment of condylar hyperplasia, which is both minimally invasive and accurate. Thus, we believe that by com-

binning knowledge we managed to develop a technically simple protocol to be shared and reproduced in the clinical setting.

Funding

There was no funding for this study.

Competing interests

There are no conflicts of interest.

Ethical approval

Not required.

Patient consent

Written patient consent was obtained to publish the surgical photographs.

References

1. Fariña R, Moreno E, Lolas J, Silva F, Martínez B. Three-dimensional skeletal changes after early proportional condylectomy for condylar hyperplasia. *Int J Oral Maxillofac Surg* 2019;**48**:941–51.
2. Wolford LM, Movahed R, Perez DE. A classification system for conditions causing condylar hyperplasia. *J Oral Maxillofac Surg* 2014;**72**:567–95.
3. Ghawsi S, Aagaard E, Thygesen TH. High condylectomy for the treatment of mandibular condylar hyperplasia: a systematic review of the literature. *Int J Oral Maxillofac Surg* 2016;**45**:60–7.
4. Niño-Sandoval TC, Maia FPA, Vasconcelos BCE. Efficacy of proportional versus high condylectomy in active condylar hyperplasia—a systematic review. *J Craniomaxillofac Surg* 2019;**47**:1222–32.
5. Haas Jr OL, Becker OE, de Oliveira RB. Computer-aided planning in orthognathic

4 Haas Junior et al.

- surgery—systematic review. *Int J Oral Maxillofac Surg* 2015;**44**:329–42.
6. Sembronio S, Tel A, Costa F, Robiony M. An updated protocol for the treatment of condylar hyperplasia: computer-guided proportional condylectomy. *J Oral Maxillofac Surg* 2019;**77**:1457–65.
 7. Fariña R, Pintor F, Pérez J, Pantoja R, Berner D. Low condylectomy as the sole treatment for active condylar hyperplasia: facial, occlusal and skeletal changes. An observational study. *Int J Oral Maxillofac Surg* 2015;**44**:217–25.
 8. Fariña R, Olate S, Raposo A, Araya I, Alister JP, Uribe F. High condylectomy versus proportional condylectomy: is secondary orthognathic surgery necessary? *Int J Oral Maxillofac Surg* 2016;**45**:72–7.
 9. Hernández-Alfaro F, Méndez-Manjón I, Valls-Ontañón A, Guijarro-Martínez R. Minimally invasive intraoral condylectomy: proof of concept report. *Int J Oral Maxillofac Surg* 2016;**45**:1108–14.
 10. Méndez-Manjón I, Haas Jr OL, Guijarro-Martínez R, de Oliveira RB, Valls-Ontañón A, Hernández-Alfaro F. Semi-automated three-dimensional condylar reconstruction. *J Craniofac Surg* 2019;**30**:2555–9.

Address:
Orion Luiz Haas Junior
Department of Oral and
Maxillofacial Surgery
Pontifícia Universidade Católica do
Rio Grande do Sul
Avenida Ipiranga
6681
Building 6
90619-900
Porto Alegre
Brazil
Tel.: +55 51 999679116
E-mail: olhj@hotmail.com