



Redefining our protocol of the orthognathic surgery-first approach after 10 years of experience

F. Hernández-Alfaro^{a,b}, C. Mezquida-Fernández^c, P.J. Brabyn^c, E. Querejeta-Lomas^c, J. Torres-Gaya^c, A. Valls-Ontañón^{a,b,*}

^a Institute of Maxillofacial Surgery, Teknon Medical Center Barcelona, Barcelona, Spain

^b Department of Oral and Maxillofacial Surgery, Universitat Internacional de Catalunya, Sant Cugat del Vallès, Barcelona, Spain

^c Institute of Maxillofacial Surgery, Teknon Medical Center Barcelona, Barcelona, Spain

Accepted 20 April 2022

Abstract

The objective of this study was to update and redefine some concepts of the surgery-first (SF) approach, regarding its indications and contraindications, virtual planning work-up, surgical tips, and postoperative orthodontic benefits, after 10 years of experience. A retrospective analysis was made of orthognathic surgical procedures following the SF protocol between January 2010 and December 2019 to review inclusion and exclusion criteria, diagnostic workflow, surgical tips, and postoperative outcomes. A total of 148 SF procedures were performed during this period, which corresponded to only 9.2% of the total orthognathic surgeries performed, which means that we have broadened the exclusion criteria instead of reducing them. Surgical tips include interdental corticotomies solely in cases of anterior crowding and leaving the intermaxillary fixation miniscrews in place postoperatively for orthodontic skeletal anchorage. The mean duration of postoperative orthodontic treatment was reduced in comparison to conventional surgery (36.8 vs 87.5 weeks). The overall degree of satisfaction was high not only for the patients, but also for the orthodontists and surgeon. SF is especially indicated for patients who desire an immediate aesthetic result, with short-term orthodontics, or for treatment of sleep-related breathing disorders, if they meet the established criteria.

© 2022 The British Association of Oral and Maxillofacial Surgeons. Published by Elsevier Ltd. All rights reserved.

Keywords: Orthognathic Surgery; Dental Occlusion; Aesthetics; Sleep disorders; Virtual Reality; Three-dimensional imaging

Introduction

In recent years, timing of the ortho-surgical sequence has been revisited and new schemes have been proposed. The traditional ‘orthodontics before surgery’ approach was the norm until recently when Nagasaka et al.,¹ in pursuit of improving patient satisfaction, proposed operating before orthodontic treatment, and in doing so re-popularised an older protocol. The surgery-first (SF) protocol consists of correcting bone before correcting tooth position and occlusion, and does not require the pre-surgical orthodontic treatments of decompensation, dental alignment, and levelling.² By starting the treatment with surgery, an immediate improvement of the skeletal discrepancy, upper airway

volume, and facial aesthetics can be achieved,³ and the period of ‘clinical worsening’ (occlusally and aesthetically) seen during orthodontic decompensation (mainly in marked Class III cases rather than in Class II skeletal dysplasias) is avoided.

Thanks to 3D imaging and simulation, the prediction of dental and bony movements is now more reliable, and stability after surgery without a previous orthodontic treatment is feasible.⁴ In this case, a virtual orthodontic setup must be created to predict the final dental occlusion, especially regarding the inclination of the incisors, in order to establish a surgical treatment objective (STO).⁵

With the SF approach, the overall duration of treatment is reduced, since the efficiency of postoperative orthodontic treatment is increased^{3,6,7} due to the regional and systemic acceleratory phenomenon (RAP⁸ and SAP,⁹ respectively). This leads to a local and systemic increased metabolic turnover of bone that has been shown to accelerate the tooth

* Corresponding author at: Maxillofacial Institute, Teknon Medical Center, Carrer de Vilana, 12 (desp 185), 08022 Barcelona, Spain.

E-mail address: avalls@institutomaxilofacial.com (A. Valls-Ontañón).

movement with a peak activity during the first two months after surgery.^{4,10} Moreover, patients treated following the SF protocol report higher degrees of satisfaction, cooperate better, and have a better quality of life (QoL).¹¹

However, as scientific evidence related to SF increases, its indications and protocols are constantly changing, which is why the treating specialist must be up to date. Therefore, the aim of the present study was to update and redefine some concepts of the SF approach, regarding its indications and contraindications (Table 1), virtual planning work-up, surgical tips and postoperative orthodontics benefits after 10 years of experience and to update our previous publications on this topic.^{3,12–14}

Methods

Study design and sample selection

A retrospective analysis of all orthognathic surgical procedures with an SF approach performed by the same surgeon (FHA), at a specialised centre in dental-maxillofacial anomalies during a 10-year time period (between January 2010 and December 2019), was carried out to update concepts of the SF orthognathic surgery protocol.

Patients over the age of 18 (with a complete maxillofacial development) who had no active orthodontic treatment before the surgery (or during the previous 2 years), were included. Patients that required any active orthodontic treatment before surgery were excluded, as well as surgery-only procedures.¹⁴ Subjects presenting with any craniofacial syndrome or pathological background that could compromise bony healing were also excluded.

The study was approved by the Ethics Committee of the Teknon Medical Centre (Barcelona, Spain) (Ref. SF10y), and was conducted in accordance with the ethical standards laid down in the 1964 Declaration of Helsinki and its later amendments.

Inclusion and exclusion criteria for surgery-first approach

After the assessment of the patient's dentofacial anomaly, the feasibility of performing SF was evaluated by the combined orthodontic-surgical team using study models and the complete diagnostic work-up (clinical pictures, a cone-beam computed tomographic (CBCT) scan (iCAT, Imaging Sciences International) of the head of the patient, and an intraoral surface scan of the dental arches using a Lava Scan ST scanner (3M™ ESPE)).¹⁵ First, postoperative occlusal harmony was verified in order to obtain final postoperative stability. Then, according to the update of our protocol,¹³ the current indications for including or excluding patients from an SF approach are listed in Table 1.

Virtual planning work-up

The preoperative CBCT scan of the patient's head and face, and surface intraoral scanning of the dental arches were imported and fused using a software program (Dolphin® 3D Orthognathic Surgery Planning Software, Version 11.8) for pre-surgical 3D planning.¹⁵ A virtual orthodontic setup was performed to establish the final occlusion, specifically the final position and axial inclination of the upper and lower incisors, and at the same time to corroborate the feasibility of an SF approach (Figs. 1–3). This position was then used to plan the surgical movements of the maxilla and/or mandible^{12,16,17} according to the STO (Supplementary Fig. 1, online only and Figs. 4).

Surgery

Patients were operated on under general anaesthesia, except for mandible-only procedures, which were mostly carried out under local anaesthesia and sedation. In cases in which conventional orthodontic treatment was going to be used, bracket bonding was done 1 week before surgery, and a

Table 1
Inclusion and exclusion criteria for the surgery-first (SF) approach.

Variable	Inclusion criteria	Exclusion criteria
Patient	<ul style="list-style-type: none"> – Desire for an immediate aesthetic improvement – Treatment for sleep-related breathing disorder 	<ul style="list-style-type: none"> – Does not understand the protocol – Has unrealistic expectations
Treating team	<ul style="list-style-type: none"> – Agrees on a reduced treatment time protocol 	<ul style="list-style-type: none"> – Inexperienced in orthognathic surgery
Occlusal relations	<ul style="list-style-type: none"> – Minimal crowding of the anterior teeth, not requiring tooth extraction 	<ul style="list-style-type: none"> – Severe crowding requiring extractions – Class II second division malocclusion with an overbite – Very deep curve of Spee
Dentoalveolar Skeletal		<ul style="list-style-type: none"> – Asymmetrical dentoalveolar compensations – Maxillary transverse discrepancy of more than 6 mm – Severe asymmetries with 3D dental compensations
Others		<ul style="list-style-type: none"> – If applying SF protocol implies modifying the surgical plan – Periodontal disease (until treated) – Unstable temporomandibular joint disorder (until stabilised)

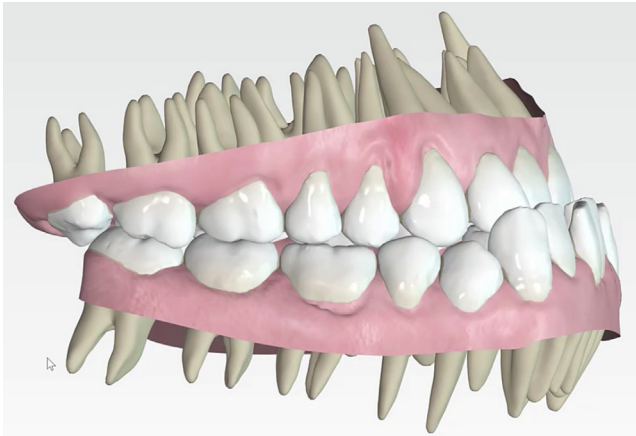


Fig. 1. Virtual orthodontic setup of a clinical case: preoperative situation.

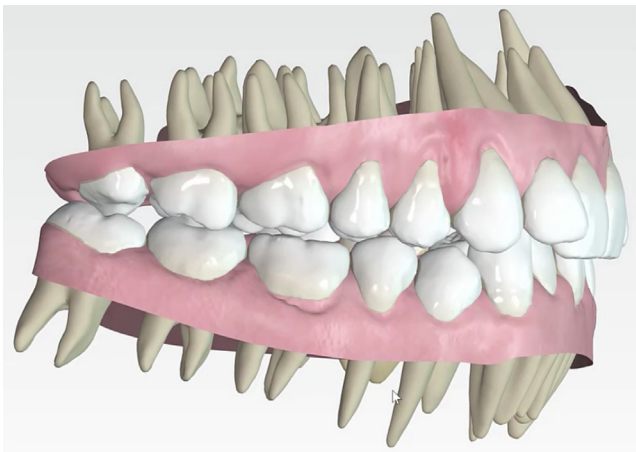


Fig. 2. Virtual orthodontic setup of a clinical case: postoperative situation. This “scenario” is used to design the final splint.

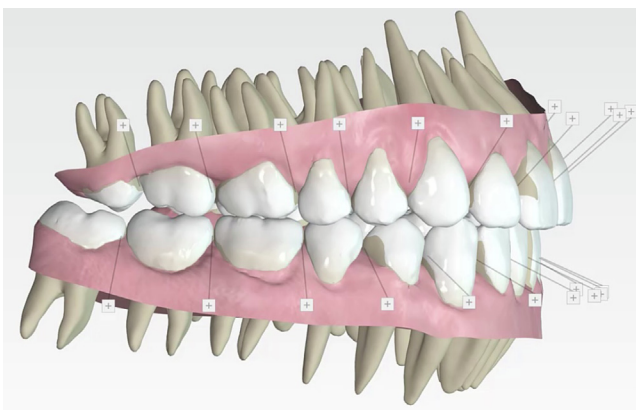


Fig. 3. Virtual orthodontic setup of a clinical case: anticipated final result after orthodontic treatment. This allows the surgeon to anticipate the final position of the upper incisor and plan the bimaxillary surgical movements accordingly.

nickel-titanium (NiTi) soft arch wire was placed the day before surgery. The first surgical step consisted of placing 4–8 transmucosal 2mm miniscrews for intermaxillary

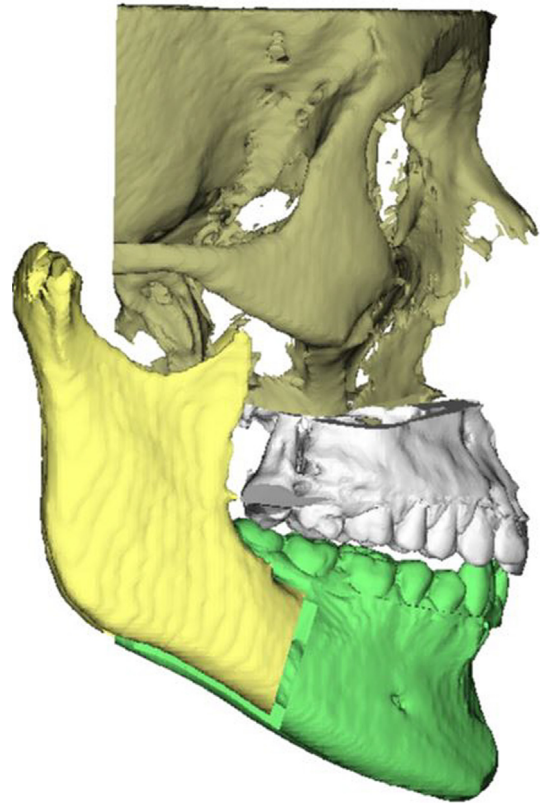


Fig. 4. Virtual surgical 3D planning of the same case: sagittal view of virtual bimaxillary surgery.

fixation with surgical splints in place, since hooks cannot be used with soft-arch wires and the Invisalign® system does not provide any anchorage.

Then, orthognathic surgery was performed following a mandible-first approach and using the conventional protocol of the surgical team, as further detailed elsewhere.^{18,19} In cases of anterior crowding, interdental corticotomies (osteotomies of the buccal cortex) were performed with a piezoelectric saw on the mandible and maxilla to further induce the previously stated RAP and SAP, and which would allow increased orthodontic management in this region postoperatively.⁹ Intermaxillary fixation miniscrews were left in place postoperatively for the use of light guiding elastics during the first month, and for skeletal orthodontic anchorage when needed. The final splint was left in place for 3 weeks after surgery only when a segmental maxillary osteotomy had been carried out.

Patients were referred to the orthodontist 2 weeks after surgery when there was enough mouth opening allowed treatment to begin.

Evaluation and statistical analysis

A descriptive analysis using SPSS for Windows (version 15.0.1, SPSS Inc) of the following compiled variables was performed: age; gender; main complaint (functional, aesthetic, or due to obstructive sleep apnoea-hypopnoea

syndrome); if the patient consulted with the orthodontist first or directly with the surgeon; initial class of occlusion, initial facial pattern; previous orthodontic treatments; type of orthodontic treatment (conventional stainless steel brackets, ceramic braces, lingual braces or Invisalign®); type of orthognathic surgery (maxillary, mandibular and/or chin) and complementary procedures; intraoperative and postoperative complications; and total treatment time (surgery + orthodontics). The overall degree of satisfaction of the patient, orthodontist, and surgeon at the end of the postoperative orthodontic treatment was also obtained. A visual analogue scale (VAS) ranging from 0 (not satisfied at all) to 10 (greatest possible satisfaction) was used, rating final facial appearance, occlusion, and how bearable the complete treatment was.

Results

A total of 148 orthognathic surgery procedures have been performed following an SF protocol during a 10-year period (between January 2010 and December 2019). It represents a 9.2% of our orthognathic surgeries. There were 89 females (60.1%) and 59 males (39.9%), with a mean (range) age of 28 (18–68) years (Table 2).

Whereas 61.5% of the patients (n = 91) were referred by their orthodontist, 38.5% (n = 57) were self-referred. The main chief complaint was functional occlusion (55.4%, n = 82)), followed by aesthetics (33.8%, n = 50)) and sleep-related breathing disorders (10.8%, n = 16). Every patient who had sought treatment due to sleep-related breathing disorders (16 cases) was able to discontinue use of a nocturnal continuous positive airway pressure (CPAP) device right after the surgery.

Table 2
Demographic data and main initial diagnosis.

Variable	Number (%)
Total number of patients:	148
Female	89 (60.1)
Male	59 (39.9)
Previous orthodontic treatment:	
Yes	59
No	89
Main initial dental-skeletal diagnosis:	
Class I:	13 (8.8)
Maxillary hypoplasia (bi-retrusion)	6 (46.2)
Maxillary hyperplasia (open bite)	6 (46.2)
Mandibular hyperplasia	1 (7.6)
Class II:	54 (36.5)
Vertical maxillary hyperplasia (long face)	15 (27.8)
Vertical maxillary hypoplasia (short face and bi-retrusion)	14 (25.9)
No vertical problems (mandibular hypoplasia)	25 (46.3)
Class III:	68 (45.9)
Vertical mandibular excess (long face)	20 (29.4)
Vertical maxillary deficiency (short face)	16 (23.5)
No vertical problems	32 (47.1)
Asymmetry	13 (8.8)

The initial dental-skeletal diagnosis of the sample is also summarised in Table 2, and types of orthodontic and orthognathic surgical treatments performed in Table 3, (online only). Additional concomitant ancillary or functional surgical procedures were performed in 89 patients (60.1%), which are specified in Table 4, (online only). The postoperative orthodontic treatment lasted an average of 36.8 weeks (range: 15–72 weeks). Finally, surgical complications and patient, surgeon, and orthodontist degree of satisfaction are compiled in Table 5, (online only).

Discussion

Since the beginning of using the SF approach, several refinements of the technique have been described regarding its indications and contraindications, virtual planning work-up, surgical tips and postoperative orthodontic benefits, which will be discussed below following a point-by-point format.

First, regarding patient selection, although after a reasonable learning curve of 10 years would apparently imply a broadening of the inclusion criteria, from our point of view these have been limited instead of increased. It is reflected in our SF/other-approach ratio, where surgeries following the SF protocol only represent 9.2% of all our orthognathic surgeries, whereas other centres report higher SF ratios (32.2% and 46.4%).^{20,21}

Some points of the inclusion and exclusion criteria (Table 1) require further explanation: (a) class II division 2 deep-bite patients are excluded because the negative torque of the upper incisors would limit the appropriate surgical mandibular advancement; (b) the concept of asymmetric dentoalveolar compensations refers to the presence of opposite torque of the posterior teeth on each side (curve of Wilson), which is present in most asymmetric jaws, and also in patients with an uneven posterior dentoalveolar height, which is typical of vertical asymmetries. So, we consider that any asymmetric dentoalveolar compensation is a red light for us, since it could condition a malposition of the skeletal base; (c) whenever the surgical plan differs from the one that would be designed in a conventional surgery-late scenario is another very relevant contraindication for our SF protocol. Examples would be the need to perform segmental surgery to compensate for transverse dentoalveolar torque problems or adding a genioplasty to compensate for a poor torque of the lower incisors, or the need to perform mandibular remodelling to compensate for posterior vertical dentoalveolar asymmetries; and (d) both periodontal disease (until treated) and unstable temporomandibular joint disorder (until stabilised) would be a contraindication for both SF as well as orthodontics first approach.

As for patient recruitment, the authors would like to highlight that patients are now more aware of their dentofacial anomalies thanks to the internet and social networks, and a consultation with the surgeon before the orthodontist is increasingly more common. Regarding specifically our self-referred patients (38.5%), 28 of them consulted for aesthetic reasons (49.1%), 7 for respiratory problems

(12.3%), and the remainder 38.6% for malocclusion problems. Also, referrals from pulmonologists of patients with sleep-related breathing disorders to evaluate the possibility of surgical treatment is becoming more common, as a result of the proven benefits of orthognathic surgery in these cases.²² Usually, patients looking for immediate aesthetic improvement are typically class III, whereas those looking for a quick solution to an underlying sleep disorder are class II patients.

In relation to the virtual surgical planning work-flow, virtual orthodontic setup inherent to Invisalign[®] system has proven really helpful for subsequent virtual surgical planning, since final relations and inclination of the incisors have been analysed previously and can be added to the virtual surgical planning, which increases final treatment accuracy. Needless to say, the SF approach implies a longer learning curve, since its management requires an abstract visualisation and prediction of the orthodontic objectives, which can be portrayed virtually, but not transferred to the patient until after surgery.

Some virtual surgical planning key points should be highlighted. In SF cases, it is of utmost importance to consider post-surgical anteroposterior changes in the position and inclination of upper and lower incisors. While the upper incisors guide the 3D repositioning of the maxillomandibular complex in class I patients, the lower incisors indicate the need for a genioplasty.

Interdental corticotomies are not systematically performed, since it has been proven that maxillary-mandibular osteotomies also cause RAP/SAP.⁹ Currently, they are solely performed in cases of anterior crowding to provide an increased orthodontic management of this region. Additionally, a mandibular front-block osteotomy is carried out for anterior dentoalveolar decompensation by tipping the anterior teeth labially in cases with negative torque and thin bone and gingival biotypes. Some authors leave the final splint in place for 4–6 weeks to improve postoperative stability.²³ However, our philosophy is that this should be minimised to take advantage of RAP/SAP-assisted orthodontic movements.²⁴

Table 4 (online only) shows the number and variety of additional concomitant ancillary or functional surgical procedures performed in 60.1% of the sample, which means that the orthognathic surgical procedure is not hindered or altered because of the SF approach. On the other hand, complications related to surgery were also reviewed (Table 5, online only), and when compared with those reported in the literature of the conventional ‘orthodontics before surgery’ approach, these resulted to be similar or even slightly less, which means that the SF approach is as safe as the conventional approach. The most frequent postoperative drawback was the requirement of hardware removal due to exposure (6.1%),²⁵ followed by inferior alveolar nerve damage (3.4%)²⁶ and early surgical site infection during the first postoperative month (2.7%).^{27,28} Regarding dental ischemic problems, there were only two cases (1.4%),²⁹ and both in cases of maxillary segmentation. Interestingly, neither of them received corticotomies.

Finally, our results show a mean duration of orthodontic treatment of 36.8 weeks, which is less than in the published literature at 56.3 weeks,^{3,6,7,13} and which is shortened compared to the conventional protocol that has a mean duration of 87.5 weeks.

Our patients’ degree of satisfaction following an SF approach was high (9/10), and what the patients highlighted the most was not having to go through a previous orthodontic treatment that entails a deterioration in QoL. The surgeon’s and orthodontists’ degree of satisfaction was absolute, except in cases where the orthodontist was inexperienced with orthognathic surgery. Therefore, the treating team’s training and experience, as well as a fluid dialogue between the two teams is of uppermost importance.

Last but not least, the long-term stability of the SF approach is still unclear,^{3,4,7,30} and a limitation of the present review is the lack of a postoperative stability analysis.

Conclusion

We can conclude that the SF approach provides relevant benefits and is suitable when patients meet the above-mentioned criteria. In our quest to achieve predictable results, we have broadened our exclusion criteria.

Acknowledgements

The authors would like to specially thank Steven Huang for his hard work, as well as to all the staff members at the Institute of Maxillofacial Surgery, Teknon Medical Centre (Barcelona), for their administrative and clinical support.

Conflict of interest

We have no conflicts of interest.

Ethics statement/confirmation of patients permission

Ethics approval was obtained from the local Ethics Review Committee at the Teknon Medical Centre (Barcelona, Spain). Patient written informed consent was provided to access the CBCTs database.

Appendix A. Supplementary material

Supplementary data to this article can be found online at <https://doi.org/10.1016/j.bjoms.2022.04.006>.

References

1. Nagasaka H, Sugawara J, Kawamura H, et al. “Surgery first” skeletal Class III correction using the Skeletal Anchorage System. *J Clin Orthod* 2009;43:97–105.
2. Choi JW, Lee JY, Yang SJ, et al. The reliability of a surgery-first orthognathic approach without presurgical orthodontic treatment for skeletal class III dentofacial deformity. *Ann Plast Surg* 2015;74:333–341.

3. Peiró-Guijarro MA, Guijarro-Martínez R, Hernández-Alfaro F. Surgery first in orthognathic surgery: a systematic review of the literature. *Am J Orthod Dentofacial Orthop* 2016;**149**:448–462.
4. Choi DS, Garagiola U, Kim SG. Current status of the surgery-first approach (part I): concepts and orthodontic protocol. *Maxillofac Plast Reconstr Surg* 2019;**41**:10.
5. Kwon TG, Han MD. Current status of the surgery-first approach (part II): precautions and complications. *Maxillofac Plast Reconstr Surg* 2019;**41**:23.
6. Huang CS, Chen YR. Orthodontic principles and guidelines for the surgery-first approach to orthognathic surgery. *Int J Oral Maxillofac Surg* 2015;**44**:1457–1462.
7. Yang L, Xiao YD, Liang YJ, et al. Does the surgery-first approach produce better outcomes in orthognathic surgery? A systematic review and meta-analysis. *J Oral Maxillofac Surg* 2017;**75**:2422–2429.
8. Strippoli J, Akin JJ. Accelerated tooth movement by alveolar corticotomy or piezocision. *Orthod Fr* 2012;**83**:155–164, paper in French.
9. Abe Y, Chiba M, Yaklai S, et al. Increase in bone metabolic markers and circulating osteoblast-lineage cells after orthognathic surgery. *Sci Rep* 2019;**9**:20106.
10. Liou EJ, Chen PH, Wang YC, et al. Surgery-first accelerated orthognathic surgery: postoperative rapid orthodontic tooth movement. *J Oral Maxillofac Surg* 2011;**69**:781–785.
11. Park JK, Choi JY, Yang IH, et al. Patient's satisfaction in skeletal class III Cases treated with two-jaw surgery using orthognathic quality of life questionnaire: conventional three-stage method versus surgery-first approach. *J Craniofac Surg* 2015;**26**:2086–2093.
12. Hernández-Alfaro F, Guijarro-Martínez R, Molina-Coral A, et al. "Surgery first" in bimaxillary orthognathic surgery. *J Oral Maxillofac Surg* 2011;**69**:201–207.
13. Hernández-Alfaro F, Guijarro-Martínez R, Peiró-Guijarro MA. Surgery first in orthognathic surgery: What have we learned? A comprehensive workflow based on 45 consecutive cases. *J Oral Maxillofac Surg* 2014;**72**:376–390.
14. Hernández-Alfaro F, Guijarro-Martínez R. On a definition of the appropriate timing for surgical intervention in orthognathic surgery. *Int J Oral Maxillofac Surg* 2014;**43**:846–855.
15. Hernández-Alfaro F, Guijarro-Martínez R. New protocol for three-dimensional surgical planning and CAD/CAM splint generation in orthognathic surgery: an in vitro and in vivo study. *Int J Oral Maxillofac Surg* 2013;**42**:1547–1556.
16. Hernandez-Alfaro F. Upper incisor to Soft Tissue Plane (UI-STP): a new reference for diagnosis and planning in dentofacial deformities. *Med Oral Patol Oral Cir Bucal* 2010;**15**:e779–e781.
17. Valls-Ontañón A, Ascencio-Padilla RDJ, Vela-Lasagabaster A, et al. Relevance of 3D virtual planning in predicting bony interferences between distal and proximal fragments after sagittal split osteotomy. *Int J Oral Maxillofac Surg* 2020;**49**:1020–1028.
18. Hernández-Alfaro F, Guijarro-Martínez R. "Twist technique" for pterygomaxillary dysjunction in minimally invasive Le Fort I osteotomy. *J Oral Maxillofac Surg* 2013;**71**:389–392.
19. Hernández-Alfaro F, Raffaini M, Paredes-de-Sousa-Gil A, et al. Three-dimensional analysis of long-term stability after bilateral sagittal split ramus osteotomy fixed with a single miniplate with 4 monocortical screws and 1 bicortical screw: a retrospective 2-center study. *J Oral Maxillofac Surg* 2017;**75**:1036–1045.
20. Hoang TA, Lee KC, Chuang SK. The surgery-first approach to orthognathic surgery. *J Craniofac Surg* 2021;**32**:e153–e156.
21. Jeong WS, Choi JW, Kim DY, et al. Can a surgery-first orthognathic approach reduce the total treatment time? *Int J Oral Maxillofac Surg* 2017;**46**:473–482.
22. Giralt-Hernando M, Valls-Ontañón A, Guijarro-Martínez R, et al. Impact of surgical maxillomandibular advancement upon pharyngeal airway volume and the apnoea–hypopnoea index in the treatment of obstructive sleep apnoea: systematic review and meta-analysis. *BMJ Open Respir Res* 2019;**6**:e000402.
23. Baek SH, Ahn HW, Kwon YH, et al. Surgery-first approach in skeletal class III malocclusion treated with 2-jaw surgery: evaluation of surgical movement and postoperative orthodontic treatment. *J Craniofac Surg* 2010;**21**:332–338.
24. Yuan H, Zhu X, Lu J, et al. Accelerated orthodontic tooth movement following Le Fort I osteotomy in a rodent model. *J Oral Maxillofac Surg* 2014;**72**:764–772.
25. Falter B, Schepers S, Vrielinck L, et al. Plate removal following orthognathic surgery. *Oral Surg Oral Med Oral Pathol Oral Radiol Endod* 2011;**112**:737–743.
26. Verweij JP, Mensink G, Fiocco M, et al. Incidence and recovery of neurosensory disturbances after bilateral sagittal split osteotomy in different age groups: a retrospective study of 263 patients. *Int J Oral Maxillofac Surg* 2016;**45**:898–903.
27. Posnick JC, Choi E, Chavda A. Surgical site infections following bimaxillary orthognathic, osseous genioplasty, and intranasal surgery: a retrospective cohort study. *J Oral Maxillofac Surg* 2017;**75**:584–595.
28. Davis CM, Gregoire CE, Steeves TW, et al. Prevalence of surgical site infections following orthognathic surgery: a retrospective cohort analysis. *J Oral Maxillofac Surg* 2016;**74**:1199–1206.
29. Lee UL, Lee EJ, Seo HY, et al. Prevalence and risk factors of tooth discolouration after orthognathic surgery: a retrospective study of 1455 patients. *Int J Oral Maxillofac Surg* 2016;**45**:1464–1470.
30. Soverina D, Gasparini G, Pelo S, et al. Skeletal stability in orthognathic surgery with the surgery first approach: a systematic review. *Int J Oral Maxillofac Surg* 2019;**48**:930–940.