



Contents lists available at ScienceDirect

Journal of Cranio-Maxillo-Facial Surgery

journal homepage: www.jcmfs.com

Review

Fat grafting in patients with cleft lip and palate: A systematic review

Orion L. Haas Junior ^{a,1,*}, Bibiana M. Rosa ^{a,1}, Navid Pourtaheri ^e,
 Raquel Guijarro-Martínez ^{c,d}, Adaia Valls-Ontañón ^b, Federico Hernández-Alfaro ^b,
 Rogério B. de Oliveira ^a, Derek M. Steinbacher ^e

^a Department of Oral and Maxillofacial Surgery, Pontifical University Catholic of Rio Grande do Sul and São Lucas Hospital of PUCRS, Porto Alegre, Brazil

^b Department of Oral and Maxillofacial Surgery, Universitat Internacional de Catalunya, Sant Cugat del Valle's and Institute of Maxillofacial Surgery, Teknon Medical Centre, Barcelona, Spain

^c Oral and Maxillofacial Surgeon, Private Practice, Valencia, Spain

^d Department of Orthodontics, Cardenal Herrera-CEU Universidad de Valencia, Valencia, Spain

^e Division of Plastic and Reconstructive Surgery, Department of Surgery, Yale School of Medicine, New Haven, CT, USA

ARTICLE INFO

Article history:

Paper received 21 February 2021

Received in revised form

17 November 2022

Accepted 28 January 2023

Available online xxx

Handling Editor: Prof. Emeka Nkenke

Keywords:

Cleft lip

Cleft palate

Oral fistula

Fat grafting

Systematic review

ABSTRACT

This systematic review aims to compare different fat-grafting techniques for cleft lip and palate repair. A search was conducted in PubMed, Embase, Cochrane Library, gray literature and reference lists of selected articles. A total of 25 articles were included, 12 on closure of palatal fistula and 13 on cleft lip repair. The rate of complete resolution of palatal fistula ranged from 88.6% to 100% in studies with no control group, whereas in comparative studies patients receiving a fat graft showed better outcomes than those not receiving a graft. Evidence suggests that fat grafting can be indicated for the primary and secondary repair of cleft palate, with good results. The use of dermis-fat grafts in lip repair was associated with gains in surface area (11.5%), vertical height (18.5%–27.1%), and lip projection (20%). Fat infiltration was associated with increased lip volume (6.5%), vermilion show (31.68% ± 24.03%), and lip projection (46.71% ± 31.3%). The available literature suggests that fat grafting is a promising autogenous option for palate and fistula repair and for improvement of lip projection and scar aesthetics in patients with cleft. However, to develop a guideline, further studies are needed to confirm whether one technique is superior to the other.

© 2023 European Association for Cranio-Maxillo-Facial Surgery. Published by Elsevier Ltd. All rights reserved.

1. Introduction

Primary repair for patients with cleft seeks to close the abnormal communication between the oral and nasal cavities and reconstruct the orbicularis oris muscle. However, the functional and aesthetic prognosis depends on the type of cleft, the technique employed, and the patient's age at the time of the procedure (Owusu et al., 2013; Zhang et al., 2014; Mapar et al., 2019; Smyth and Wu, 2019). In the long run, fistulas are not an uncommon complication, and many cases are left with a hypertrophic scar, wide philtrum, and short lip with poor projection (Mulliken et al.,

2003; Khosla et al., 2012; Zhang and Arneja, 2017; Campbell et al., 2019).

Fat grafting has been used for primary and secondary deformities of the lips because adipose tissue provides a plentiful source of stem cells and mitigates the inflammatory process while promoting healing with minimal fibrous tissue loading, thus improving the appearance of the scar as well as lip volume and contour. (Patel and Hall, 2004; Balkin et al., 2014; Wang et al., 2014; Emara and Tahseen, 2017; Zheng et al., 2020).

In palatoplasty, fat grafting has also been increasingly used to prevent or close fistulas, especially in patients with more complex clefts. The rationale is to cover the surfaces exposed by the flap and to provide additional vascularization in order to allow complete mucosal epithelization under less tension (Debnath, 2006; Levi et al., 2009; Gröbe et al., 2011; Horswell and Chou, 2019; Kim et al., 2020).

* Corresponding author. Hospital São Lucas da PUCRS, Avenida Ipiranga, 6690 office 816, Brazil.

E-mail address: olhj@hotmail.com (O.L. Haas Junior).

¹ Both authors contributed equally.

There is a vast literature on fat grafting in the treatment of cleft patients and several outcomes have been evaluated, but there is no comparison of these data to aid in the clinical management of patients or to help guide surgeons' decision-making. Therefore, this systematic review aims to compare different fat grafting techniques, summarizing and reporting functional and aesthetic outcomes.

2. Methods

The methods of this review followed the recommendations set forth in the Preferred Reporting Items for Systematic reviews and Meta-Analyses (PRISMA) Statement (Liberati et al., 2009). The PRISMA Checklist can be found in [Supplementary Material 1](#). A systematic search was conducted in 3 major databases (PubMed, Embase, and Cochrane Library) and the gray literature. A hand search of the reference lists of selected articles was also performed. The search queries were constructed using the PICO strategy (**Patient**: "cleft lip" or "cleft palate"; **Intervention**: "fat graft" or "transplants"; **Comparison**: no comparison; **Outcome**: "graft survival" or "graft rejection"), with no restrictions on language or date of publication.

3. Search strategy

The main search strategy used MeSH terms in MEDLINE (via PubMed) and the Cochrane Library. The Embase search query was based on Emtree terms and synonyms.

Works not indexed in major databases were accessed through Google Scholar (gray literature) with the same MeSH terms used in the main search strategy ([Supplementary Material 2](#)).

The reference lists of the included studies were hand searched for additional relevant publications.

4. Study selection and eligibility

Titles and abstracts were screened by 2 independent investigators (BMR and OLHJ) following 3 selection criteria: (1) Intervention study reporting outcomes of fat-grafting techniques in patients with cleft; (2) not a case report; and (3) not a literature review.

Full texts of potential studies for inclusion were retrieved even if selected by only one of the investigators. Inter-rater agreement was assessed using the kappa coefficient (κ).

The selected full-text articles were assessed by the same 2 independent investigators, and 3 eligibility criteria were applied: (1) Intervention study reporting outcomes of dermis-fat graft or fat infiltration techniques for lip repair or use of a fat-grafting technique on the palate for fistula treatment; (2) reports of aesthetic and/or postoperative functional data or data on treatment success rate and/or need for reintervention; and (3) an original study.

In case of disagreement between the raters, the article was discussed with a third investigator (DMS). All reasons for exclusion were recorded. Again, the kappa coefficient was used to assess inter-rater agreement.

5. Data extraction

The parameters of interest were demographic data, study methodology, aesthetic and functional outcomes in cleft lip repair, graft success/recurrence rate and function in cleft palate repair, and complications. In case of disagreement, the most experienced investigator (DMS) was asked to adjudicate. If doubts remained, the first author of the article in question was contacted.

5.1. Outcome analysis

In cleft lip repair, different techniques were reviewed and their respective morphological gains in surface area, volume, or length were compared. Data were expressed in mm and/or as percentages, or on satisfaction scales. The aesthetic parameters of interest were lip appearance and symmetry. Lip strength, speech articulation, or muscle behavior were analyzed using satisfaction or functional scales.

In cleft palate repair, the graft success rate was calculated as the number of patients who had complete resolution after the procedure, and was expressed as percentage. The functional parameter of interest was speech, measured on scales or dichotomously as absence vs. presence.

Graft stability was expressed in mm or as a percentage. The recurrence rate was expressed by the absolute and relative number of patients who experienced recurrence.

The complications reported for each technique were summarized.

6. Analysis of methodological quality

6.1. The parameters of interest for risk of bias assessment were: (1) sample randomization, (2) comparison between treatments, (3) blinded assessment, (4) validation of measures, (5) statistical analysis, (6) definition of inclusion and exclusion criteria, and (7) postoperative follow-up

Studies meeting all 7 criteria were considered to have a low risk of bias; 5 or 6 criteria, moderate risk; and 4 or fewer criteria, high risk.

7. Results

7.1. Search strategy

The main search was conducted on March 3, 2020, and the gray literature search, on March 18, 2020.

The main search yielded 1358 (PubMed), 2546 (Embase), and 42 (Cochrane Library) publications. After removal of duplicates, 3150 entries remained. A total of 11,100 articles were found in the gray literature.

7.2. Study selection and eligibility

The flowchart of study selection is shown in [Fig. 1](#).

Overall, 51 publications from the main search and 6 from the gray literature search were selected. The kappa coefficient was consistent with excellent agreement between investigators ($\kappa = 0.86$).

Of the 57 articles selected, 23 were included in the systematic review and 34 were excluded: 19 did not report outcomes of fat-grafting techniques for lip repair or oral fistula treatment; 12 did not report sufficient data on postoperative aesthetic and/or functional outcomes or treatment success rate; and 3 were not original articles. The kappa coefficient demonstrated perfect agreement between investigators ($\kappa = 1$). The final sample was composed of 25 articles: 21 obtained via the main search, 2 from the gray literature, and 2 through hand searching.

7.3. Demographic data

Studied on cleft lip repair evaluated a total of 426 patients and studies on cleft palate repair evaluated a total of 636 patients. Both

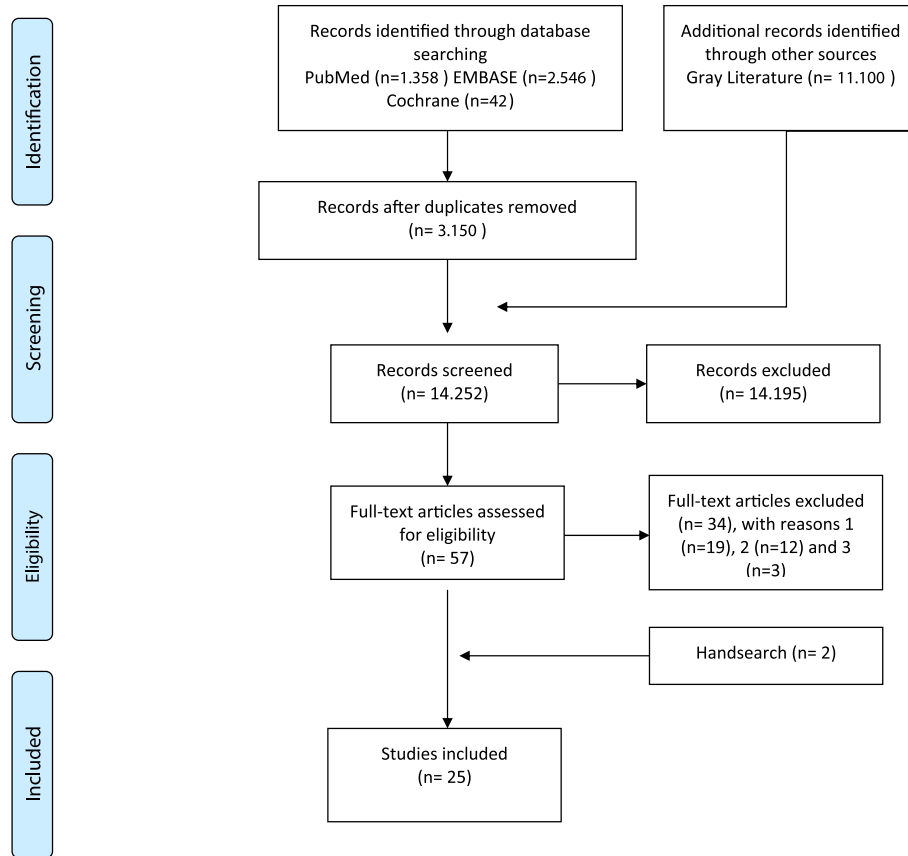


Fig. 1. Flowchart of the systematic review.

techniques were used to repair primary or secondary deformities (Table 1).

Supplementary Material 3 presents a classification of the level of evidence for each outcome analyzed.

7.4. Cleft lip repair with dermis–fat grafts

Five studies (Lee et al., 2012; Thomas et al., 2012; Abdali et al., 2017; Resnick et al., 2018; Schwaiger et al., 2019) involving 198 patients assessed dermis–fat grafts. Donor sites, graft preparation techniques, graft sizes, and cases of overcorrection are described in Table 2.

7.4.1. Outcome analyses

An 11.5% gain in surface area (0.31 mm^2 ; $p = 0.019$) was reported in one study (Resnick et al., 2018). Other studies found 27.11% improvement in vertical height (Thomas et al., 2012), 14.1% (1.14 mm; $p = 0.002$) improvement in lateral height (Resnick et al., 2018), 18.5% (1.30 mm; $p = 0.001$) improvement in midline height (Resnick et al., 2018), and 20% improvement in lateral projection (Thomas et al., 2012).

Gains in lip profile ranged from 80% with silicone, 40% with dermis–fat grafts, and 4% with lip revisions in patients with unilateral clefts to 104% with Abbé flaps, 39% with silicone, 30% with dermis–fat grafts, and 8% with lip revisions in patients with bilateral clefts ($p = 0.083$) (Schwaiger et al., 2019).

One study identified a postoperative complication (partial thickness loss) in 5 grafts (Lee et al., 2012).

7.5. Cleft lip repair with fat infiltration

Eight studies (Zellner et al., 2015; Bae et al., 2016; Baum et al., 2017; Jones et al., 2017; Akdag et al., 2018; Koonce et al., 2018; Alighieri et al., 2020; Zheng et al., 2020) involving 228 patients assessed fat infiltration. Donor sites, graft preparation techniques, graft volume, and cases of overcorrection are shown in Table 3.

7.5.1. Outcome analyses

A $1.16 \pm 0.32 \text{ mm}$ ($46.71 \pm 31.3\%$) increase in lip protrusion and a $0.77 \pm 0.19 \text{ mm}$ ($31.68 \pm 24.03\%$) increase in vermilion show were reported (Bae et al., 2016). Vermilion volume increased significantly from 0.87 mm^3 to 0.93 mm^3 (6.5%, $p = 0.001$) (Baum et al., 2017). The appearance of the vermilion border was considered significantly improved ($p = 0.02$) (Jones et al., 2017; Koonce et al., 2018; Zheng et al., 2020) (Zheng et al., 2020), ranging from 2.8 to 2.4 ($p = 0.048$) on the Asher-McDade scale in one study (Jones et al., 2017). Lip symmetry and nasolabial profile also improved significantly ($p = 0.007$ and $p = 0.04$ respectively) (Koonce et al., 2018; Zheng et al., 2020).

The fat resorption rate ranged from 30% to 80% (mean, 53%) (Baum et al., 2017). Complications included hematoma ($n = 1$), feeling of pressure at the donor site ($n = 4$), and recurrent lip pain ($n = 1$) (Baum et al., 2017).

7.6. Treatment of palatal fistula

Nine studies evaluated outcomes of primary repair (Debnath, 2006; Levi et al., 2009; Zhang et al., 2010 Gröbe et al., 2011; Yamaguchi et al., 2016; Horswell and Chou, 2019; Qiu et al., 2019;

Table 1
Demographic data analyses - y (years old); m (months); M (male); F (female).

Author, year and country	Type of study	Sample	Age	Gender	Technique	Method of analysis	Follow-up
Lee et al., 2012-Korea	Longitudinal prospective	91 (99 grafts)	21.6 y (5–57)	57 M/34 F	Composite grafts (skin + subcutaneous fat).	Visual analog scale	30.7 m (10–51)
Thomas et al., 2012-India	Longitudinal retrospective	10	26 y (18–30)	10 F	Composite graft (mastoid fascia + subcutaneous fat + dermis)	Digital photographs	12 m
Abdali et al., 2017-Iran	Longitudinal prospective	35	9 y (5–18)	21 M/14 F	Dermis fat graft	Photographs and upper lip motion	4 m
Resnick et al., 2018-USA	Longitudinal retrospective	25	10.9±3 y (8.5–18.7)	15 M/10 F	Dermis fat graft	Stereophotogrammetry	8.7 ± 6.27 m
Schwaiger et al., 2019-UK	Case control retrospective	37	23.8 y	17 M/20 F	Lip revisions: 15; Abbe flaps: 4; Dermal grafts: 12; Silicone implants: 6	Likert scale and digital photographs	11.9 m
Zellner et al., 2015-USA	Case control retrospective	35 (44 grafts)	4.9 ± 3.8 m (2–20)	13 M/22 F	Infiltration vs Control	Photographs	Control: 8.77 m; Fat: 8.71 m
Bae et al., 2016-Korea	Longitudinal retrospective	15	25 ± 9.41 y (17–55)	10 M/5 F	Infiltration	Photographs and questionnaire for patients, doctors and the general public.	6 m
Akdag et al., 2017-Turkey	Longitudinal prospective	20	21 y (18–25)	20 M	Infiltration	The Patient and Observer Scar Assessment Scale (POSAS)	12 m
Baum et al. (2017) - Germany	Longitudinal prospective	15 (17 grafts)	21 y (15–70)	1 M/14 F	Infiltration	Photographs and questionnaire for patient and surgeon	19 m (6–48), Outcomes: 6 m
Jones et al., 2017-USA	Longitudinal retrospective	18	16.1 y (6–43)	5 M/13 F	Infiltration	Photographs and patient satisfaction questionnaire	11.7 m
Koonce et al. (2018) - USA	Case control retrospective	52	7 y (2–16)	35 M/17 F	Infiltration vs Control	Photographs	24 m (9–72)
Alighieri et al., 2019 - Belgium	Longitudinal retrospective	8	19 y (14–24)	5 M/3 F	Infiltration	Clinical analysis and questionnaire	1.84 m (1.38–3.45)
Zheng et al. (2020) - China	Longitudinal prospective	65	25 y (22–41)	26 M/39 F	Infiltration	Photographs	17 m
Fat-grafting in cleft palate repair							
Debnath et al., 2006 India	Case control prospective	30 (Fat: 15)	1–18 y Fat: 5.45 y	15 M/15 F Fat: 6 M/9 F	Fat grafting in primary palatoplasty vs. Control	<i>Pain: Visual Analogue Scale (Faces Scale); Scar contracture and occurrence of palatal fistulae: photographs</i>	6 m
Levi et al., 2009 USA	Case series	14	11 m–15 y (38.2 m)	–	Fat grafting in primary and secondary palatoplasty	Clinical evaluation	3 m
Zhang et al., 2010 China	Case series	8	19–46 m (29.6 m)	6 M/2 F	Fat grafting in primary palatoplasty	Clinical evaluation	6 m
Ashtiani et al., 2011 Iran	Case series	29	2.5–19 y (9.3 y)	18 M/11 F	Fat grafting in secondary palatoplasty	Clinical evaluation	28 m
Gröbe et al., 2011 Germany	Case series	24	6 m–17 y (4.7 y)	8 M/16 F	Fat grafting in primary and secondary palatoplasty	Clinical evaluation	12 m
Yamaguchi et al., 2016 Taiwan	Longitudinal Retrospective	231 (Speech: 127)	8.3 ± 1.7 m (Speech evaluation: 47.6 ± 15.0 m)	104 M/127 F	Fat grafting in primary palatoplasty	Clinical evaluation; <i>Speech evaluation: perceptual assessment and nasopharyngoscopy</i>	30.3 ± 20.5 m (Speech: 39.1 ± 15 m)
Adeyemo et al., 2019 Nigeria	Case series	8	1–26 y (6.1 ± 8.6 y)	4 M/4 F	Fat grafting in primary and secondary palatoplasty	Clinical evaluation	1 m
Qiu et al., 2019 USA	Case series	7	11 m – 7 y9m (4.4 y)	–	Fat grafting in primary and secondary palatoplasty	Clinical evaluation	16 m
Horswell et al., 2019 USA	Case control retrospective	114	13.1 ± 6.6 m Control: 12.1 ± 7.2 m	63 M/51 F	Fat grafting in primary palatoplasty with modification: 65 Fat grafting in standard primary palatoplasty (control): 49	Clinical evaluation	6 m

Table 1 (continued)

Author, year and country	Type of study	Sample	Age	Gender	Technique	Method of analysis	Follow-up
Saralaya et al.,2019 India	Case control retrospective	62 (Fat: 11)	6 m–25 y	35 M/27 F	Tongue flap: 15 Redo Palatoplasty: 17 Rotation Flap: 19 Fat grafting + Rotation Flap: 11	Clinical evaluation	–
Denadai et al.,2019 Taiwan	Case control retrospective	44	20.4 ± 9.7 y	19 M/25 F	Local flaps with interpositional grafting (fascia or dermofat grafting): 23 Tongue flap: 21 Fat grafting in primary palatoplasty vs. Control	Clinical evaluation Pittsburgh fistula classification	6 m–14 y (5.1 ± 3.3 y)
Kim et al.,2020 Korea	Case control retrospective	65 (Fat: 36)	7 m - 30 y (39 m)	36 M/29 F Fat: 23 M/13 F	Fat grafting in primary palatoplasty vs. Control	Photographs and clinical evaluation	1 m

Adeyemo et al., 2019; Kim et al., 2020) and 7 reported outcomes of secondary repair (Levi et al., 2009; Ashtiani et al., 2011; Gröbe et al., 2011; Adeyemo et al., 2019; Denadai et al., 2019; Qiu et al., 2019; Saralaya et al., 2019). The most common graft donor site was the buccal fat pad (BFP): 11 of 12 included studies used this technique.

7.6.1. Outcome analyses

The rate of complete resolution of the fistula ranged from 88.6% (Horswell and Chou, 2019) to 100% (Levi et al., 2009; Zhang et al., 2010; Ashtiani et al., 2011; Gröbe et al., 2011; Adeyemo et al., 2019; Qiu et al., 2019) in studies with no comparison group. When compared, patients receiving a fat graft showed better outcomes (93.34% and 100%) than those not receiving a graft (80% and 86.2%) (Debnath, 2006; Denadai et al., 2019).

The combination of rotation flap with BFP was inferior (54.6% resolution) to either tongue flap (73.3%) or rotation flap alone (73.6%), but superior to redo palatoplasty (52.9%) (Saralaya et al., 2019). Another study also showed superiority of the tongue flap technique (100%) over dermal fat grafts (87%) (Denadai et al., 2019).

Among patients who received a graft, whether alone or combined with other repair techniques, 23 relapses were reported in the included studies (4.25% of the total sample) (Debnath, 2006; Denadai et al., 2019; Horswell and Chou, 2019; Saralaya et al., 2019).

Complications included bleeding (n = 3) (Debnath, 2006; Yamaguchi et al., 2016), necrosis (n = 1) (Debnath, 2006; Yamaguchi et al., 2016), infection (n = 1) (Yamaguchi et al., 2016), airway obstruction (n = 1) (Yamaguchi et al., 2016), obstructive sleep apnea (n = 1) (Yamaguchi et al., 2016), distal uvula dehiscence (n = 2) (Yamaguchi et al., 2016), partial flap dehiscence (n = 1) (Denadai et al., 2019), and superficial desquamation of the oral mucosa (n = 3) (Denadai et al., 2019) (Table 4).

7.7. Methodological quality

The analysis of methodological quality can be found in Supplementary Material 4.

Four lip repair studies (Zellner et al., 2015; Koonce et al., 2018; Resnick et al., 2018; Alighieri et al., 2020) were classified as having moderate risk of bias, and the remaining 9 studies (Lee et al., 2012; Thomas et al., 2012; Bae et al., 2016; Abdali et al., 2017; Baum et al., 2017; Jones et al., 2017; Akdag et al., 2018; Schwaiger et al., 2019; Zheng et al., 2020) as having a high risk of bias.

Eleven cleft palate studies were considered to have a high risk of bias (Levi et al., 2009; Zhang et al., 2010; Ashtiani et al., 2011; Gröbe et al., 2011; Yamaguchi et al., 2016; Adeyemo et al., 2019; Denadai et al., 2019; Horswell and Chou, 2019; Qiu et al., 2019; Saralaya et al., 2019; Kim et al., 2020). Only one article — the only

randomized study — was classified as having low risk of bias (Debnath, 2006).

8. Discussion

The studies included in this systematic review reported surgical outcomes for patients of all age groups, but only Zellner et al. presented a sample of patients in which fat infiltration was used for primary repair of cleft lip in infants, with significant improvements in lip morphology and aesthetics (Thomas et al., 2013; Zellner et al., 2015). Adipose tissue has angiogenic potential, promotes granulation and re-epithelialization and attenuates inflammation. In infants, these cellular capabilities are even greater, thus making fat grafting an excellent strategy to reduce tissue tension without impairing the healing process (Balkin et al., 2014; Idone et al., 2015; Zellner et al., 2015), and thus decreasing the nasolabial deformity that would normally develop during growth. However, it remains an infrequently used technique and secondary procedures for correction of lip aesthetics are more common.

Lip revisions using Abbé flaps, dermal grafts and silicone implants were compared by Schwaiger et al., who found that Abbé flaps provide greater lip projection in bilateral clefts, where lip deformity is greater; however, there is a need for a 2-stage procedure and scar formation on the lower lip (Schwaiger et al., 2019; Veeramani et al., 2020). Dermis-fat grafts are a good choice to avoid lower lip scar and to increase upper lip vermilion show, and this technique is also easier to adapt to the defect and readily correct asymmetries (Schwaiger et al., 2019).

Several fat grafting techniques have been reported for aesthetic correction during lip revision, all with the ability to optimize volume and provide a natural appearance. Comparison of different techniques showed an 11.5% increase in lip surface area with dermis-fat grafts (Resnick et al., 2018) and a 6.5% gain in volume with fat infiltration (Baum et al., 2017). Positive changes in vermilion show ranged from 18.5% (Resnick et al., 2018) to 27.11% (Thomas et al., 2012) with dermis-fat grafts and 31.68% with fat infiltration (Bae et al., 2016). The increase in lip projection reached 20% with dermis-fat grafts (Thomas et al., 2012) and up to 46.71% after fat infiltration (Bae et al., 2016). Regarding functional outcomes, Alighieri et al. analyzed lip strength and found no statistically significant difference after fat infiltration (Alighieri et al., 2019).

Graft stability is still considered uncertain in lip repair, but some parameters associated with outcome predictability could be analyzed in the present review, such as the greater rate of fat resorption in the first postoperative month, ceasing after 1 year (Zheng et al., 2020). This phenomenon is clearly demonstrated by

Table 2

Dermis-fat graft in cleft lip repair: detailed information about sample, graft and outcomes are presented - U (Unilateral cleft); B (bilateral cleft); I (incomplete cleft); C (complete cleft); mm (millimeters).

Study Derma graft	Cleft	Donor site	Graft prepare	Graft size	Extra Graft	Surface/Volume	Length/Height	Others outcomes	Stability	Complications
Lee et al. (2012) - Korea	–	Preauricular: 30 Suprabrow: 34 Chin: 7 Postauricular: 28	–	Width: 6.6 ± 2.7 mm (3 –12) Length: 13.7 ± 6.7 mm(4 –35)	8 cases	–	–	Scar change: 8.3 ± 1.7 Morphologic change: 8.2 ± 1.5	–	Thickness loss in 5 grafts
Thomas et al. (2012) - India	U: 7 B: 3	Postauricular	Deepithelialization, harvested as a single layer (ellipse) and kept in saline-soaked gauze.	10–15% extra	All cases 10/ 15%	–	Height 1 m: 46.53% (2.7 mm) 1 y: 27.11% Length 1 m: 30.48% (1.8 mm) 1 y: 20%	–	Height: 12.81% (–1.1 mm) Length: 9.75% (–0.7 mm)	–
Abdali et al. (2017) - Iran	U: 7 B: 23 C: 32 I: 3	Groin area	Deepithelialization and harvested. Subcutaneous fat excess was trimmed off.	Lip defect dependent	All cases	–	–	Satisfaction Excellent: 18 (51.42%) Good: 10 (28.57%) Intermediate: 7 (20%)	–	–
Resnick et al. (2018) - USA	UI: 4 UC: 10, BC: 11	Posterior iliac	Deepithelialization, harvested and kept in a saline-soaked sponge	Dermal thickness: 2.6 ± 0.4 mm	–	Surface: +11.5% (0.31 mm ²)	Lateral height: 14.1% (1.14 mm) Midline height: 18.5% (1.30 mm)	–	–	–
Schwaiger et al. (2019) - UK	U: 21 B: 16	–	–	–	–	–	U:Length-subjective Silicone: +3.29 Dermal graft: +2.54 Lip revision: +1.36 Length-objective Silicone: 80% Dermal graft: 40% Lip revision: 4% Upper vermilion height-subjective Silicone: +2.5 Dermal graft: +2.41 Lip revision: +1.36 Upper vermilion height-objective Dermal graft > PermaLip B: Length-subjective Abbe flap: +3.32 Silicone: +2.39 Dermal graft: +1.81 Lip revision: +1.20 Length-objective Abbe flap: 1.0:2.04 (104%) Silicone: 1.0:1.39 (39%) Dermal graft: 1.0:1.30 (30%) Lip revision: 1.0:1.08 (8%) Upper vermilion height-subjective Abbe flap: +3.46 Dermal graft: +2.00 Silicone: +1.50 Lip revision: +1.23	U: Symmetry-subjective Lip revision: +2.91 Silicone: +2.01 Dermal graft: +1.97 Symmetry-objective Lip revision: pre 22%/post 9% Dermal graft: pre 11%/post 12% Silicone: pre 19%/post 15% B: Symmetry-subjective Abbe flap: +3.46 Dermal graft: +2.10 Lip revision: +1.89 Silicone: +1.39 Symmetry-objective Abbe flap: pre 24%/post 7% Lip revision: pre 20%/post 8%	–	–

the loss of lip height (approximately 12.81%) and lip projection (approximately 9.75%) between 1-month and 1-year follow-up with the use of dermis-fat grafts ([Thomas et al., 2012](#)): Fat resorption at 1 year with the infiltration technique ranged from 30% to 80% (mean, 53%) ([Baum et al., 2017](#)). Although important, graft

stability outcomes were reported only in a few studies. To circumvent the unpredictability of fat resorption, some authors used an overcorrection strategy ([Thomas et al., 2012](#); [Abdali et al., 2017](#); [Baum et al., 2017](#); [Zheng et al., 2020](#)). Those who did not,

Table 3
Fat infiltration in cleft lip repair: detailed information about sample, graft and outcomes are presented - U (Unilateral cleft); B (bilateral cleft); I (incomplete cleft); C (complete cleft); mL (milliliters); rpm (rotations per minute); mm (millimeters); POSAS (Patient and Observer Scar Assessment Scale).

Study Graft infiltration	Cleft	Donor site	Graft prepare	Graft volume	Extra Graft	Surface/Volume	Length/Height	Others outcomes	Stability	Complications
Zellner et al. (2015) - USA	U: 26 B: 9	Medial thigh	Processed by Telfa rolling.	1.4 mL (0.5–2)	–	–	–	Residual cleft-related facial stigmata (appearance) Face Upper Lip Control: 2.85 ± 0.66 Control: 2.89 ± 0.66 Fat Grafting: 2.20 ± 0.77 Fat Grafting: 2.11 ± 0.72 Difference: 0.65. Difference: 0.79 Nose Midface Control: 2.80 ± 0.96 Control: 2.70 ± 0.70 Fat Grafting: 2.29 ± 0.84 Fat Grafting: 2.18 ± 0.69 Difference: 0.51 Difference: 0.52 Analysis by Asher-McDade Scale (appearance) Vermilion border Pre: 2.8/ Post: 2.4 Patient Satisfaction <i>How happy were you with your appearance before you received fat injections?</i> 3.2 <i>How happy are you with your appearance after you received fat injections?</i> 4.0 <i>How would you rate your recovery?</i> 4.3 <i>How did getting fat injections compare to your other surgeries?</i> 3.9 <i>Would you do it again?</i> 11 (yes)/0 (no) Satisfaction Patient: 3.8(3–5) Surgeon: 3.91(3.4–4.6) Layperson: 4.03(3.2–4.8)	–	–
	I: 19 C: 17									
Jones et al. 2016 - USA	U: 10 B: 8	Infraumbilical	Decanted onto a Telfa pad, then gently rolled back and forth to allow the oil to be absorbed.	–	Revision Once: 1	–	–		–	–
Bae et al. (2016) - Korea	–	Abdominal	Coleman technique	11.9 ± 4.6 mL (6.3–22.5)	–	–	Vermilion Height 0.77 ± 0.19 (31.68 ± 24.03%) Length 1.16 ± 0.32 (46.71 ± 31.3%)		–	–
Akdag et al. 2017 - Turkey	U: 8 B: 12	Periumbilical	Coleman technique	1–2 mL	–	–	–	POSAS Before fat graft: 6.7 Before hair transplantation: 5.3 After moustache transplantation: 3.2	–	–
Baum et al. (2017) - Germany	UC: 15	Periumbilical	Sedimentation for 15 min, free fat was used.	2.2 mL (0.7–4 mL)	All patients: 30 –40% Revision Twice: 2	Volume +6.5%	Length (pre-post): 0.87–0.93 mm	Not fully satisfied: 3(20%)	Resorption: 30 –80% (53%) >50%: 13 Revision necessity: 3	Hematoma: 1(7%) Periumbilical: 4(27%) Recurrent pain: 1(7%)
Koonce et al. (2018) - USA	U: 41 B: 11	Thighs, abdomen or buttocks	Centrifuge at 3100 rpm for 5 min, free fat was used	3 mL (2–5)	–	–	–	Symmetry and aesthetics (pre vs. post) Vermillion border: p = 0.02 Symmetry: p = 0.007 Nasal-labial profile: p = 0.04 Fat-grafted patients vs. non-fat-grafted patients Vermillion border: 3.1:4.17 Symmetry: 2.4:4.38 Nasal-labial profile: 3:4.21	–	–
Alighieri et al., 2019 - Belgium	U: 7 B: 1	Inner knees	Coleman technique	20–40 mL	–	–	–	Lip/tongue strength: no significance (p > 0.05) Cleft Evaluation Profile: pre: 4/ post: 3 Articulatory assessment: for none of the bilabials and labiodental consonants, no significance (p > 0.05) Orofacial myofunctional behavior: no significance (p > 0.05).	–	–
Zheng et al. (2020) - China	UI: 13 B: 52	Thighs, abdomen or buttocks	Decanted onto a gauze, then gently rolled back and forth to absorb the oil	1.5 mL (1–2)	All patients: 0.5 mL Revision Once: 23 Twice: 27 3 times: 15	–	–	Symmetry and aesthetics Vermillion border: 3.1:4.17 Symmetry of lip: 2.4:4.38 Nasal-labial: 3:4.21	–	–

Table 4
Fat-grafting in cleft palate repair: detailed information about sample, graft and outcomes – UCLP (Unilateral Cleft Lip and Palate); CP (Cleft Palate); BCLP (Bilateral Cleft Lip and Palate); BCCP (Bilateral Complete Cleft Palate); SMCP (Submucous Cleft Palate); ICP (Incomplete Cleft Palate); CHOP (Children’s Hospital of Philadelphia); VPI (velopharyngeal insufficiency); BFP (buccal fat pad); mm (millimeters).

Study	Fistula	Donor site	Graft size	Cleft preop	Cleft postop	Speech analysis	Recurrence	Complications
Debnath et al., 2006 - India	Fat: UCLP: 11; CP: 2; BCLP: 2 Buccal fat pad		Bilateral BFP	–	Closed: 26(86.66%) Fat: 14(93.34%), Control: 12(80%)	-	Fat: 1(6.66%) Control: 3(20%)	Fat: Bleeding: 1(6.66%); Necrosis: 1(6.66%)
Levi et al. (2009) - USA	Primary CP repair: Unilateral:3; Bilateral:7 Fistula repair Junctional: 1; Anterior: 1; Bilateral: 1; Oroantral: 1	Buccal fat pad	Bilateral BFP	–	Closed: 14(100%)	–	–	-
Zhang et al. (2010) - China	BCCP: 14	Buccal fat pad	Unilateral BFP	Maximum cleft width 13–18 mm(15.3 mm)	Closed: 8 (100%)	–	–	-
Ashtiani et al. (2011) - Iran	Middle hard palate:8 Posterior hard palate:8 Soft palate: 13	Buccal fat pad	–	Medio-lateral: 5–15 mm (9.5 mm) Antero-posterior: 10–20 mm(14.7 mm)	Closed: 29(100%)	–	–	–
Gröbe et al. (2011) - Germany	Primary CP repair: 12 Fistula repair: 12	Buccal fat pad	Bilateral BFP	Maximum size (adults): 4 × 4 × 3cm Maximum size (infants): 2 × 2 × 1cm	Closed: 24(100%)	–	–	–
Yamaguchi et al.,2016 - Taiwan	Veau class I: 47 Veau class II: 52 Veau class III: 83 Veau class IV: 49	Buccal fat pad	Bilateral BFP	–	Closed 230(99.56%)	<i>Adequate</i> 110 (86.6%) <i>Marginal</i> 10 (7.9%) <i>Inadequate</i> 7 (5.5%)	1 (0.4%)	Bleeding: 2(0.8%); Airway obstruction: 1(0.4%); Obstructive sleep apnea: 1(0.4%); Stitch abscess: 1(0.4%); Distal uvula dehiscence: 2(0.8%)
Adeyemo et al. (2019) - Nigeria	Primary CP repair: Hard and soft palate cleft: 5 Fistula repair Soft palatal cleft: 1; Hard and soft palate cleft: 2	Buccal fat pad	–	-	Closed: 8(100%)	–	–	–
Qiu et al. (2019) - USA	Primary CP repair CP: 1; SMCP: 2 Fistula repair UCLP: 1 Residual VPI UCLP: 2; SMCP: 1	Buccal fat pad	Bilateral BFP: 3 Unilateral BFP: 4	-	Closed: 7(100%)	–	–	–
Horswell et al., 2019 - USA	BCLP: 7; UCLP: 18; CP: 40 Control: BCLP: 9; UCLP: 12; CP: 28	Buccal fat pad	Bilateral BFP	-	Closed: 88.6% Standard Furlow: 38(77.6%) <i>Furlow with CHOP Modification:</i> 63(97%)	–	2(3%) Control: 11(22.4%)	Hemi-flap dehiscence: 1 Superficial slough of the oral mucosal layer: 3
Saralaya et al. (2019) - India	Soft palate and uvulae: 2 Posterior and mid palate: 29 Anterior hard palate: 31	Buccal fat pad	–	Longitudinal: 25.8%(n = 16) Transverse: 74.2%(n = 46)	Closed: Tongue flap: 11(73.3%) Redo Palatoplasty: 9(52.9%) Rotation Flap: 14(73.6%) BFP + Rotation Flap: 6(54.6%)	–	22(35.4%) Fat: 5(45.4%)	–
Denadai et al. (2019) - Taiwan	Type V: 17; Type VI: 6; Type VII: 4; Combined types: 17 Graft: Type V: 13; Type VI: 6; Type VII: 4	Mastoid fascia: 2 Groin dermofat: 2 Gluteal dermofat: 19	–	Small(<2 mm): 9(20; 5%); Medium(2.5 mm): 14(31.8%); Large(>5 mm): 21(47.7%) Graft: Small: 9; Medium: 14	Closed: 41(93.2%) Fat: 20(87%) Tongue: 21(100%)	–	3(6.8%) Fat: 3(13%)	–
Kim et al. (2020) - Korea	ICP: 21; UCLP: 38; BCLP: 6 Fat ICP: 15; UCLP: 15; BCLP: 6	BFP	Bilateral BFP	Ratio of cleft width: Fat: 0.328 ± 0.081 Control: 0.329 ± 0.106	Closed: 61(93.85%) Fat: 36(100%) Control: 25(86.2%)	-	Control 4(13.8%)	–

such as Jones et al., concluded that even minor overcorrection would help ensure consistency in the results (Jones et al., 2017).

The available literature suggests that both dermis-fat grafts and fat infiltration are promising autogenous options for improvement of lip projection and scar aesthetics. However, to develop a safe and definitive guideline for this type of treatment, further studies are needed to confirm whether one technique is superior to the other. Researchers should focus on conducting randomized clinical trials with blinded evaluators to compare fat grafting with synthetic materials and, especially, to compare different fat grafting techniques (dermis-fat vs. infiltration).

Regarding closure of palatal fistula, successful palatoplasty means avoiding potential negative repercussions on speech, swallowing, or dentofacial development (Horswell and Chou, 2019; Saralaya et al., 2019; Smyth and Wu, 2019; Hu et al., 2020). High success rates were found in the included publications; 6 studies reported 100% success (Levi et al., 2009; Zhang et al., 2010; Gröbe et al., 2011; Adeyemo et al., 2019; Qiu et al., 2019; Kim et al., 2020). The highest recurrence rate was 11.4%, reported by Horswell and Chou, but this still means that 88.6% of cases resolved permanently (Horswell and Chou, 2019), which can be considered a good outcome. Two comparative studies showed a higher incidence of postoperative fistulas (failure) in the groups that did not receive a graft (Debnath, 2006; Kim et al., 2020), due to healing by secondary intention. BFP was the donor site used in all studies of primary palatoplasty, because this anatomical region is easily accessible via a simple surgical technique and is not associated with increased morbidity or operative time (Levi et al., 2009; Zhang et al., 2010; Gröbe et al., 2011; Adeyemo et al., 2019; Horswell and Chou, 2019; Kim et al., 2020).

BFP was also used in secondary repair. In 5 studies, the rate of complete resolution of the fistula was 100% (Zhang et al., 2010; Ashtiani et al., 2011; Gröbe et al., 2011; Qiu et al., 2019; Adeyemo et al., 2019). However, Saralaya et al. reported better success rates with a tongue flap (73.3%) or a rotation flap (73.6%) than with a BFP graft plus rotation flap (54.6%) or redo palatoplasty (52.9%) (Saralaya et al., 2019). Only one study in this category did not use BFP as the graft donor site (Denadai et al., 2019), the authors used local flaps with an interpositional graft from the mastoid fascia or a groin/gluteal dermofat graft and achieved an 87% rate of resolution of anterior palatal fistula, which is particularly difficult to repair due to the small amount of healthy tissue available, in addition to the proximity to the teeth. The authors noted that all relapses in their sample (13%) occurred in moderately large to large fistulas, and that the grafts were probably too thin for these cases.

Yamaguchi et al. (2016) reported that 86.6% of patients had adequate speech in the long term after primary repair using a BFP graft. While the dysfunctions caused by the fistula may be satisfactorily addressed during the repair procedure it is pertinent to consider that further intervention may be necessary if the patient has some degree of velopharyngeal insufficiency (Hu et al., 2020).

In the present systematic review, the overall rate of fistula recurrence after palatoplasty was approximately 7.5% considering the varying follow-up periods of the included studies. This is a satisfactory finding, as there was considerable variation in fistula diameter and in the amount of fat grafted across studies. Therefore, the optimal graft volume depends greatly on the surgeon's experience, and does not appear to be a problem in view of the low rate of recurrence.

Reported surgical complications were minimal, which is consistent with the safety record of autologous techniques, with minimal morbidity at the donor site. Conversely, biomaterials are costly and associated with increased odds of rejection or infection, and so should only be indicated as a second-line option (Niechajew, 2000; Patel and Hall, 2004; Coleman, 2006). It bears stressing that

the prevention of complications involves multiple factors, such as operative technique and intraoperative and postoperative care; nevertheless, the absence of cases of infection or rejection when using autologous material is remarkable.

Considering the high success rates summarized here, it can be inferred from the findings that the use of fat grafting in primary palatoplasty is recommended to reduce the odds of recurrence and the need for secondary repair. In primary cases, BFP grafts are technically straightforward and safe. For secondary repair, fat grafting improves the quality of the fibrous tissue in the wound bed, increasing the likelihood of defect closure. When tissue availability is limited, fat-grafting techniques can be used to cover exposed surfaces and thus ensure better outcomes.

The main advantages of fat grafting include its autogenous nature, low morbidity, zero cost to the patient, and excellent safety profile. The optimal management strategy should be guided by interpretation of evidence in conjunction with individual clinical findings, such as the patient's degree of deformity, age, expectations, and goals.

9. Conclusion

The available literature suggests that fat grafting is a promising autogenous option for palate and fistula repair and for improvement of lip projection and scar aesthetics in patients with cleft. However, to develop a guideline, further studies are needed to confirm whether one technique is superior to the other.

Ethical approval

Not required.

Funding

None declared.

Registration

This systematic review was not registered.

Declaration of competing interest

The authors declare that they have no known competing financial interests or personal relationships that could have appeared to influence the work reported in this paper.

Appendix A. Supplementary data

Supplementary data to this article can be found online at <https://doi.org/10.1016/j.jcms.2023.01.019>.

References

- Abdali, H., Kachuee, A.A.A., Mohammadi-Mofrad, R., Houghoughi, M.A., Esmalian-Ayouni, N., 2017. Surgical correction of upper lip deficit in patients with cleft lip using dermis fat graft. *J. Res. Med. Sci.* https://doi.org/10.4103/jrms.JRMS_994_15.
- Adeyemo, W.L., Ibikunle, A.A., James, O., Taiwo, O.A., 2019. Buccal fat pad: a useful adjunct flap in cleft palate repair. *J. Maxillofac. Oral Surg.* 18, 40–45. <https://doi.org/10.1007/s12663-018-1100-9>.
- Akdag, O., Evin, N., Karamese, M., Tosun, Z., 2018. Camouflaging cleft lip scar using follicular unit extraction hair transplantation combined with autologous fat grafting. *Plast. Reconstr. Surg.* 141, 148–151. <https://doi.org/10.1097/PRS.0000000000003956>.
- Alighieri, C., Bettens, K., Roche, N., Bruneel, L., Van Lierde, K., 2020. Lipofilling in patients with a cleft lip (and palate) – a pilot study assessing functional outcomes and patients' satisfaction with appearance. *Int. J. Pediatr. Otorhinolaryngol.* 128, 109692. <https://doi.org/10.1016/j.ijporl.2019.109692>.

- Ashtiani, A.K., Bohluli, B., Kalantar Motamed, M.H., Fatemi, M.J., Moharamnejad, N., 2011. Effectiveness of buccal fat in closing residual midpalatal and posterior palatal fistulas in patients previously treated for clefts. *J. Oral Maxillofac. Surg.* 69, e416–e419. <https://doi.org/10.1016/j.joms.2011.02.010>.
- Bae, Y.C., Park, T.S., Kang, G. Bin, Nam, S.B., Bae, S.H., 2016. Usefulness of microfat grafting in patients with repaired cleft lip. *J. Craniofac. Surg.* 27, 1722–1726. <https://doi.org/10.1097/SCS.0000000000002976>.
- Balkin, D.M., Samra, S., Steinbacher, D.M., 2014. Immediate fat grafting in primary cleft lip repair. *J. Plast. Reconstr. Aesthetic Surg.* 67, 1644–1650. <https://doi.org/10.1016/j.jbips.2014.08.049>.
- Baum, S.H., Rieger, G., Pfortner, R., Mohr, C., 2017. Correction of whistle deformity using autologous free fat grafting: first results of a pilot study and review of the literature. *Oral Maxillofac. Surg.* 21, 409–418. <https://doi.org/10.1007/s10006-017-0648-8>.
- Campbell, A., Restrepo, C., Park, E., Navas, G., Deshpande, G., Swanson, J., et al., 2019. Influence of severity on aesthetic outcomes of unilateral cleft lip repair in 1,823 patients. *Plast Reconstr Surg - Glob Open* 7, 1–7. <https://doi.org/10.1097/GOX.0000000000002083>.
- Coleman, S.R., 2006. Structural fat grafting: more than a permanent filler. *Plast. Reconstr. Surg.* 118, 108–120. <https://doi.org/10.1097/01.prs.0000234610.81672.e7>.
- Debnath, S., 2006. A Comparative Study of Primary Palatoplasty Using the Bilateral Pedicled Buccal Pad Fat Graft.
- Denadai, R., Seo, H.J., Lo, L.J., 2019. Persistent symptomatic anterior oronasal fistulae in patients with Veau type III and IV clefts: a therapeutic protocol and outcomes. *J. Plast. Reconstr. Aesthetic Surg.* 73, 126–133. <https://doi.org/10.1016/j.jbips.2019.05.033>.
- Emara, D., Tahseen, H., 2017. The role of fat transfer in secondary cleft lip patients. *Egypt. J. Plast Reconstr Surg* 41, 375–379.
- Gröbe, A., Eichhorn, W., Hanken, H., Precht, C., Schmelzle, R., Heiland, M., et al., 2011. The use of buccal fat pad (BFP) as a pedicled graft in cleft palate surgery. *Int. J. Oral Maxillofac. Surg.* 40, 685–689. <https://doi.org/10.1016/j.ijom.2011.02.024>.
- Horswell, B.B., Chou, J., 2019. Does the children's hospital of Philadelphia modification improve the fistula rate in furlow double-opposing Z-plasty? *J. Oral Maxillofac. Surg.* 1–11. <https://doi.org/10.1016/j.joms.2019.08.018>.
- Hu, S., Levinson, J., Rousso, J.J., 2020. Revision surgery of the cleft palate. *Semin. Plast. Surg.* 34, 120–128. <https://doi.org/10.1055/s-0040-1709429>.
- Idone, F., Sisti, A., Tassinari, J., Nisi, G., 2015. Fat grafting in primary cleft lip repair. *Plast. Reconstr. Surg.* 136, 708e. <https://doi.org/10.1097/PRS.0000000000001665>.
- Jones, C.M., Morrow, B.T., Albright, W.B., Long, R.E., Samson, T.D., Mackay, D.R., 2017. Structural fat grafting to improve reconstructive outcomes in secondary cleft lip deformity. *Cleft Palate-Craniofacial J.* 54, 70–74. <https://doi.org/10.1597/15-197>.
- Khosla, R., McGregor, J., Kelley, P., Gruss, J., 2012. Contemporary concepts for the bilateral cleft lip and nasal repair. *Semin. Plast. Surg.* 26, 156–163. <https://doi.org/10.1055/s-0033-1333885>.
- Kim, J.-Y., Kim, S.-G., Park, Y.-W., Hwang, D.S., Paeng, J.-Y., Seok, H., 2020. The effect of buccal fat pad graft in the palatoplasty and the risk factor of postoperative palatal fistula. *Oral Maxillofac. Surg.* 1–4. <https://doi.org/10.1097/scs.00000000000006151>.
- Koonce, S.L., Grant, D.G., Cook, J., Stelnicki, E.J., 2018. Autologous fat grafting in the treatment of cleft lip volume asymmetry. *Ann. Plast. Surg.* 80, 2–5. <https://doi.org/10.1097/SAP.0000000000001348>.
- Lee, D.W., Kim, Y.S., Park, B.Y.Y., 2012. Simultaneous correction of scars and tissue deficiency with composite grafts in secondary cleft lip deformity. *J. Oral Maxillofac. Surg.* 70, 419–427. <https://doi.org/10.1016/j.joms.2012.02.026>.
- Levi, B., Kasten, S.J., Buchman, S.R., 2009. Utilization of the buccal fat pad flap for congenital cleft palate repair. *Plast. Reconstr. Surg.* 123, 1018–1021. <https://doi.org/10.1097/PRS.0b013e318199f80f>.
- Liberati, A., Altman, D.G., Tetzlaff, J., Mulrow, C., Gøtzsche, P.C., Ioannidis, J.P.A., et al., 2009. The PRISMA statement for reporting systematic reviews and meta-analyses of studies that evaluate health care interventions: explanation and elaboration. *PLoS Med.* 6. <https://doi.org/10.1371/journal.pmed.1000100>.
- Mapar, D., Khanlar, F., Sadeghi, S., Abdali, H., Memarzadeh, M., Davari, H.A., et al., 2019. The incidence of velopharyngeal insufficiency and oronasal fistula after primary palatal surgery with Sommerlad intravelar veloplasty: a retrospective study in Isfahan Cleft Care Team. *Int. J. Pediatr. Otorhinolaryngol.* 120, 6–10. <https://doi.org/10.1016/j.ijporl.2018.12.035>.
- Mulliken, J.B., Wu, J.K., Padwa, B.L., 2003. Repair of bilateral cleft lip: review, revisions, and reflections. *J. Craniofac. Surg.* 14, 609–620. <https://doi.org/10.1097/00001665-200309000-00003>.
- Niechajev, I., 2000. Lip enhancement: surgical alternatives and histologic aspects. *Plast. Reconstr. Surg.* 105, 1173–1183. <https://doi.org/10.1097/00006534-200003000-00056>.
- Owusu, J.A., Liu, M., Sidman, J.D., Scott, A.R., 2013. Does the type of cleft palate contribute to the need for secondary surgery? A national perspective. *Laryngoscope* 123, 2387–2391. <https://doi.org/10.1002/lary.24008>.
- Patel, I.A., Hall, P.N., 2004. Free dermis-fat graft to correct the whistle deformity in patients with cleft lip. *Br. J. Plast. Surg.* 57, 160–164. <https://doi.org/10.1016/j.jbips.2003.11.007>.
- Qiu, C.S., Fracol, M.E., Bae, H., Gosain, A.K., 2019. Prophylactic use of buccal fat flaps to improve oral mucosal healing following furlow palatoplasty. *Plast. Reconstr. Surg.* 143, 1179–1183. <https://doi.org/10.1097/PRS.0000000000005430>.
- Resnick, C.M., Partridge, J., Dang, R.R., Burashed, H.M., Padwa, B.L., Mulliken, J.B., 2018. Augmentation of the median tubercle with dermis-fat graft in children with repaired cleft lip. *Plast. Reconstr. Surg.* 141, 540e–546e. <https://doi.org/10.1097/PRS.0000000000004237>.
- Saralaya, S., Desai, A.K., Kumar, N., 2019. Difficulty index-based management of palatal fistula after primary cleft palate repair: an institutional experience. *J. Oral Maxillofac. Surg.* 77, 851.e1–851.e7. <https://doi.org/10.1016/j.joms.2018.12.005>.
- Schwaiger, M., Edmondson, S.J., Wallner, J., Mischak, I., Echlin, K., Paddle, A., et al., 2019. Influence of different techniques of secondary cleft lip revision surgery on upper lip projection. *Int. J. Oral Maxillofac. Surg.* <https://doi.org/10.1016/j.ijom.2019.10.010>.
- Smyth, A.G., Wu, J., 2019. Cleft palate outcomes and prognostic impact of palatal fistula on subsequent velopharyngeal function—a retrospective cohort study. *Cleft Palate-Craniofacial J.* 56, 1008–1012. <https://doi.org/10.1177/1055665619829388>.
- Thomas, M., D'silva, J.A., Chilgar, R.M., 2012. Volume enhancement of upper lip in secondary cleft deformity using composite mastoid tissue. *Aesthetic Plast. Surg.* 36, 414–420. <https://doi.org/10.1007/s00266-011-9822-9>.
- Thomas, M.D., Pfaff, M.J., Tonn, J., Steinbacher, D.M., 2013. Normal nasolabial anatomy in infants younger than 1 year of age. *Plast. Reconstr. Surg.* 131, 574–581. <https://doi.org/10.1097/PRS.0b013e3182818ee5>.
- Veeramani, A., Wilson, A.T., Sawh-Martinez, R., Steinbacher, D.M., 2020. Staged abbe-rhinoplasty technique to correct bilateral cleft deformity. *Plast. Reconstr. Surg.* 518–521. <https://doi.org/10.1097/PRS.0000000000006508>.
- Wang, Y., Qi, Z., Wang, X., 2014. Original article dermis reconstruction and dermis fat graft through an intraoral incision: a new method to correct the furrowed philtral column deformity in lesser-form cleft lip. *Cleft Palate-Craniofacial J.* 51, 184–188. <https://doi.org/10.1597/12-076>.
- Yamaguchi, K., Lonic, D., Lee, C.H., Yun, C., Lo, L.J., 2016. Modified furlow palatoplasty using small double-opposing Z-plasty: surgical technique and outcome. *Plast. Reconstr. Surg.* 137, 1825–1831. <https://doi.org/10.1097/PRS.0000000000002181>.
- Zellner, E.G., Pfaff, M.J., Steinbacher, D.M., 2015. Fat grafting in primary cleft lip repair. *Plast. Reconstr. Surg.* 135, 1449–1453. <https://doi.org/10.1097/PRS.0000000000001187>.
- Zhang, J.X., Arneja, J.S., 2017. Evidence-based medicine: the bilateral cleft lip repair. *Plast. Reconstr. Surg.* 140, 152e–165e. <https://doi.org/10.1097/PRS.0000000000003474>.
- Zhang, Q., Li, L., Tan, W., Chen, L., Gao, N., Bao, C., 2010. Application of unilateral pedicled buccal fat pad for nasal membrane closure in the bilateral complete cleft palate. *J. Oral Maxillofac. Surg.* 68, 2029–2032. <https://doi.org/10.1016/j.joms.2010.02.042>.
- Zhang, Z., Fang, S., Zhang, Q., Chen, L., 2014. Analysis of complications in primary cleft lips and palates surgery. *J. Craniofac. Surg.* 25, 968–971. <https://doi.org/10.1097/SCS.0000000000000832>.
- Zheng, D., Zhou, J., Yu, L., Zhang, Y., Wang, J., 2020. Autologous fat transplantation to improve lip contour in secondary cleft lip deformity. *J. Craniofac. Surg.* 31, 343–346. <https://doi.org/10.1097/SCS.00000000000006071>.