

Ultrasound-Guided Suprazygomatic Maxillary Nerve Block Is Effective in Reducing Postoperative Opioid Use Following Bimaxillary Osteotomy

Gloria Molins, MD, *Adaia Valls-Ontañón, MD, DD, PhD,^{†‡}
Miriam De Nadal, MD, PhD,[§] and Federico Hernández-Alfaro, MD, DD, PhD^{||¶}

Background: Ultrasound-guided maxillary nerve block has recently been described, though its impact upon bimaxillary osteotomy has not been formally investigated.

Purpose: The present study was carried out to determine whether the addition of ultrasound-guided maxillary nerve block in subjects undergoing bimaxillary osteotomy reduces opioid use.

Study Design, Setting, Sample: A randomized clinical trial was carried out in adults undergoing bimaxillary osteotomy between April 2019 and January 2020 at Teknon Medical Center (Barcelona, Spain).

Predictor Variable: The predictor variable was the treatment technique used (maxillary nerve block or no block). The subjects were randomized to either receive (test group) or not receive (control group) bilateral ultrasound-guided suprazygomatic maxillary nerve block (5 ml of 0.37% ropivacaine) before surgery.

Main Outcome Variable(s): The primary outcome variable was the intravenous methadone requirements in the first two postoperative hours. The secondary outcome variables were postoperative pain, rescue subcutaneous methadone, intravenous remifentanyl used intraoperatively, the incidence of postoperative nausea-vomiting, and complications derived from maxillary nerve block.

Covariates: Subject age, sex, weight, height, and anesthetic risk, and the duration of surgery were recorded.

Analyses: Descriptive and inferential analyses were performed using the χ^2 test and Mann-Whitney *U* test. Statistical significance was considered for $P < .05$.

Results: The baseline sample consisted of 68 subjects scheduled for bimaxillary osteotomy. The follow-up sample comprised 60 subjects: 30 in the control group (10 females and 20 males, aged 34.0 ± 10.2 years) and 30 in the test group (13 females and 17 males, aged 29.8 ± 10.8 years). The subjects who received maxillary nerve block showed less intravenous methadone use in the first 2 hours postsurgery (median 2.0 mg control group vs 0 mg test group; $P < .001$), lower pain levels at any time during the first 18 hours postsurgery (median visual analog score 4 control group vs 2 test group; $P < .001$), and a

*Deputy Anesthesiologist, Department of Anesthesiology, Anestesia, Teknon Medical Center, Barcelona, Spain.

†Deputy Maxillofacial Surgeon, Department of Oral and Maxillofacial Surgery, Institute of Maxillofacial Surgery, Teknon Medical Center, Barcelona, Spain.

‡Associate Professor, Department of Oral and Maxillofacial Surgery, Universitat Internacional de Catalunya, Barcelona, Spain.

§Associate Professor, Department of Surgery, Universitat Autònoma de Barcelona, Hospital Vall d'Hebró, Barcelona, Spain.

||Chief, Department of Oral and Maxillofacial Surgery, Institute of Maxillofacial Surgery, Teknon Medical Center, Barcelona, Spain.

¶Professor and Department Head, Department of Oral and Maxillofacial Surgery, Universitat Internacional de Catalunya, Barcelona, Spain.

Conflict of Interest Disclosures: None of the authors have any relevant financial relationship(s) with a commercial interest.

Trial Registration: [Clinicaltrials.gov](https://clinicaltrials.gov) Identifier: NCT03913429. Principal investigator: Gloria Molins. Date of registration: April 2019.

Address correspondence and reprint requests to Dr Molins: Deputy anesthesiologist, Department of Anesthesia, Anestesia, Teknon Medical Center, c/ Vilana n° 12, 08034 Barcelona, Spain; e-mail: molinsgloria@me.com

Received December 28 2022

Accepted December 28 2023

© 2024 American Association of Oral and Maxillofacial Surgeons
0278-2391/23/01350-2

<https://doi.org/10.1016/j.joms.2023.12.018>

lesser percentage required methadone (33.3% control group vs 0% test group; $P < .01$) at 4-18 hours post-surgery.

Conclusion and Relevance: The results obtained suggest that ultrasound-guided maxillary nerve block is a promising anesthetic technique capable of reducing intraoperative and postoperative opioid use, with greater patient comfort in bimaxillary osteotomy.

© 2024 American Association of Oral and Maxillofacial Surgeons

J Oral Maxillofac Surg ■:1-10, 2024

Bimaxillary orthognathic surgery (BOS) is complex, and its anesthetic management is a challenge for two main reasons: the foreseeable difficulty of managing the patient's airway and the control of patient pain in the perioperative period.

Regarding pain control, BOS under general anesthesia constitutes the common practice, along with nonultrasound-guided isolated terminal peripheral nerve blocks.¹ These minor blocks are performed by the surgeon before incision via the intraoral and intranasal routes through infiltration of local anesthesia (LA) and a vasoconstrictor with the purpose of reducing pain, minimizing bleeding, facilitating subperiosteal dissection, and avoiding the undesired effects of an excessive use of intravenous anesthetics and analgesics. Opioids are often used, among other medications, to control perioperative pain, with the consequences this entails—particularly nausea-vomiting and adverse respiratory effects.² Despite advances in surgical techniques and anesthetic management, patients undergoing orthognathic surgery continue to experience moderate to severe postoperative pain.^{3,4} In recent years, clinicians have employed multimodal analgesic regimens to reduce postoperative pain, enhance functional recovery, and shorten hospital stay. Specifically, systematic reviews pooling moderate to high quality evidence suggest that peripheral nerve blocks reduce pain and opioid consumption, and improve patient satisfaction.⁵ Moreover, population-based studies suggest that nerve blocks may reduce costs and the length of hospital stay.⁶ However, nerve blocks of the face have been scantily investigated, and further review is required in this field. Regional anesthesia refers to the infiltration of LA near a cluster of nerves seeking to numb only the area of the body that requires surgery. It is increasingly being used in many types of surgeries to afford multimodal control of perioperative pain, with effective intraoperative and postoperative analgesia, which reduces respiratory depression secondary to excessive opioid use.⁷ Recent literature has supported the use of bilateral ultrasound-guided suprazygomatic maxillary nerve block (SMB) for maxillofacial surgeries, with studies having documented better perioperative pain control while the incidence of adverse outcomes is not significant.⁸⁻¹⁷ In expert hands, SMB safely provides analgesia of the middle third of the face in a

wide range of maxillofacial surgeries.⁸⁻¹⁷ A multimodal approach to pain control is essential in patients undergoing BOS.

Thus, the purpose of the present study was to optimize perioperative pain control and reduce opioid use. The investigators hypothesize that adding SMB to general anesthesia reduces the opioid requirements after BOS versus not adding SMB.

The specific aim of the study was to determine whether the addition of SMB to a general anesthesia regimen reduces the intravenous methadone requirements in the first two postoperative hours after BOS. Secondary objectives of the study were to evaluate the postoperative pain scores, intraoperative and postoperative opioid use up to 18 hours after surgery and postoperative nausea-vomiting (PONV) over the same period, and any potential complications derived from the infiltrations and nerve blocks.

Methods

STUDY DESIGN

To address the research purpose, the investigators designed and implemented a prospective, randomized, double-blind clinical trial in adults who underwent BOS at the Maxillofacial Institute - Centro Medico Teknon (Barcelona, Spain). The study was approved by the local Ethics Committee (Registration number: CMT-ANE-2018-02; Chairman: Simon J.L.; Date of registration: April 2018), abided with the Declaration of Helsinki and was registered in www.clinicaltrials.gov (Registration number: NCT03913429; Principal investigator: Gloria Molins; Date of registration: April 2019; Protocol available). The manuscript adheres to the Consolidated Standards of Reporting Trials (CONSORT) statement. The study population comprised all adults presenting for BOS between April 2019 and January 2020.

To be included in the study sample, the study subjects had to undergo elective BOS. Subjects rejecting participation were excluded, as were individuals under 18 years of age, subjects undergoing reoperations or urgent surgery, and subjects with allergy to local anesthetics, anti-inflammatory medication, opioids or adjuvant drug treatments. Written informed consent was obtained from all the subjects before their inclusion in the trial.

Randomization and Blinding

A statistician not participating in any other way in the study generated a 1:1 randomization table for subject allocation: control group (subjects not receiving SMB) or test group (subjects receiving SMB before surgery). Immediately after subject arrival in the operating room, the investigating anesthesiologist opened a sequentially numbered, sealed opaque envelope containing subject allocation (test group [SMB] or control group [non-SMB]). Only the anesthesiologist in the operating room who performed or did not perform SMB was not blinded to subject allocation. The surgeons, nurses, research assistants, and subjects were all blinded to allocation.

Anesthetic Management

The subjects were received in the surgical area for the administration of premedication and antibiotic prophylaxis. In the operating room, standard noninvasive intraoperative monitoring and general anesthesia was started (fentanyl $2 \mu\text{g kg}^{-1}$ i.v., propofol 2 mg kg^{-1} i.v., rocuronium 0.6 mg kg^{-1} i.v.), with balanced maintenance anesthesia (sevoflurane minimum alveolar concentration 1.2 and target-controlled infusion [TCI] of remifentanyl, Schnider-model effective concentration 2 ng ml^{-1}). Following nasal intubation and mechanical ventilation, pharyngeal tamponade was applied, with the administration of LA.

In the test group, the anesthesiologist performed SMB (5 ml of 0.37% ropivacaine injected in each side) in the anesthetized subject before the surgical procedure. The needle (21 gauge 100 mm Locoplex - Vygon, Ecouen, France) puncture was located at the angle formed by the upper edge of the zygomatic arch below and the posterior orbital rim forward. The needle was inserted perpendicular to the skin and advanced to reach the greater wing of the sphenoid at a depth of approximately 30 mm. The needle was then reoriented and advanced 40-55 mm deep to the pterygopalatine fossa (Fig 1A).⁹ Ultrasound images were obtained using a portable ultrasound unit (S-Nerve Sonosite Fujifilm, Bothell, WA, USA) and a 6-13 MHz linear array probe. The ultrasound transducer was located in the infrazygomatic area, over the maxilla, with an inclination of 45° in both the frontal and horizontal planes. The location of the probe allowed visualization of the pterygopalatine fossa, limited anteriorly by the maxilla and posteriorly by the greater wing of the sphenoid. The needle was advanced using the out-of-plane approach, and the needle tip was easily identified during movements and LA administration (Fig 1B).⁹ The bilateral nerve block procedure had a maximum duration of 5 minutes.

In turn, in both groups, the surgeon performed preincisional infiltration with lidocaine and adrenaline (a total of 50 ml of the following preincisional mixture was infiltrated: 0.5 amp. adrenaline 1 mg ml^{-1} and 1 amp. 10 ml 2% lidocaine in physiological saline solution 100 ml) at

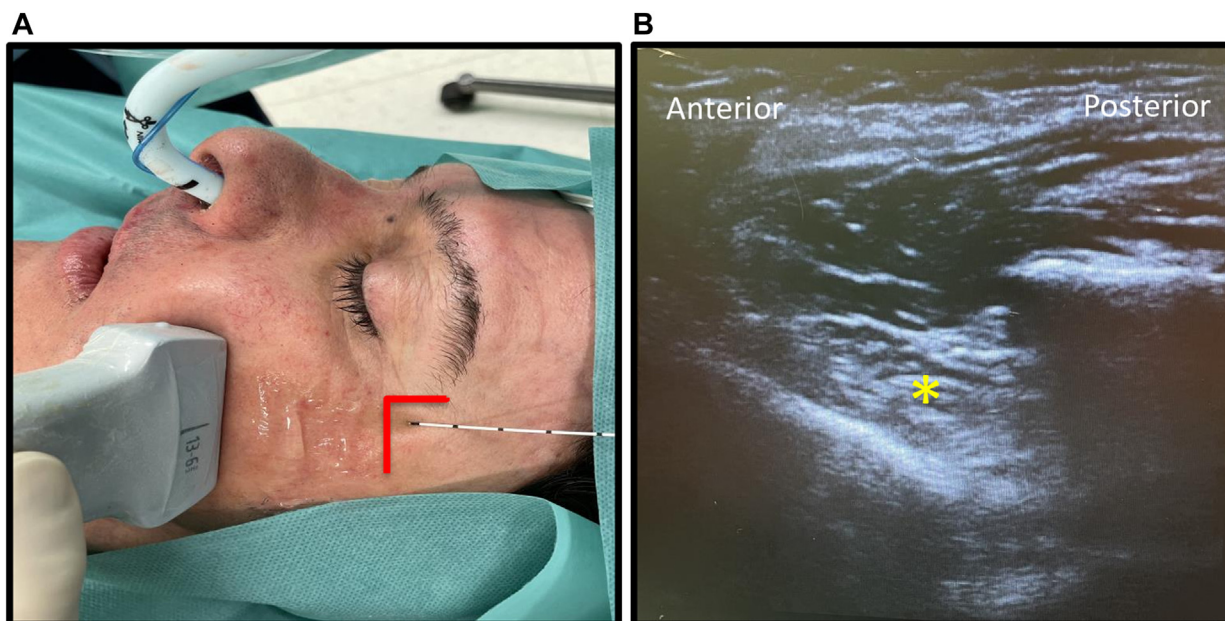


FIGURE 1. Maxillary nerve block by suprazygomatic approach with an infrazygomatic ultrasound window. *A*, The needle entry point is situated at the angle formed by the superior edge of the zygomatic arch below and the posterior orbital rim forward. Location of the ultrasound probe under the maxilla, in the infrazygomatic area, with an inclination of 45° in both the frontal and horizontal planes. *B*, Ultrasound imaging of the pterygopalatine fossa* delimited by the maxilla (anterior) and the greater wing of the sphenoid (posterior).

Table 1. COVARIABLES VERSUS TREATMENT GROUP

Group	Control	Test	P Value
n (patients)	30	30	
Age (years)	34.0 ± 10.2	29.8 ± 10.8	.127
Sex			
Male	20 (66.7)	17 (56.7)	.426
Female	10 (33.3)	13 (43.3)	
Weight (kg)	67.2 ± 13.7	64.8 ± 14.7	.527
Height (cm)	173.1 ± 9.4	171.5 ± 8.9	.518
BMI (kg/m ²)	22.3 ± 3.3	21.8 ± 3.2	.564
ASA			
I	18 (60.0)	24 (80.0)	.091
II	12 (40.0)	6 (20.0)	

Note: Mean ± standard deviation or n (%). χ^2 test of association and *t* test for independent samples.

Abbreviations: ASA, American Society of Anesthesiologists; BMI, body mass index.

Molins et al. *Ultrasound-Guided Suprazygomatic Maxillary New Block*. *J Oral Maxillofac Surg* 2024.

intraoral and intranasal submucosal level in the upper and lower maxilla to block the terminal branches of the maxillary and mandibular nerve, respectively.

Before the surgical incision, TCI of remifentanyl was started at an effective concentration of 2 ng ml⁻¹. All subjects received intraoperative corticosteroids (methylprednisolone 15 mg kg⁻¹ i.v.), antifibrinolytic treatment (tranexamic acid 15 mg kg⁻¹ i.v.), gastric protection measures (ranitidine 50 mg i.v.), antiemetic medication (ondansetron 4 mg i.v.), analgesics (paracetamol 1 g i.v., dexketoprofen 50 mg i.v., diclofenac 75 mg i.m.), and ketamine at subanesthetic doses (0.4 mg kg⁻¹ i.v.). Intraoperatively, in the event of basal blood pressure variations ≥ 20%, remifentanyl was increased/reduced by 0.2 ng ml⁻¹ (TCI). If the blood pressure increments persisted for over 5 minutes, a remifentanyl bolus dose (20 µg i.v.) was administered. If the blood pressure reductions persisted for over 5 minutes or the mean blood pressure was < 60 mmHg, an ephedrine bolus dose (6 mg i.v.) was provided. The subjects were extubated in the operating room after pharyngeal tamponade removal, the suspension of gastric aspiration, and the reversal of neuromuscular relaxation and of the airway reflexes. The subjects were then transferred per protocol with light guiding elastics for intermaxillary fixation and local cold therapy (facial mask Hilotherm GmbH; Argenbühl, Germany) to the post-anesthesia care unit (PACU) for the first two postoperative hours, and then to the ward, for continued postoperative care.

Surgical Technique

In all cases, the mandible was operated upon first, without complementary treatments and with no statistically significant differences in the duration of surgery between the groups (mean duration 99.02 ± 15.02 minutes; range 80-140). Sagittal split osteotomy was performed using the Hunsuck-Dal Pont-Obwegeser technique, and the maxillary Le Fort I osteotomy was carried out with the minimally invasive twist technique.¹⁸ When indicated, maxillary segmentation was performed through the same minimally invasive approach between the upper lateral incisors and canines. Rigid internal fixation with a hybrid technique (a miniplate fixed with 4 monocortical screws and a retromolar bicortical screw) was carried out in the mandible,¹⁹ while two preformed Lindorf miniplates were fixed with monocortical screws in the lateral segments of the upper maxilla, leaving the premaxilla free of osteosynthesis.

STUDY VARIABLES

The predictor variable was the treatment technique (maxillary nerve block or no block). The covariates in the form of demographic (age, sex) and anthropometric data (weight [kg], height [cm]), and anesthetic risk (American Society of Anesthesiologists Physical Status Classification System - ASA score) were also recorded. The relationship between all these variables and the predictor variable was considered for statistical analysis (Table 1).

The primary outcome variable was the intravenous methadone requirements during the two postoperative hours in the PACU. The secondary outcome variables were postoperative pain up to 18 hours after surgery, rescue subcutaneous methadone administered in the in-patient ward from 2 to 18 hours postsurgery, intraoperative intravenous remifentanyl use, the incidence of PONV up to 18 hours after surgery, and complications derived from infiltrations and SMB. The relationship between covariates and the primary outcome variable was also considered for statistical analysis (Table 2).

Once surgery was completed, the subjects were assessed for pain intensity (visual analog scale [VAS]: 0 = no pain, 10 = worst pain imaginable) by nurses. Pain was scored firstly upon admission to the PACU, and every 15 minutes thereafter during the first 2 hours after surgery, and secondly in the hospital ward at 4, 8, and 18 hours postsurgery. According to the protocol of the center, paracetamol 1 g/8 h, dexketoprofen 50 mg/8 h, and metamizol 2 g/8 h were administered intravenously in a fixed manner. In addition, the presence of VAS > 3 in the postoperative period was considered an indicator of insufficient pain control, and rescue analgesia was administered (opioid in the form of methadone if the pain failed to subside: intravenous

Table 2. COVARIABLES VERSUS METHADONE USE IN THE POST-ANESTHESIA CARE UNIT

Use of Methadone	No	Yes	<i>P</i> Value
n (patients)	34	26	
Age (years)	31.1 ± 10.4	32.8 ± 11.1	.557
Sex			
Male	18 (48.6)	19 (51.4)	.112
Female	16 (69.6)	7 (30.4)	
Weight (kg)	63.7 ± 12.2	69.0 ± 16.0	.157
Height (cm)	171.7 ± 9.4	173.1 ± 8.7	.544
BMI (kg/m ²)	21.5 ± 2.7	22.8 ± 3.7	.139
ASA			
I	27 (64.3)	15 (35.7)	.069
II	7 (38.9)	11 (61.1)	

Note: Mean ± standard deviation or n (%). χ^2 test of association and *t* test for independent samples.

Abbreviations: ASA, American Society of Anesthesiologists; BMI, body mass index.

Molins et al. *Ultrasound-Guided Suprazygomatic Maxillary New Block. J Oral Maxillofac Surg* 2024.

methadone 2 mg in the PACU, and subcutaneous methadone 5 mg in the in-patient ward). The total doses of intravenous methadone (mg) in the postoperative period in the PACU (2 hours postsurgery) and subcutaneous methadone in the in-patient ward (4, 8 and 18 hours postsurgery) were recorded.

Intraoperative opioid use was recorded (remifentanyl TCI-effective concentration [$\text{ng}\cdot\text{ml}^{-1}$]) in order to evaluate intraoperative nociceptive stimulus control.

The incidence of nausea-vomiting was assessed at 2, 4, 8, and 18 hours postsurgery.

Lastly, the presence of complications of both infiltration with lidocaine-vasoconstrictor and SMB with ropivacaine was also documented (LA systemic toxicity, bleeding at the puncture site, vascular puncture-blood reflow through the needle during aspiration testing, local infection, and intraorbital puncture).

DATA COLLECTION

Covariates, intravenous and subcutaneous methadone requirements (mg), postoperative pain (VAS), intravenous remifentanyl use ($\text{ng}\cdot\text{ml}^{-1}$), the incidence of PONV, and complications derived from infiltrations and SMB were all collected from electronic clinical records (SAP, Walldorf, Germany).

DATA ANALYSIS

The study protocol included the calculation of sample size and statistical power using the standard *t* test formulations. The assessment of analgesic efficacy of the nerve blocks was evaluated based on methadone

use in the first two postoperative hours, and so this was regarded as the primary outcome from which to estimate the required sample size. At the time the study protocol was designed, scientific publications supporting the use of intravenous methadone in the perioperative period increased in number,^{20,21} but no randomized clinical trials in adults similar to our own were found in the literature. The sample size depended directly upon the minimum clinically relevant difference in mean drug use 2 hours after surgery between the two groups. In preliminary observations, the researchers reported postoperative intravenous methadone bolus dose consumptions of 0 ± 4 mg in a pilot study of patients subjected to maxillary nerve block in superior maxillary osteotomy,^{16,17} which was in line with the reported literature.^{22,23} Thus, a difference of 3 mg of intravenous methadone may be considered clinically relevant, and a total of 58 subjects (29 per group) would be needed to detect the difference as being significant with a statistical power of 80% and a statistical significance level (alpha) of 0.05 (PASS 2008 Number Cruncher Statistical System, USA).

The descriptive analysis involved calculation of the mean, standard deviation, interquartile range (IQR) and median for continuous variables, and absolute and relative frequencies for categorical variables. The Kolmogorov-Smirnov test revealed statistically significant deviations from normal distribution for most of the response variables. The objectives of the study were thus addressed using a nonparametric approach. The inferential analysis consisted of: (a) the nonparametric Mann-Whitney *U* test to contrast the homogeneity of distributions of the ordinal variables (pain, remifentanyl, and methadone) in the two treatment groups; (b) the χ^2 test to contrast the association between two categorical variables such as nausea-vomiting and group. Fisher exact test was also used in very low expected frequency tables; (c) the Brunner-Langer nonparametric model of longitudinal data for each dependent response variable (pain and remifentanyl) was measured at different timepoints, and an analysis of variance statistic was calculated to evaluate the changes of the variables over time; (d) independent samples *t* testing was used to contrast the homogeneity of the means in the demographic and clinical profile variables (age, weight, etc.) that did exhibit a normal distribution. The level of statistical significance was set at 5% ($\alpha = 0.05$). The SPSS version 22.0 statistical package for MS Windows (IBM, Armonk, NY, USA) was used throughout.

Results

Figure 2 displays the CONSORT flowchart corresponding to subject selection and dropouts. A total of 62 subjects were enrolled in the study (31 in each

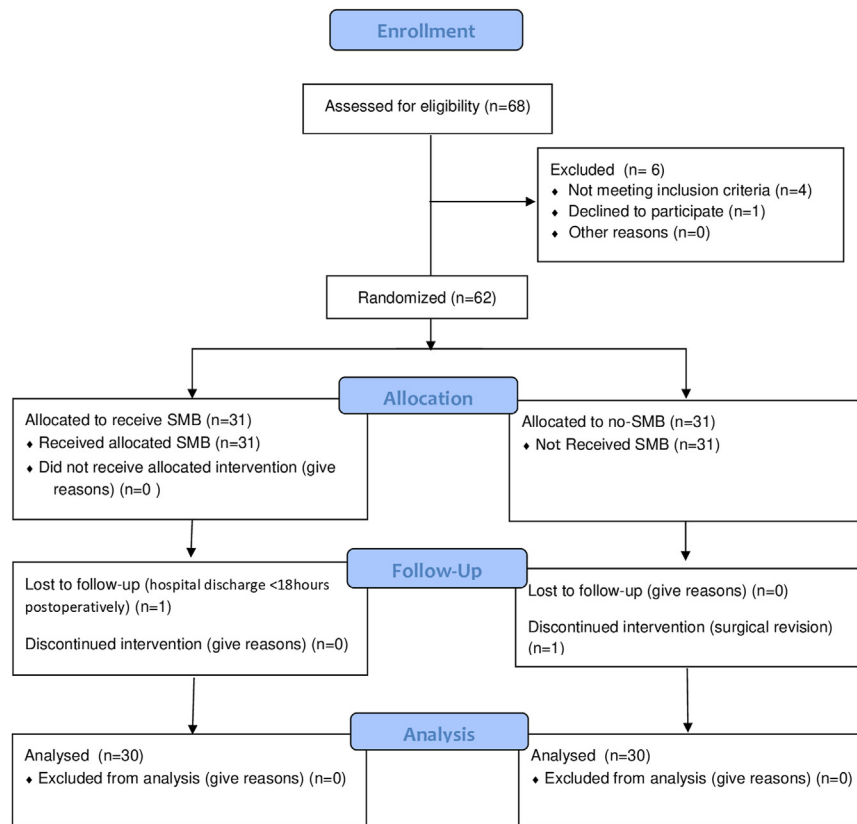


FIGURE 2. CONSORT diagram of patient recruitment. *SMB, ultrasound-guided bilateral suprazygomatic maxillary nerve block; CONSORT, Consolidated Standards of Reporting Trials.

Molins et al. *Ultrasound-Guided Suprazygomatic Maxillary New Block. J Oral Maxillofac Surg* 2024.

group) from April 2019 to January 2020, but finally only 30 subjects in the control group (10 females and 20 males, aged 34.0 ± 10.2 years) and 30 in the test group (13 females and 17 males, aged 29.8 ± 10.8 years) completed evaluation of the primary outcomes. One subject from the control group was lost because he required postoperative surgical revision and one subject from the study group was lost because he was discharged before 18 hours postoperatively.

There were no statistically significant differences in the baseline demographic characteristics between the groups (with and without SMB) (Tables 1 and 2).

POSTOPERATIVE OPIOIDS

In the PACU (from 0 to 2 hours after surgery), postoperative intravenous methadone use was significantly lower in the test group than in the control group (median and IQR: 0.0 [0-2] mg test group vs 2.0 [0-8] mg control group; $P < .001$). Furthermore, only 16.7% of the subjects in the test group required opioid medication, compared to 70% of the subjects in the control group ($P < .001$) (Table 3).

In contrast, in the in-patient ward (from 2 to 18 hours after surgery), subcutaneous methadone

dosing was found to be higher in the control group (median and IQR: 0 [0-0] mg test group vs 0 [0-5] mg control group; $P < .001$). The proportion of subjects requiring opioids was 0 and 33.3%, respectively ($P < .001$) (Table 3).

Table 3. POSTOPERATIVE METHADONE (MG) IN THE POST-ANESTHESIA CARE UNIT (INTRAVENOUS) AND IN-PATIENT WARD (SUBCUTANEOUS) ACCORDING TO GROUP

Group	Control	Test	P Value
PACU			
Rate (%)	70%	16.7%	<.001
Dose (mg)	2.0 (0-8)	0 (0-2)	<.001
WARD			
Rate (%)	33.3%	0%	.001
Dose (mg)	0 (0-5)	0 (0-0)	.001

Abbreviations: PACU, post-anesthesia care unit; WARD, in-patient ward.

Molins et al. *Ultrasound-Guided Suprazygomatic Maxillary New Block. J Oral Maxillofac Surg* 2024.

Table 4. EVOLUTION OF PAIN (VISUAL ANALOG SCALE) OVER FOLLOW-UP ACCORDING TO GROUP

Time (Hours)	2 Hours	4 Hours	8 Hours	18 Hours	P Value
Control	5.0 (0-10)	4.5 (0-9)	4.0 (0-7)	3.0 (0-5)	.76
Test	2.0 (0-5)	2.0 (0-6)	2.0 (0-5)	1.0 (0-3)	
P value	<.001	<.001	<.001	<.001	

Note: Median (range). Analyses of variance test for statistics test of the Brunner-Langer model on the homogeneity of evolution of both groups. Mann-Whitney *U* test on the homogeneity between groups in a given time.

Molins et al. *Ultrasound-Guided Suprazygomatic Maxillary New Block. J Oral Maxillofac Surg* 2024.

POSTOPERATIVE PAIN

The Brunner-Langer model showed pain intensity as assessed by the VAS to be significantly lower in the test group than in the control group at all timepoints within the first 18 hours after surgery ($P < .001$). However, pain evolution over time proved similar in both groups ($P = .76$), with a decrease in pain intensity over 18 hours (Table 4).

INTRAOPERATIVE OPIOIDS AND EPHEDRINE

The intraoperative opioid infusion doses were seen to decrease rapidly during the first hour in the test group (from a median of 2.0 to 1.0 remifentanyl TCD), while in the control group the initial opioid doses remained constant over time (with a median of 2.0)—the difference being statistically significant ($P < .001$) (Table 5 and Fig 3).

No statistically significant differences were found in either the proportion of subjects who required remifentanyl boluses or the bolus dose received. No ephedrine boluses were recorded in either group.

POSTOPERATIVE NAUSEA AND VOMITING

From 2 to 8 hours postsurgery, the incidence of PONV differed significantly between the two groups, being lower in the test group at 2, 4, and 8 hours ($P < .05$), while the incidence was seen to be practically zero after 18 hours in both groups ($P = .49$). Furthermore, the incidence of PONV was seen to decrease at a similar rate in both groups ($P = .17$) (Table 6).

COMPLICATIONS

There were no complications of the LA infiltrations or nerve blocks in either group.

Discussion

The present randomized clinical trial was conducted to investigate and compare the treatment outcomes of subjects that underwent BOS treated with SMB versus no SMB. The authors hypothesized that SMB

would be more effective than no SMB for pain control. The pretreatment (baseline) bivariate associations between the study and predictor variables confirmed no statistically significant differences in the predictor variables, including age, sex, weight, height, and anesthetic risk. The specific aim of the study was to determine whether the addition of SMB to a general anesthesia regimen reduces the intravenous methadone requirements in the first two postoperative hours after BOS.

In the present study, maxillary nerve block was performed adopting a suprazygomatic approach with an infrazygomatic ultrasound window, for increased safety and effectiveness. Effective anesthesia of the maxillary area is achieved by inserting the needle through the pterygomaxillary fissure to the pterygopalatine fossa—though with a high risk of causing vessel and nerve puncture. Real-time visualization of the block procedure under ultrasound guidance is therefore used to limit this risk. Since the pterygopalatine fossa anatomically lies deep and is surrounded by bone, the best ultrasound window for visualization is the infrazygomatic approach—allowing us to monitor the entire axis of the pterygopalatine fossa.²⁴ Three approaches for maxillary nerve block in the pterygopalatine fossa under ultrasound guidance have been described (infrazygomatic in-plane, infrazygomatic out-of-plane, and suprazygomatic out-of-plane).²⁵ The suprazygomatic approach from the frontozygomatic angle is one of the safest and most recommended routes for reaching the pterygopalatine fossa.²⁶ This approach limits insertion of the needle in the anterior portion of the foramen rotundum, thus avoiding inadvertent puncture of the infraorbital contents through the infraorbital fissure.²⁷

The reason why the researchers decided to carry out the study in patients subjected to BOS is that good results were obtained in preliminary observations with SMB in zygomatic implant surgery and single maxillary orthognathic surgery.^{16,17} At our center, BOS is routinely performed under general anesthesia with infiltration only of the terminal branches of the maxillary and mandibular nerve using local anesthetic and

Table 5. EVOLUTION OF INTRAOPERATIVE TARGET-CONTROLLED INFUSION OF REMIFENTANIL (NG/ML EFFECTIVE CONCENTRATION) ACCORDING TO GROUP

Time (Minutes)	0	10	20	30	40	50	60	70	80
Control	2.0 (2.0-2.0)	2.0 (2.0-2.4)	2.0 (1.8-2.6)	2.0 (1.8-2.6)	2.0 (1.8-2.6)	2.0 (1.8-2.6)	2.0 (1.6-2.6)	2.0 (1.6-2.4)	1.7 (1.0-2.0)
Test	2.0 (2.0-2.0)	2.0 (1.6-2.4)	2.0 (1.2-1.8)	1.6 (1.0-2.8)	1.6 (0.8-2.4)	1.2 (0.6-2.4)	1.2 (0.6-2.4)	1.0 (0.0-2.0)	1.0 (0.0-2.0)
P value	1.00	.525	<.01	<.001	<.001	<.001	<.001	<.001	<.001
Time (Minutes)	90	100	110	120	130	140	P-Value		
Control	1.6 (1.0-2.0)	1.2 (1.0-2.0)	1.0 (1.0-2.0)	1.0 (1.0-2.0)	1.0 (0.8-2.0)	1.0 (1.0-1.0)	<.001		
Test	1.0 (0.0-1.6)	1.0 (0.0-1.4)	1.0 (0.6-1.4)	1.0 (0.8-1.0)	0.9 (0.8-1.0)	—			
P value	<.001	<.001	<.05	.25	.66	—			

Note: Median (range). Analyses of variance test for statistics test of the Brunner-Langer model on the homogeneity of evolution of both groups. Mann-Whitney *U* test on homogeneity between groups in a given time.

Molins et al. *Ultrasound-Guided Suprazygomatic Maxillary New Block. J Oral Maxillofac Surg* 2024.

vasoconstrictor.²⁸ Therefore, the researchers decided to perform peripheral infiltrations of LA and adrenaline in both groups to ensure study blinding and prevent LA infiltration from acting as a confounding factor in the evaluation of the outcomes.

The choice of LA is conditioned by factors such as the onset of effect, its duration and toxicity. Therefore, the researchers considered the combined use of lidocaine and ropivacaine at different timepoints to be appropriate: lidocaine for the infiltrations of the surgical field, affording faster action and antiarrhythmic effects in potentially arrhythmogenic surgical procedures,²⁹ and ropivacaine in SMB, affording longer action for pain control throughout the perioperative period.

The volume and type of LA used for SMB (5 ml of 0.37% ropivacaine) was chosen based on the published literature and on our own experience with other maxillofacial surgeries.^{8-12,16,17} Nevertheless,

the volume of LA is subject to controversy in clinical practice. On one hand, anesthesiologists who are experts in SMB in children calculate an LA dose of 0.15 ml/kg,⁸⁻¹² while on the other hand a study in cadavers carried out by Echaniz et al suggested that SMB with volumes < 5 ml could be equally effective and at the same time could reduce adverse effects.²⁴ Thus, we must ask ourselves where the remaining LA migrates. Perhaps it spreads to the pterygomandibular space where the inferior alveolar nerve (branch of the mandibular nerve) emerges, as some authors suggest.³⁰ Maybe this is why promising results of maxillary nerve block are obtained in these subjects undergoing bimaxillary osteotomy, where both the maxillary and mandibular nerves are involved. Further studies on cadavers are still needed to confirm this.

At the time of planning and starting the two studies, no similar scientific publications were found. There were only reports of isolated clinical cases describing

Evolution of TCI of Remifentanil (ng/ml) according to Group

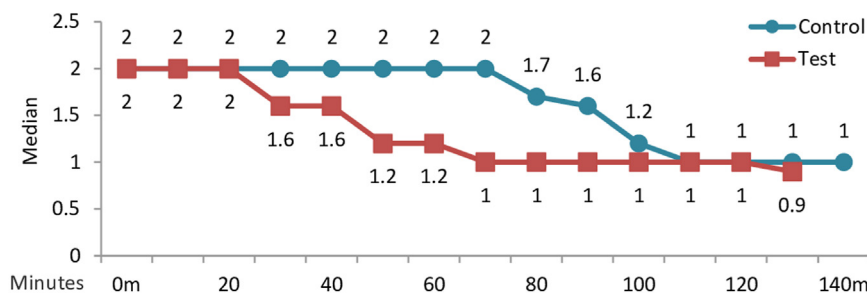


FIGURE 3. Evolution of the target-controlled infusion (TCI) of remifentanil (effective concentration [$\text{ng}\cdot\text{ml}^{-1}$]) over intraoperative time according to group.

Molins et al. *Ultrasound-Guided Suprazygomatic Maxillary New Block. J Oral Maxillofac Surg* 2024.

Table 6. EVOLUTION OF THE INCIDENCE OF POSTOPERATIVE NAUSEA AND VOMITING OVER FOLLOW-UP ACCORDING TO GROUP

Time (Hours)	2 h	4 h	8 h	18 h	P Value
Control	40.0%	40.0%	20.0%	6.7%	.17
Test	16.7%	10.0%	0.0%	0.0%	
P value	<.05	<.01	.02	.49	

Note: Percentage of affected patients. Analyses of variance test for statistics test of the Brunner-Langer model on the homogeneity of evolution of both groups. χ^2 test and Fisher exact test on homogeneity between groups in a given time.

Molins et al. Ultrasound-Guided Suprazygomatic Maxillary New Block. J Oral Maxillofac Surg 2024.

SMB and orthognathic surgery in adults. However, recently, progress has been made in the study of analgesia and maxillofacial surgery. García-Nores et al recently published a study of SMB in orthognathic surgery.³¹ This is a similar study, in this case involving pediatric patients subjected to superior maxillary osteotomy. The reported results were also favorable, though again it must be noted that these were pediatric patients and that postoperative pain management in this population differs from that in adults. However, it is worth noting here that the time of onset of oral tolerance was included in this study, being earlier in subjects who had received SMB, and suggesting that the time to first tolerated intake is correlated to the decrease in postoperative pain and to the decreased need for postoperative narcotics. Subsequently, Shetty et al published another study of regional blocks and orthognathic surgery.³² They reported good results using nerve blocks of the maxillary and mandibular nerves. In contrast, in the mentioned study, SMB was not performed under ultrasound guidance but was guided by anatomical landmarks.

The present study has a number of strengths and limitations that need to be considered. Firstly, blinding the anesthesiologist was infeasible. Secondly, as a standard practice at our center, the dosing of remifentanyl infusion by the anesthesia team is based on standard criteria such as hemodynamic responses. In this regard, it would have been better if such dosing had also relied on data provided by nociception monitors. Thirdly, in BOS, both the maxillary nerve and the mandibular nerve are implicated in perioperative pain. In general, in BOS, the surgeon performs bilateral infiltration of the inferior alveolar nerve, which is the largest (but not the only) branch of the mandibular nerve. New studies therefore could be considered, blocking the mandibular nerve under ultrasound guidance before it emits its multiple branches, in order to optimize the control of perioperative pain in BOS. Likewise, it would be of interest to conduct studies in cadavers to determine where the remaining LA migrates after filling the pterygopalatine fossa when maxillary nerve block is performed.

The administration of intravenous opioids is not only useful for the control of intraoperative nociceptive stimulus, but is also commonly used in BOS to control postoperative pain. However, this increases the risk of PONV, with greater patient dissatisfaction and a prolongation of hospital stay. Our results showed SMB under ultrasound guidance and with adjusted ropivacaine doses to be associated to a lesser need for opioids in both the intraoperative and postoperative periods (Tables 3 and 5). Last but not least, the incidence of PONV was lower among the subjects in the test group during the immediate postoperative period (in the first 8 hours postsurgery). It is important to highlight this decrease in PONV, because it also reduces the risk of bronchoaspiration in subjects with postoperative elastic intermaxillary fixation, and lowers the postoperative risk of edema.

In conclusion, adding SMB to subjects undergoing BOS under general anesthesia has been shown to be an effective procedure, affording significantly better results in statistical terms than simple general anesthesia in terms of pain management and analgesia demand, as well as in reducing PONV and avoiding the adverse effects of opioids.

References

1. Wang YH, Wang DR, Lius JY, Pan J. Local anesthesia in oral and maxillofacial surgery. A review of current opinion. *J Dent Sci* 16(4):1055-1065, 2021
2. Shanthanna H, Ladha KS, Kehlet H, Joshi GP. Perioperative opioid administration: A critical review of opioid-free versus opioid-sparing approaches. *Anesthesiology* 134(4):645-659, 2021
3. Philips C, Blakey G, Jaskolka M. Recovery after orthognathic surgery: Short-term health-related quality of life outcomes. *J Oral Maxillofac Surg* 66(10):2110-2115, 2008
4. Mobini A, Mehra P, Chigurupati R. Postoperative pain and opioid analgesic requirements after orthognathic surgery. *J Oral Maxillofac Surg* 76(11):2285-2295, 2018
5. Guay J, Parker MJ, Griffiths R, Kopp S. Peripheral nerve blocks for hip fractures. *Cochrane Database Syst Rev* 5(5):CD001159, 2017
6. Hamilton GM, Lalu MM, Ramlogan R, et al. A population-based comparative effectiveness study of peripheral nerve blocks for hip fracture surgery. *Anesthesiology* 131(5):1025-1035, 2019
7. Kumar A, Sinha C, Kumar A, Kumar P, Mukul SK. Ultrasound-guided trigeminal nerve block and its comparison with conventional analgesics in patients undergoing faciomaxillary surgery: Randomised control trial. *Indian J Anaesth* 62(11):871-875, 2018

8. Mesnil M, Dadure C, Captier G, et al. A new approach for perioperative analgesia of cleft palate repair in infants: The bilateral suprazygomatic maxillary nerve block. *Pediatr Anesth* 20(4): 343–349, 2010
9. Sola C, Raux O, Savath L, Macq C, Capdevila X, Dadure C. Ultrasound guidance characteristics and efficiency of suprazygomatic maxillary nerve blocks in infants: A descriptive prospective study. *Pediatr Anesth* 22(9):841–846, 2012
10. Chiono J, Raux O, Bringuier S, et al. Bilateral suprazygomatic maxillary nerve block for cleft palate repair in children: A prospective, randomized, double-blind study versus placebo. *Anesthesiology* 120(6):1362–1369, 2014
11. Bouzinac A, Tournier JJ, Dao M, Delbos A. Ultrasound-guided maxillary nerve block in adults: Feasibility and efficiency for postoperative analgesia after maxillary osteotomy. *Minerva Anesthesiol* 80(7):860–861, 2014
12. Echaniz G, De Miguel M, Merritt G, et al. Bilateral suprazygomatic maxillary nerve blocks vs. infraorbital and palatine nerve blocks in cleft lip and palate repair: A double-blind, randomised study. *Eur J Anaesthesiol* 36(1):40–47, 2019
13. Nader A, Schitteck H, Kendall MC. Lateral pterygoid muscle and maxillary artery are key anatomical landmarks for ultrasound-guided trigeminal nerve block. *Anesthesiology* 118(4):957, 2013
14. Kumar A, Kumar A, Sinha C, Singh AK. Ultrasound-guided trigeminal nerve block for faciomaxillary surgeries. *Saudi J Anaesth* 11(2):246–247, 2017
15. Chuang YW, Chen CH. Landmark of ultrasound-guided trigeminal block: Lateral pterygoid muscle. *Pain Physician* 18:E933–E934, 2015
16. Molins G, Valls-Ontañón A, De Nadal M, Hernandez-Alfaro F. Clinical experiences with ultrasound-guided suprazygomatic maxillary nerve block in zygomatic implants surgery: A new indication. *Reg Anesth Pain Med* 44:A107–A108, 2019
17. Molins G, Valls-Ontañón A, Masiá J, De Nadal M, Hernández-Alfaro F. Effects of ultrasound-guided bilateral suprazygomatic maxillary nerve block on postoperative pain after elective orthognathic monomaxillary osteotomy in adult patients. *Eur J Anaesthesiol* 37(e-S58):116, 2020
18. Hernández-Alfaro F, Guijarro-Martínez R. "Twist technique" for pterygomaxillary dysjunction in minimally invasive Le Fort I osteotomy. *J Oral Maxillofac Surg* 71(2):389–392, 2013
19. Hernández-Alfaro F, Raffaini M, Paredes-de-Sousa-Gil A, Magri AS, Guijarro-Martínez R, Valls-Ontañón A. Three-dimensional analysis of long-term stability after bilateral sagittal split ramus osteotomy fixed with a single miniplate with 4 monocortical screws and 1 bicortical screw: A retrospective 2-center study. *J Oral Maxillofac Surg* 75(5):1036–1045, 2017
20. Murphy GS, Avram MJ, Greenberg SB, et al. Perioperative methadone and ketamine for postoperative pain control in Spinal surgical patients. A randomized, double-blind, placebo-controlled trial. *Anesthesiology* 134(5):697–708, 2021
21. Pacreu S, Fernández J, Moltó L, Carazo J, Fernández S. The perioperative combination of methadone and ketamine reduces post-operative opioid usage compared with methadone alone. *Acta Anaesthesiol Scand* 56(10):1250–1256, 2012
22. Moro ET, Lambert ME, Pereira AL, et al. The effect of methadone on postoperative quality of recovery in patients undergoing laparoscopic cholecystectomy: A prospective, randomized, double blinded, controlled clinical trial. *J Clin Anesth* 53:64–69, 2019
23. Kitlik A, Erdogan MA, Ozgul U, et al. Ultrasound-guided transversus abdominis plane block for postoperative analgesia in living liver donors: A prospective, randomized, double-blinded clinical trial. *J Clin Anesth* 37:103–107, 2017
24. Echaniz G, Chan V, Maynes JT, Jozaghi Y, Agur A. Ultrasound-guided maxillary nerve block: An anatomical study using the suprazygomatic approach. *Can J Anaesth* 67(2):186–193, 2020
25. Anugerah A, Nguyen K, Nader A. Technical considerations for approaches to the ultrasound-guided maxillary nerve block via the pterygopalatine fossa: A literature review. *Reg Anesth Pain Med* 45(4):301–305, 2020
26. Zou F, Gong W, Zhang D, Fan K. A novel approach for performing ultrasound-guided trigeminal nerve block: Above the zygomatic arch. *J Clin Anesth* 60:36–38, 2020
27. Captier G, Dadure C, Leboucq N, Sagintaah M, Canaud N. Anatomic study using three-dimensional computed tomographic scan measurement for truncal maxillary nerve blocks via the suprazygomatic route in infants. *J Craniofac Surg* 20(1): 224–228, 2009
28. Sisk AL. Vasoconstrictors in local anesthesia for dentistry. *Anesth Prog* 39:187–193, 1992
29. Rashad A, el-Attar A. Cardiac dysrhythmias during oral surgery: Effect of combined local and general anaesthesia. *Br J Oral Maxillofac Surg* 28(2):102–104, 1990
30. Kumita S, Murouchi T, Arakawa J. Ultrasound-guided maxillary and inferior alveolar nerve blocks for postoperative analgesia in gnathoplasty. *Asian J Anesthesiol* 55(4):89–90, 2017
31. Garcia Nores GD, Cuzzzone DA, Hush SE, et al. The impact of bilateral suprazygomatic maxillary nerve blocks on postoperative pain control in patients undergoing orthognathic surgery. *FACE* 1(1):58–65, 2020
32. Shetty V, BhanuPrakash B, Yadav A, Kishore PN, Menon A. Do regional nerve blocks before bimaxillary surgery reduce postoperative pain? *J Oral Maxillofac Surg* 78(5):724–730, 2020