

Journal section: *Clinical and Experimental Dentistry*

Publication Types: *Research*

## Transalveolar screw: A new concept for orthodontic anchorage

Federico Hernández-Alfaro <sup>1</sup>, Elisabeth Egio <sup>2</sup>, Vanessa Ruiz <sup>3</sup>

<sup>1</sup> MD, DDS, FEBOMS, PhD. Director of the Program in Implant Dentistry, Universitat Internacional de Catalunya. Director Instituto de Cirugía Maxilofacial e Implantología, Teknon Medical Center. Barcelona, Spain

<sup>2</sup> DDS. Master in Orthodontics, Universitat Internacional de Catalunya

<sup>3</sup> DDS. Master in Periodontics, Associate profesor in Periodontology, Universitat Internacional de Catalunya

### Correspondence:

Instituto de Cirugía Maxilofacial e Implantología

Centro Medico Teknon

C/ Vilana, 12.

08022, Barcelona, Spain

director@institutomaxilofacial.com

Hernández-Alfaro F, Egio E, Ruiz V. Transalveolar screw: A new concept for orthodontic anchorage. Med Oral Patol Oral Cir Bucal. 2009 Apr 1;14 (4):E198-202.

<http://www.medicinaoral.com/medoralfree01/v14i4/medoralv14i4p198.pdf>

Received: 15/10/2008

Accepted: 16/01/2009

Article Number: 5123658903 <http://www.medicinaoral.com/>  
© Medicina Oral S. L. C.I.F. B 96689336 - pISSN 1698-4447 - eISSN: 1698-6946  
eMail: [medicina@medicinaoral.com](mailto:medicina@medicinaoral.com)

### Indexed in:

- SCI EXPANDED
- JOURNAL CITATION REPORTS
- Index Medicus / MEDLINE / PubMed
- EMBASE, Excerpta Medica
- SCOPUS
- Indice Médico Español

### Abstract

The purpose of this article is to describe the use of a new trans-alveolar screw (TAS) as a temporary orthodontic anchorage device for the posterior maxilla, to intrude overerupted maxillary molars. To date, five consecutive patients have been treated with these newly designed screws.

Intrusions achieved ranged from 2.1 and 6mm (mean 4.7mm). The TAS is cheap, easy to place and remove by the orthodontist, has bicortical anchorage, and is loaded on both sides. The main advantage of TAS is that when placed in the maxilla to intrude upper molars, it allows application of intrusive force from both buccal and palatal aspects simultaneously, so that the line of force in relation to the center of resistance of the posterior segment, permits an in-mass intrusion, avoiding buccal tipping or rotations. Moreover the surgical procedure for inserting and removing the bicortical screw is simple and does not require any surgical flap, so complications are minimal and screws can be loaded immediately, without requiring any waiting healing period of time.

**Key words:** *Orthodontic anchorage, miniscrews, molar intrusion, temporary anchorage device.*

### Introduction

Over the past several decades, an increasing number of adult patients have demanded for orthodontic treatment. Many of those patients have pre-existing conditions that are not seen in young patients, including tooth loss, periodontal disease, severe skeletal dysplasias, and temporomandibular dysfunction.

Sometimes, in these patients, as a result of early loss of antagonistic teeth, the maxillary molars are overerupted, exhibiting long clinical crowns and elongated dentoalveolar process (Fig. 1). The goal for these patients is to maintain what remains of their dentition and to regain

original position of teeth, levelling an uneven occlusal plane. The elongated dentoalveolar process may cause problems of occlusal interferences and functional disturbances and may result in great difficulty during prosthetic reconstruction (1).

The intrusion of an overerupted maxillary molar using conventional orthodontic treatment (intraoral and extraoral appliance) is a real challenge in adult patients, where some teeth are absent, and there is lack of cooperation. To overcome this anchorage limitation, and to avoid the side effect of extrusion of the anchorage teeth, we can use temporary anchorage devices (TADs),

which can be defined as biocompatible devices fixed to bone for the purpose of enhancing orthodontic anchorage either by supporting the teeth of the reactive unit or by obviating the need for the reactive unit altogether, and which is subsequently removed after use. The currently available temporary anchorage devices (TAD) are miniscrew implants, palatal implants, mini-plates, and most recently, bicortical screws.

Recent reports (1-8) have demonstrated the clinical efficiency of miniscrews and bone plates in intruding maxillary and mandibular molars, either to level the occlusal plane previously to a prosthetic reconstruction, or to close severe anterior open-bites. Up to date, various techniques to reinforce anchorage have been devised and used in orthodontic practise (9). Skeletal anchorage can be used to avoid these problems while obtaining pure intrusion of a posterior tooth. Intrusion using skeletal anchorage is simple and comfortable for the patient, and good results can be reliably obtained (10).

Because their limited resistance to withstand heavy orthodontic loading, however, these screws tend to loosen specially when they are placed in certain areas like the posterior maxilla where a low quality bone is often found. Other potential complications with mini-screws in orthodontics are soft tissue irritation at the site of insertion, risk of infection, and premature loosening of the screw (11).

Freudenthaler et al.(12) reported the use of bicortical titanium screws for critical orthodontic anchorage in the mandible. The screws were used to protract molars through extraction sites. Orthodontic force was applied, to get a translatory movement of the tooth. However, only the vestibular head of the screw was loaded. Bretin et al. (13) in an in-vitro study, found that bicortical screws provide the orthodontist superior anchorage resistance, reduce cortical stress, and superior stability compared with monocortical screws.

The purpose of this article is to describe the use of a new trans-alveolar screw (TAS) as a temporary orthodontic anchorage device for the posterior maxilla to intrude an overerupted maxillary molar. Due to its bicortical anchorage and ability to withstand bilateral (vestibular & palatal) loading, it might bear heavier orthodontic forces and have a lower rate of loosening and failure.

### Patients and Methods

The Trans-Alveolar Screw (TAS) has been designed by the authors, and engineered and manufactured by Tekka s.l. (Brignais, France), and consists of a nut & screw system, the nut being a machined shaft 2mm in diameter and of variable lengths (10,12,16 and 20mm) with a threaded interior. In one end, a 3-mm hex head with two crossed grooves and a tunnel, allows for engagement of orthodontic wires and elastics.

The screw has the same head and is twisted into the nut from the palatal side. (Fig.2a)

Presurgical work up includes periapical radiographs to define shape and direction of neighbouring roots. In our practice we have recently incorporated a CBCT which allows for more precise location of the roots and measuring of the width of the alveolar process.

To place the TAS, local anesthetic is infiltrated both in the vestibular and palatal sides.

A 1.8-mm bur drills transmucosally at the mucogingival junction. It crosses the alveolar process and exits through the palatal mucosa.

Then the nut is tapped through the resultant tunnel. The screw is locked into the nut. (Fig.2b)

Coil springs or rubber chains can then be attached to both heads and to the palatal & vestibular sides of the upper molars to be intruded. (Fig. 3a,b)

### Results

To date, five consecutive patients have been treated with these newly designed screws. The indications in all five were intrusion of overerupted posterior maxillary molars.

In all five, a single (unilateral) TAS was placed. Intrusions ranged between 2.1 and 6mm (mean 4.7mm). (Fig. 4)

Mean treatment time was 163 days (range 110 to 195 days).

No loosening of the screws was detected, the only complication being mucositis at the vestibular side in one patient which was managed with chlorhexidine gel.

In one patient, vestibular tipping of the intruding molars was detected. Correction was achieved by increasing the force at the palatal side.

### Discussion

The ideal temporary anchorage device (TAD) should be simple to use, small size, inexpensive, biocompatible, immediately loaded, and easy to remove after treatment. Moreover, should have great number of implant sites and indications, primary stability when placed, orthodontic connection, and of course not to require compliance, providing clinically equivalent or superior results when compared with traditional anchorage systems (14).

Most of the currently available anchorage devices lack one or more of those characteristics.

Osseointegrated implants are expensive and need edentulous spaces with enough bone to be placed. Conventional screws get loosened most of the times when placed in the posterior maxilla. Even if they are placed bicortically, the fact that they are unilaterally loaded provokes an unfavourable combination of forces that facilitates loosening. Miniplates are very stable but expensive and only act from the vestibular side, which warrants some degree of vestibular tipping of the intruding molars. They also need two invasive surgeries for placement and removal.

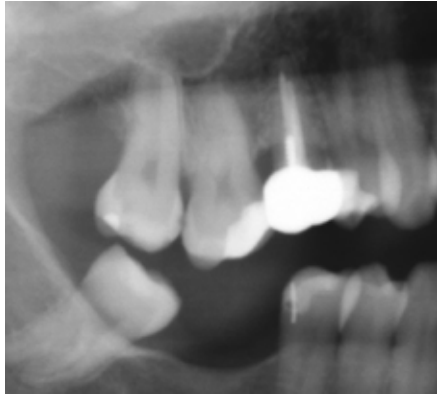
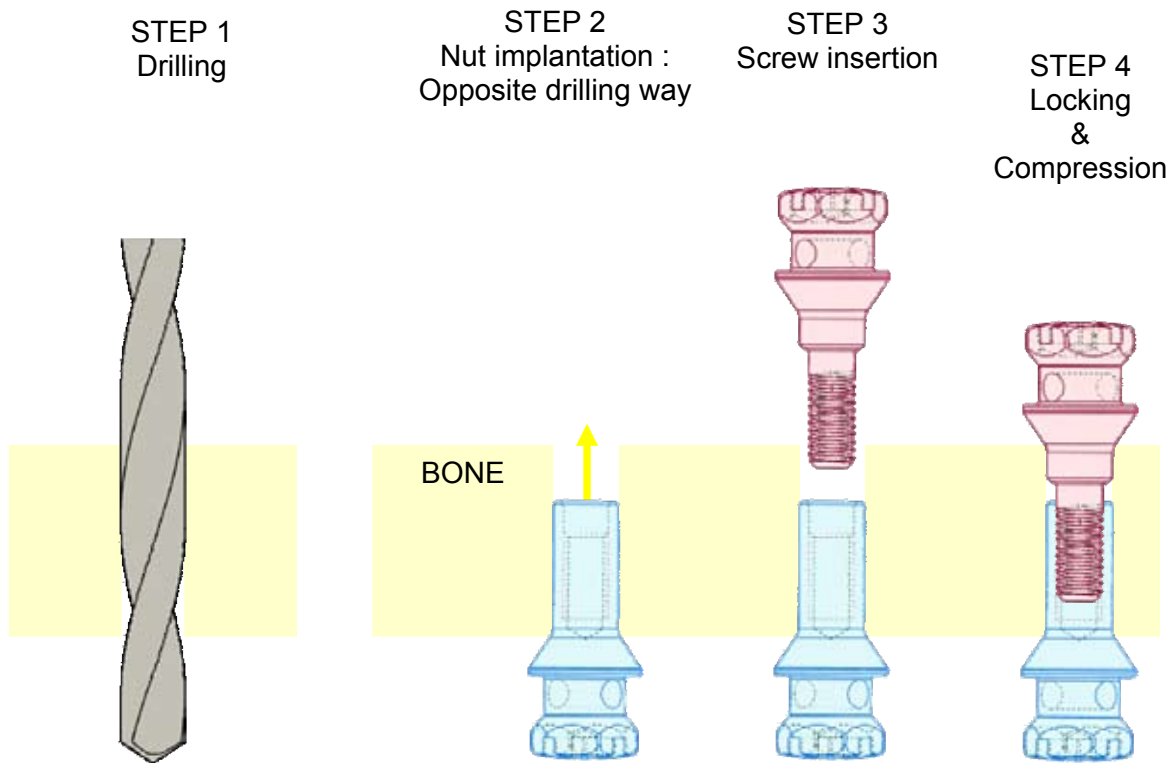
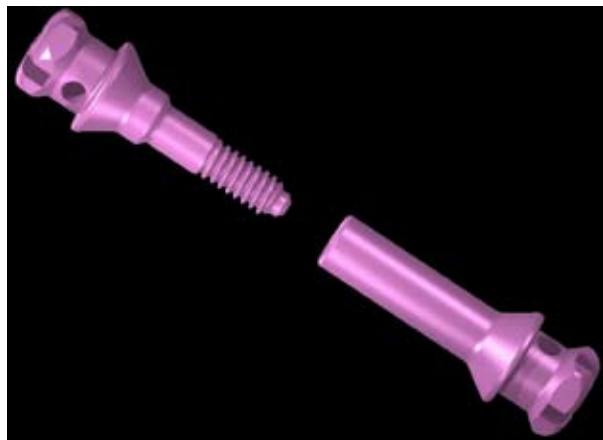
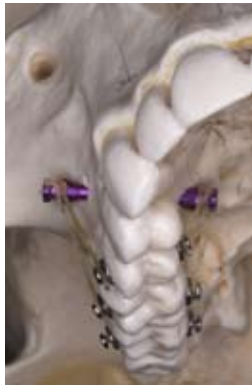
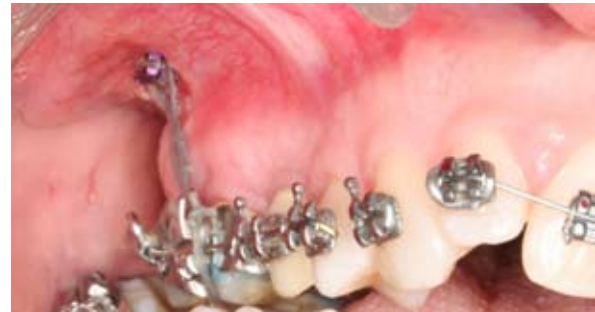Fig. 1. Overerupted molar.

Fig. 2 a y b-Transalveolar Screw (TAS) consisting of a nut of variable lengths and a bolt. Note the cross groove and the tunnel in both heads to allow for coil or elastics engagement.

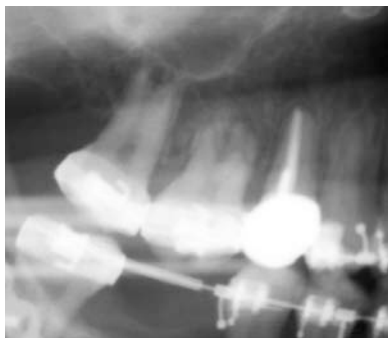




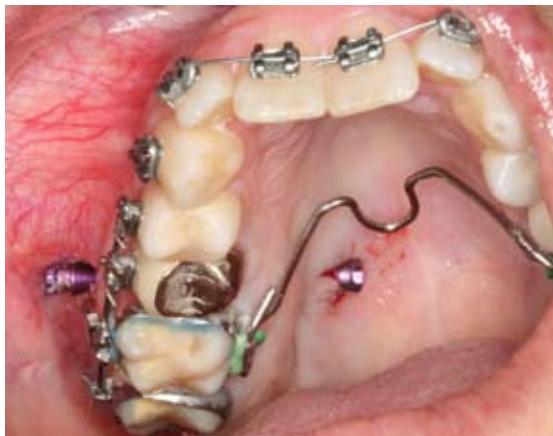**Fig. 3a.** TAS applied on a dry skull. Note how differential elastic forces can be applied in both sides.



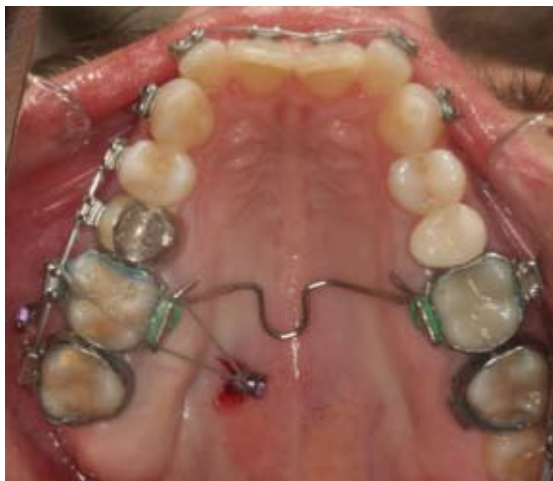**Fig. 3b.** Elastic chain attached to the vestibular side.



**Fig. 4.** Postintrinsic radiograph.



**Fig. 5.** Transalveolar screw inserted at the maxilla.



**Fig. 6.** Elastic thread attached to the palatal side.

Miyawaki et al. (9), comparing three types of miniscrews and a miniplate system, described three major factors that were negatively associated with the success rate of miniscrews placed into the bucal alveolar bone of posterior region: 1) peri-implant gingival inflammation, 2) decreased screw diameter (1mm or less), and 3) increased mandibular plane which often exists with thin cortical bone. In these type of patients, they recommend the use of titanium screws with a diameter of more than 2.3mm diameter or miniplates. They also found important to avoid tissue inflammation around the miniscrew to prevent mobility of the implant anchor. According to their stability results, immediate loading is possible if the applied force is less than 2 N, and finally recommend a flapless surgery to minimize patient discomfort.

As the bone quality in the infrazygomatic crest is generally good, in patients with thin cortical alveolar bone, this would be an alternative site to place the miniscrews. However, one potential problem of placing TADs in extra-alveolar bony sites, is the mobile mucosa that usually grows, covering the head of the screw, making difficult to activate the orthodontic mechanics without a minor surgical uncovering procedure (15).

Several studies (4-6,16) reported the use of titanium miniplates and monocortical fixation screws placed in zygomatic buttress, to get effective intrusion of the maxillary posterior segment in long face patients with anterior open bites. After placing the miniplates, the authors described the need of a waiting period of time (1-8 weeks) for tissue healing, before orthodontic force is applied. After orthodontic correction, the plates and screws are removed. However, miniplates have the disadvantage of surgical damage and risk because of the need for elevation of a mucoperiosteal flap and subperiosteal dissection to expose the bony cortex for both placing and removing them. Miyawaki et al. (9) reported that almost all subjects complained of swelling and pain within a week after the surgery. Moreover, patients may show infections, plate loosening or fracture and mucosal dehiscence (16).

Intrusion of molars by only applying an apically direct-

ed force to the buccal tooth attachment will tip molars to the buccal. Avoiding the tipping moment produced by the intrusive force applied from buccal aspect is essential, because not only impairs posterior occlusion but also creates interferences that impede to close the open bite (5).

There are several ways to counteract this side effect and get a better three-dimensional control of molar movement. Erverdi et al. (5) recommended to place an appliance that consists of two shallow acrylic bite blocks connected with two heavy palatal arches, and wire attachments on each buccal side, which are used for force application. Sherwood et al. (4) used a constricted overlay round archwire to control the buccal crown tipping. The TAS is cheap, easy to place and remove by the orthodontist, has bicortical anchorage, and is loaded in both sides. This allows for symmetrical intrusion of the molars provided that equivalent forces are applied in both buccal and palatal aspects.

The main advantage of TAS is that when placed in the maxilla to intrude upper molars, they allow application of intrusive force from both buccal and palatal aspects simultaneously, so the line of force in relation to the center of resistance of the posterior segment, allows an in-mass intrusion, avoiding buccal tipping or rotations. Moreover the surgical procedure for inserting and removing the bicortical screw is simple, does not require any surgical flap (Fig. 5), so complications are minimal and screws can be loaded immediately, without requiring any waiting healing period of time (Fig. 6).

## References

1. Yao CC, Lee JJ, Chen HY, Chang ZC, Chang HF, Chen YJ. Maxillary molar intrusion with fixed appliances and mini-implant anchorage studied in three dimensions. *Angle Orthod*. 2005;75:754-60.
2. Kuroda S, Katayama A, Takano-Yamamoto T. Severe anterior open-bite case treated using titanium screw anchorage. *Angle Orthod* 2004;74:558-67.
3. Erverdi N, Keles A, Nanda R. The use of skeletal anchorage in open bite treatment: a cephalometric evaluation. *Angle Orthod* 2004;74:381-90.
4. Sherwood KH, Burch JG, Thompson WJ. Closing anterior open bites by intruding molars with titanium miniplate anchorage. *Am J Orthod Dentofacial Orthop* 2002;122:593-600.
5. Erverdi N, Usumez S, Solak A. New generation open-bite treatment with zygomatic anchorage. *Angle Orthod* 2006;76:519-26.
6. Park YC, Lee SY, Kim DH, Jee SH. Intrusion of posterior teeth using mini-screw implants. *Am J Orthod Dentofacial Orthop* 2003;123:690-4.
7. Umemori M, Sugawara J, Mitani H, Nagasaka H, Kawamura H. Skeletal anchorage system for open-bite correction. *Am J Orthod Dentofac Orthop* 1999;115:166-74.
8. Sugawara J, Baik UB, Umemori M, Takahashi I, Nagasaka H, Kawamura H, et al. Treatment and posttreatment dentoalveolar changes following intrusion of mandibular molars with application of a skeletal anchorage system (SAS) for open bite correction. *Int J Adult Orthodon Orthognath Surg*. 2002;17:243-53.
9. Miyawaki S, Koyama I, Inoue M, Mishima K, Sugahara T, Takano-Yamamoto T. Factors associated with the stability of titanium screws placed in the posterior region for orthodontic anchorage. *Am J Orthod Dentofacial Orthop* 2003;124:373-8.
10. Xun C, Zeng X, Wang X. Microscrew anchorage in skeletal anterior open-bite treatment. *Angle Orthod* 2007;77:47-56.
11. Schnelle MA, Beck FM, Jaynes RM, Huja SS. A radiographic evaluation of the availability of bone for placement of miniscrews. *Angle Orthod* 2004;74:832-7.
12. Freudenthaler JW, Haas R, Bantleon H-P. Bicortical titanium screws for critical orthodontic anchorage in the mandible: a preliminary report on clinical applications. *Clin Oral Impl Res*. 2001;12:358-63.
13. Brettin BT, Grosland NM, Qian F, Southard KA, Stuntz TD, Morgan TA, et al. Bicortical vs monocortical orthodontic skeletal anchorage. *Am J Orthod Dentofacial Orthop* 2008; 134:625-35.
14. Wahl N. Orthodontics in 3 millenia. Chapter 15: Skeletal anchorage. *Am J Orthod Dentofacial Orthop* 2008;134:707-10.
15. Kravitz ND, Kusnoto B. Risks and complications of orthodontic miniscrews. *Am J Orthod Dentofacial Orthop*. 2007;131:S43-51.
16. Ari-Demirkaya A, Masry MA, Erverdi N. Apical root resorption of maxillary first molars alter intrusion with zygomatic skeletal anchorage. *Angle Orthod* 2005;75:761-7.