

# Minimally Invasive Surgically Assisted Rapid Palatal Expansion With Limited Approach Under Sedation: A Report of 283 Consecutive Cases

Federico Hernandez-Alfaro, MD, DMD, PhD,\*  
Javier Mareque Bueno, MD, DMD, PhD,† Artur Diaz, MD,‡ and  
Carles Martí Pagés, MD, PhD§

**Purpose:** An adequate transverse maxillary dimension is one of the critical aspects of a functional and stable occlusion. Surgically assisted rapid palatal expansion consists of a surgical liberation of the sites of resistance combined using orthopedic forces. Most technical descriptions advocate the use of general anesthesia with hospital admission.

**Materials and Methods:** Between March 2000 and July 2008, surgery was performed on 283 consecutive cases with transverse skeletal maxillary hypoplasia. The incision ran horizontally to reach the level of the laterals. Osteotomies of lateral walls and pterygoid disjunction were performed in all cases. A V-Y closure was performed in 2 layers. Patients were discharged after recovery from sedation.

**Results:** One hundred seventy-two of the 283 patients were male. Mean age was 18.3 years. Mean surgical time from incision to last suture was 19 minutes. Expanders were Hyrax in 221 cases and Haas in 61, and a bone-borne expander was used in 1 case. At the 1-year follow-up visit, mean expansion was 8.0 at the canines and 8.9 at the mesiovestibular cuspid of the first molar. General anesthesia has been classically advocated for these procedures, the argument being that pterygomaxillary disjunction was too traumatic to be performed under sedation. The surgical technique used sought to attain a balance between maximum mobilization of the maxilla with a complete liberation of all the buttresses and minimum morbidity to avoid further complications.

**Conclusions:** The new technique that we report seeks to combine both aspects and allows for rapid intervention with local anesthesia plus sedation and a minimal approach with a total liberation of the maxillary resistances (piriform aperture pillars, zygomatic buttresses, midpalatal suture, and pterygoid junctions). The minimal approach and incision used in the technique guarantee vascular support to the maxilla via the vestibular corridors.

© 2010 American Association of Oral and Maxillofacial Surgeons  
*J Oral Maxillofac Surg* 68:2154-2158, 2010

An adequate transverse maxillary dimension is one of the critical aspects of a functional and stable occlusion.<sup>1</sup>

Rapid palatal expansion allows transverse discrepancies to be treated in skeletally immature patients. The orthopedic force delivered by the expander opens the midpalatal suture and allows the maxilla to widen.<sup>2</sup> After skeletal maturity, there

is an increase of osseous interdigitation secondary to fusion of the midpalatal suture.<sup>3,4</sup> At this stage, trying to expand the maxilla orthopedically may cause pain, and removal of the expander will be associated with a relapse of the transverse discrepancy.<sup>5</sup> These forces may also cause periodontal problems when posterior teeth are pushed against the vestibular wall.<sup>6</sup>

Received from the Instituto de Cirugia Maxilofacial, Centro Medico Teknon, Oral and Maxillofacial Surgery, Universidad Internacional de Catalunya, Barcelona, Spain.

\*Professor and Director.

†Professor.

‡Professor.

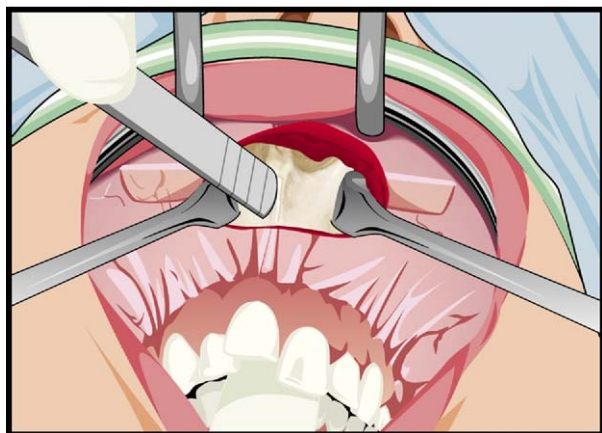
§Professor.

Address correspondence and reprint requests to Dr Hernandez-Alfaro: Instituto de Cirugia Maxilofacial, Centro Medico Teknon, Oral and Maxillofacial Surgery, Vilana 12 Desp 185, 08022 Barcelona, Spain; e-mail: 36984jmb@comb.es

© 2010 American Association of Oral and Maxillofacial Surgeons

0278-2391/10/6809-0019\$36.00/0

doi:10.1016/j.joms.2009.09.080



**FIGURE 1.** Minimal approach from 2 to 2.

*Hernandez-Alfaro et al. Rapid Palatal Expansion With Limited Approach. J Oral Maxillofac Surg 2010.*

Surgically assisted rapid palatal expansion (SARPE) consists of a surgical liberation of the sites of resistance combined using orthopedic forces. Thanks to the principles of osteogenic distraction, SARPE can widen the upper arch in skeletally mature patients.<sup>7</sup> Several technical approaches have been advocated since the first description by Brown,<sup>8</sup> who used a medial palatal osteotomy, the hypothesis being that this area was the most resistant to maxillary expansion.

Since then, several authors have proposed different areas of resistance and advocated several combined osteotomies to mobilize them.<sup>9,10</sup>

The areas of resistance have been classified as anterior support (piriform aperture pillars), lateral support (zygomatic buttresses), posterior support (pterygoid junctions), and medial support (midpalatal suture). The literature reviewed shows no consensus regarding the extent of the necessary osteotomies for SARPE.<sup>11</sup>

Most technical descriptions advocate the use of general anesthesia with hospital admission.<sup>12</sup> Bays and Greco<sup>13</sup> proposed local anesthesia plus sedation as an ambulatory procedure, but only for cases where pterygomaxillary disjunction is not needed. In such cases, posterior expansion is limited.<sup>13</sup>

In this report, we present and retrospectively evaluate our technique for minimally invasive SARPE under local anesthesia plus sedation with total liberation of the anterior, lateral, posterior, and medial buttresses in an ambulatory regimen.

## Materials and Methods

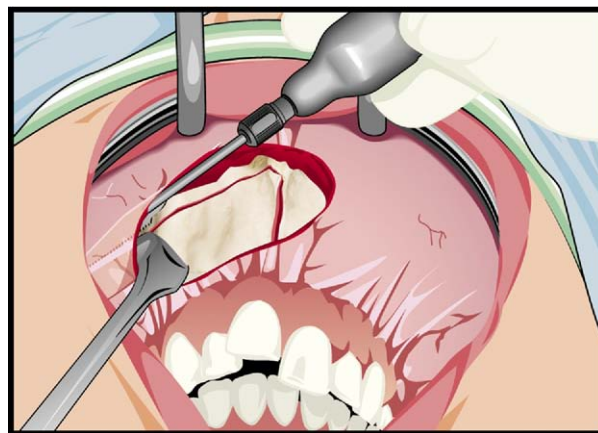
Between March 2000 and July 2008, 283 consecutive patients with transverse skeletal maxillary hypoplasia underwent surgery performed by the same

surgeon (F.H.A.). In all cases, the expander (Hyrax or Haas) was fitted by the orthodontist 1 to 14 days before surgery. Twenty-seven orthodontists were responsible for orthodontic management of the group of patients.

## TECHNIQUE

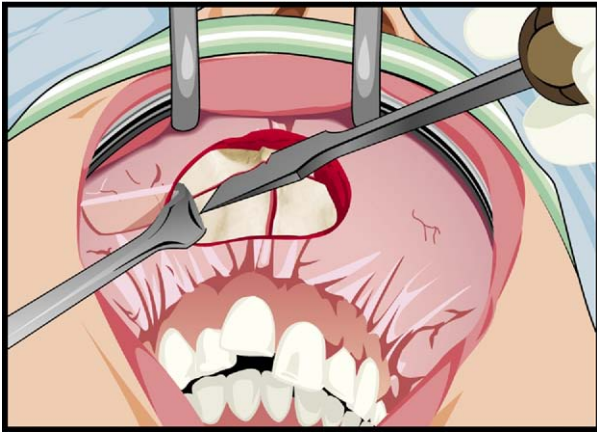
Patients were instructed to rinse their mouth before the procedure, to be accompanied, and to wear comfortable clothes. Local anesthetic (articaine + epinephrine) plus mild intravenous sedation consisting of midazolam and remifentanyl was administered in the operating room in our surgical office setting. Surgical field isolation was achieved through sterile drapes after scrub decontamination of the face with iodine. A through-and-through vestibular incision 10 mm over the keratinized mucosa limit was performed with a Colorado needle. The incision ran horizontally to reach the level of the laterals and measured between 2 and 3.5 cm (mean, 2.9 cm) (Fig 1). Periosteal elevation was then performed with a sharp instrument degloving the maxillary bone from the piriform aperture to the pterygomaxillary junction. The vertical width of the exposed area at the maxilla was sufficient to allow osteotomies to be performed. Subspinal osteotomy was achieved with a sharp chisel to preserve a fair amount of insertions of the nasal base muscles and reduce postoperative nasal widening (Fig 2). Subperiosteal dissection of the nasal floor and disinsertion of the septal base was achieved with a narrow periosteal elevator. A reciprocating saw (Osteomed; Osteoplac S. L. San Sebastián, Guipúzcoa, Spain) with a 2-cm blade was used to perform a sagittal cut posteriorly 2 cm behind the nasal spine and inferiorly to the level of the central incisors' apex.

A blunt osteotome was then used to complete the interdental osteotomy with care not to sever the pal-



**FIGURE 2.** Osteotomy with a reciprocating saw.

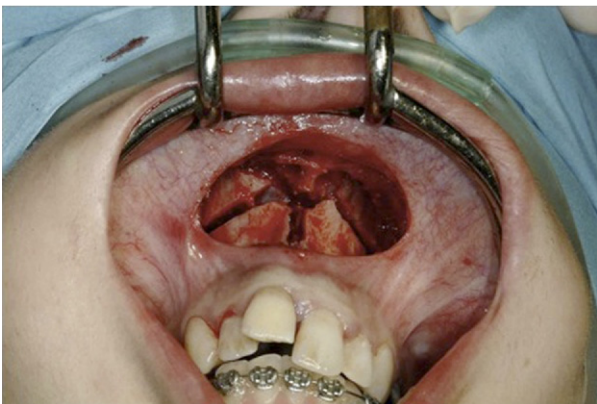
*Hernandez-Alfaro et al. Rapid Palatal Expansion With Limited Approach. J Oral Maxillofac Surg 2010.*



**FIGURE 3.** Use of the osteotome back to the pterygoid plates.

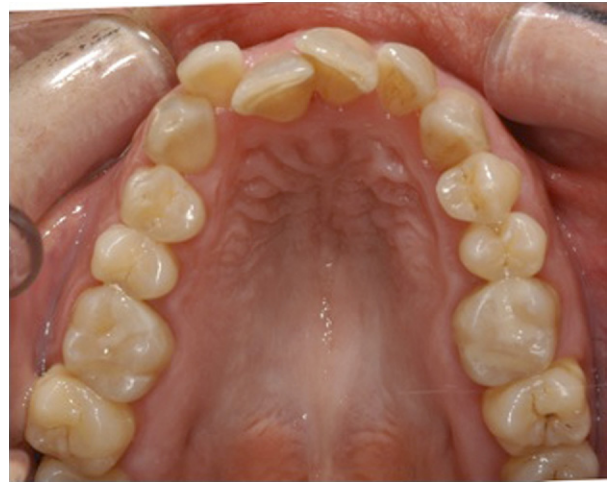
*Hernandez-Alfaro et al. Rapid Palatal Expansion With Limited Approach. J Oral Maxillofac Surg 2010.*

atal mucosa. To prevent this, the surgeon held the osteotome in one hand and used the other hand to palpate the palate at the interincisal area to feel any perforation of the palatal cortex and to avoid severing of the mucosa. The assistant tapped carefully with a hammer (Fig 3). At this point, a reciprocating saw with a 4-cm blade was used to perform the horizontal osteotomies. Nasal periosteum was protected with a spatula, and a Langenbeck retractor with an inverted tip was used to protect the periosteum laterally and posteriorly. Next, lateral osteotomies were completed with a sharp 2-cm osteotome to reach the pterygomaxillary junction (Fig 4). Pterygomaxillary osteotomies in the classic lateral approach were not performed. Instead, the osteotome was driven through the osteotomy back to the posterior wall of the maxillary sinus and then the 2-cm-wide osteotome at the level of the zygomatic buttress was twisted, provoking down-fracturing of the maxilla. The Hyrax or Haas



**FIGURE 4.** Surgical field when the osteotomies have been completed.

*Hernandez-Alfaro et al. Rapid Palatal Expansion With Limited Approach. J Oral Maxillofac Surg 2010.*



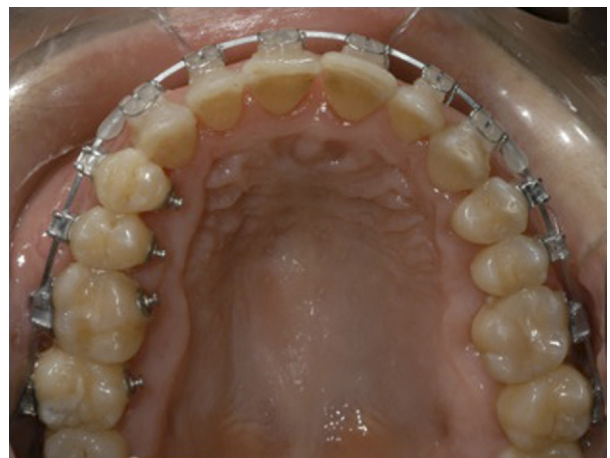**FIGURE 5.** Occlusal view preoperation.

*Hernandez-Alfaro et al. Rapid Palatal Expansion With Limited Approach. J Oral Maxillofac Surg 2010.*

device was activated to check symmetrical and complete expansion of both sides. One-millimeter (4 activations) expansion remained at the time of surgery.

A V-Y closure was performed in 2 layers using 4/0 Vicryl. Interrupted sutures were used in the vertical segment, and running sutures were placed laterally (Fig 5). Patients were discharged after recovery from sedation. The accompanying person received instructions with regard to postoperative care, medication, and diet. Antibiotic, anti-inflammatory, and analgesic drugs were prescribed, together with a chlorhexidine rinse. Ice packs and a soft toothbrush were given to the patient. Occasionally, slight nasal bleeding occurred and temporary nasal cannulated tampons were applied.

Five to 7 days after surgery, patients were instructed to have the expander activated by our staff or



**FIGURE 6.** Occlusal view after orthodontic treatment.

*Hernandez-Alfaro et al. Rapid Palatal Expansion With Limited Approach. J Oral Maxillofac Surg 2010.*

at the orthodontist's office. Activation rate ranged between 0.5 and 1 mm per day, depending on the patient's age; the pace was faster for younger patients. Distraction was continued until desired correction was achieved. No overcorrection was applied. The contention period with the expander in place ranged between 8 and 17 weeks.

## Results

One hundred seventy-two of the 283 patients were male. Ages ranged between 14 and 62 years (mean, 18.3 years). Mean surgical time from incision to last suture was 19 minutes (range, 15 to 32 minutes). Expanders were Hyrax in 221 cases and Haas in 61, and a bone-borne expander was used in 1 case.

In 126 patients, SARPE was the only surgical procedure performed. In the remaining 157, it was followed by other orthognathic maxillary (26), mandibular (374), or maxillomandibular (94) procedures. Mean expansion at the canines was 8.3 mm (range, 3.2 to 13.5 mm). Mean expansion was 9.2 mm (range, 3.0 to 15 mm) at the level of the mesiovestibular cuspid of the first molar.

In 1 case, 2 consecutive hyrax distractors had to be fitted to achieve the desired expansion. In 3 cases, reintervention was necessary because of the lack of expansion on 1 side. The osteotomies were revised under local anesthesia and expansion continued uneventfully. These 3 cases were among the first 50 cases in which the technique was used.

At the 1-year follow-up visit, mean expansion at the canines was 8.0 (range, 3.0 to 13.0), and at the mesiovestibular cuspid of the first molar, it was 8.9 (range, 2.0 to 14.2) (Fig 6).

## Discussion

SARPE has proven to be a stable and reliable method for correcting transverse maxillomandibular deficiencies in nongrowing patients.<sup>14,15</sup> However, very few cases have been published to date. The reason may be reluctance on the part of orthodontists and surgeons to persuade patients to undergo a relatively traumatic procedure only to achieve transverse correction, particularly in cases where further orthognathic procedures were to follow.

General anesthesia has been advocated classically for these procedures,<sup>16</sup> the argument being that pterygomaxillary disjunction was too traumatic to be performed under sedation. As previously proven,<sup>17,18</sup> pterygomaxillary osteotomy is not necessary to achieve successful pterygomaxillary disjunction. In our patients, completion of Le Fort I osteotomies followed by twisting a 2-cm chisel at the level of the malar buttress suffices to down-fracture the posterior

part of the maxilla, thus releasing the pterygomaxillary suture. This is exactly the same pterygomaxillary disjunction procedure that we use in our regular maxillary Le Fort I osteotomies.

All of our cases were conducted under local anesthesia plus sedation, allowing SARPE to be performed as an ambulatory procedure in the office. This fact, together with the amnesic effect of midazolam, prevents the patient from perceiving the operation as a major procedure. Other factors also have a bearing on how patients and relatives view the procedure. One is the short operative time (mean, 19 minutes), which allows quick recovery from the sedation and prompt discharge. The other is reduced morbidity related to a limited intraoral incision.

This procedure is technically sensitive and depends largely on the surgeon's experience and skill. The frequency of a given procedure and the development of instrumentation protocols<sup>19,20</sup> diminish operative time. By contrast, the anesthesia surgery time largely determines the recovery time and hospital stay.<sup>21</sup>

Descriptions of incision for access in SARPE are scarce. Aside from palatal incision, which violates the distraction principles of avoiding scars directly over the osteotomies, most authors use long incisions or combined short incisions in the vestibule.<sup>20,21</sup> Others have described an endoscopic approach through the nasal floor.<sup>22</sup> In our protocol, a short anterior incision ensures vascular supply via the vestibular mucosa. The same incision allows subperiosteal dissection and osteotomies from the piriform aperture to the pterygomaxillary junction. In fact, a complete Le Fort I without mobilization is performed. This complete freeing and bipartition of the maxilla warrants transverse skeletal distraction and prevents a harmful burden at teeth level.

No reports were found regarding the amount of transverse expansion and degree of stability achieved with SARPE.<sup>19</sup> Our technique has proved to be effective. A mean 8.3 and 9.2 expansion at the canine and first molar level, respectively, was achieved. One issue might be to differentiate between skeletal and dental expansion in these cases. In 2 cases of our series, dental expansion was detected because of the worsening of the curve of Wilson. This invariably means that skeletal expansion is impaired and should be an indication for surgical revision. Although relapse at the 1-year follow-up visit is practically nonexistent, we cannot infer from our data how much of the achieved expansion is dental and how much is skeletal. Currently, we are conducting an ongoing prospective study to evaluate these parameters more accurately with cone beam computed tomography.

Advantages of SARPE include normalization of maxillary width, improvement of periodontal health, and correction of the negative space. In some cases, it

avoids dental extractions.<sup>14</sup> With regard to the surgical technique, we tried to reach a balance between maximum mobilization of the maxilla with a complete liberation of all the buttresses and minimum morbidity to prevent further complications.

The new technique reported herein seeks to combine both aspects: it allows rapid intervention under local anesthesia plus sedation, and a minimal approach with a total liberation of the maxillary resistances (piriform aperture pillars, zygomatic buttresses, midpalatal suture, and pterygoid junctions).

On other hand, the minimal approach and incision associated with this technique ensure vascular support to the maxilla via the vestibular corridors.

Betts et al<sup>16</sup> describe SARPE with a piezoelectric device in 6 patients, with local anesthesia plus oral sedation. Their mean surgical time is 45 minutes, and they use 3 different vestibular incisions. Several studies recommend overcorrection to compensate the 5% to 25% relapse reported in the literature.<sup>12,13,19</sup> In our protocol, we do not overcorrect because of the low number of relapses. Where relapses occur, we assume that the duration of postdistraction contention was insufficient.

The absence of postoperative complications in our series, combined with a low number of relapses, supports this technique for management of maxillomandibular transverse discrepancies of more than 5 mm in skeletally mature patients.

## References

1. Vanarsdale R, White R: Three dimensional analysis for skeletal problems. *Int J Adult Orthodon Orthognath Surg* 9:159, 1994
2. Haas AJ: Palatal expansion: Just the beginning of dentofacial orthopedics. *Am J Orthod* 57:219, 1970
3. Melson B: Palatal growth studied on human autopsy material. *Am J Orthod* 68:42, 1975
4. Melson B, Melson F: The postnatal development of the palato-maxillary region studied on human autopsy material. *Am J Orthod* 82:329, 1982
5. Haas AJ: Long term post treatment evaluation of rapid palatal expansion. *Angle Orthod* 50:189, 1980
6. Vanarsdall RL: Periodontal/orthodontic relationships, *in* Graber TM, Vanarsdall RL (eds): *Orthodontics: Current Principles and Techniques* (ed 2). St Louis, MO, CCV Mosby, 1994
7. Bell RA: A review of maxillary expansion in relation to rate of expansion and patients age. *Am J Orthod* 81:32, 1982
8. Brown GVI: *The Surgery of Oral and Facial Diseases and Malformations* (ed 4). Londres, Kimpton, 1938, p 507
9. Bell WH, Epker BN: Surgical-orthodontic expansion of the maxilla. *Am J Orthod* 70:517, 1976
10. Kennedy JW, Bell WH: Osteotomy as an adjunct to rapid maxillary expansion. *Am J Orthod* 67:44, 1975
11. Lines PA: Surgically assisted rapid palatal expansion: A literature review. *Am J Orthod Dentofac Orthop* 133:290, 2008
12. Pogrel MA, Kaban LB, Vangervik K: Surgically assisted rapid maxillary expansion in adults. *Int J Adult Orthodon Orthognath Surg* 7:37, 1992
13. Bays RA, Greco JM: Surgically assisted rapid palatal expansion: An outpatient technique with long-term stability. *J Oral Maxillofac Surg* 50:110, 1992
14. Swennen G, Holm J: Craniofacial distraction osteogenesis: A review of the literature. Part I; Clinical studies. *Int J Oral Maxillofac Surg* 30:89, 2001
15. Puigdollers A, De La Iglesia F: Actualización sobre la disyunción asistida quirúrgicamente. *Rev Esp Ortod* 33:263, 2003
16. Betts NJ, Vanarsdall RL, Barber HD, et al: Diagnosis and treatment of transverse maxillary deficiency. *Int J Adult Orthodon Orthognath Surg* 10:75, 1995
17. Precious DS, Morrison A, Ricard D: Pterygomaxillary separation without the use of an osteotome. *J Oral Maxillofac Surg* 49:98, 1991
18. Precious DS, Ricard D: Modifications of LeFort I osteotomies. Pterygomaxillary disjunction by an interior rotation of the maxilla. *Rev Stomatol Chir Maxillof* 89:788, 1988
19. Chamberland S, Proffit WR: Closer look at the stability of surgically assisted rapid palatal expansion. *J Oral Maxillofac Surg* 66:1895, 2008
20. Dann JJ: Outpatient oral and maxillofacial surgery: Transition to a surgicenter setting and outcome of the first 200 cases. *J Oral Maxillofac Surg* 56:572, 1998
21. Lupori JP, Van Sickels JE, Holmgreen WC: Outpatient orthognathic surgery: Review of 205 cases. *J Oral Maxillofac Surg* 55:558, 1997
22. Mommaerts MY, Collado J, Mareque Bueno J: Morbidity related to "endocorticotomies" for transpalatal distraction. *J Craniomaxillofac Surg* 36:198, 2008