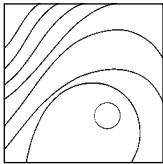


Mandibular Reconstruction with Tissue Engineering in Multiple Recurrent Ameloblastoma



Federico Hernández-Alfaro, MD, DDS, PhD*
 Vanessa Ruiz-Magaz, DMD**/Punjamun Chatakun, DDS***
 Raquel Guijarro-Martínez, MD****

The aim of this paper is to present a new approach to bone regeneration in a patient with multiple recurrent ameloblastoma of the left mandibular angle. Through an extraoral approach, complete resection of the tumor was achieved. Bone marrow aspirate from the iliac crest was centrifuged to concentrate the mesenchymal cellular fraction. Based on a stereolithographic cast, titanium mesh was bent preoperatively to accurately reconstruct the mandibular angle. The mesh was filled with two blocks of xenogenic material mixed with recombinant bone morphogenetic protein 7 (BMP-7) and stem cells. Nine months later, three endosseous implants were placed in the regenerated bone to restore the patient's masticatory function. At this time, bone samples were obtained for histomorphometric analysis. New bone formation was confirmed around the particles of xenograft material. The results indicate that adequate esthetics and function may be achieved with bone marrow aspirate seeded on a scaffold obtained from bovine xenograft blocks and BMP-7. This technique attains new bone formation with sufficient quantity and quality to allow for implant placement, with decreased patient morbidity and surgical time compared to conventional reconstructive methods. (Int J Periodontics Restorative Dent 2012;32:e82–e86.)

*Oral and Maxillofacial Surgeon and Head, Institute of Maxillofacial Surgery and Implantology, Teknon Medical Center, Barcelona, Spain; Clinical Professor of Oral and Maxillofacial Surgery and Director, Master in Implant Dentistry, Universitat Internacional de Catalunya, Barcelona, Spain.

**Periodontist, Institute of Maxillofacial Surgery and Implantology, Teknon Medical Center, Barcelona, Spain; Associate Professor of Periodontics, Universitat Internacional de Catalunya, Barcelona, Spain.

***Fellow, International Master Program in Implantology, Universitat Internacional de Catalunya, Barcelona, Spain.

****Fellow, Institute of Maxillofacial Surgery and Implantology, Teknon Medical Center, Barcelona, Spain.

Correspondence to: Dr Federico Hernández-Alfaro, Institute of Maxillofacial Surgery and Implantology, Teknon Medical Center, Vilana, 12. D-185, 01022 Barcelona, Spain; email: director@institutomaxilofacial.com.

An ameloblastoma is a tumor of odontogenic epithelial origin. It represents approximately 1% of all cysts and tumors of the maxillofacial region.^{1,2} Although its cellular features categorize it as benign, it may be locally aggressive—causing severe facial deformity and functional impairment—and highly recurrent.³ The most commonly affected sites are the posterior body and angle of the mandible.^{4,5}

Adequate treatment requires thorough surgical resection of the tumor as well as a functionally and esthetically acceptable reconstruction of the residual defect.³ Soft tissue loss must be minimized; however, incomplete resection of the primary lesion leads to a high risk of recurrence. Several reconstructive options have been proposed, but the corticocancellous block graft is still considered the method of choice for defects less than 5 cm. These grafts tend to be harvested from the anterior or posterior iliac crest with survival rates dependent on the rate of graft revascularization. In addition, micromovements of the graft jeopardize its viability.⁶

Microvascular bone grafting shows higher success rates for defects that are greater than 5 cm in size. The fibula flap is considered the gold standard for mandibular reconstruction⁷; however, microvascular reconstruction is often technically demanding and time-consuming, may cause significant morbidity both at donor and recipient sites, and requires general anesthesia and hospitalization. Further, the quality and height of the bone graft is frequently limited.^{8,9} These drawbacks have led to the development of reconstructive procedures based on tissue engineering.

Tissue engineering blends regenerative medicine and surgery, with its three basic components being scaffolds, cells, and signaling molecules. Tissue regeneration and functional restoration are achieved through the implantation of cells and tissues developed outside the body or the promotion of cell growth in an implanted matrix.¹⁰ These procedures eliminate the need to harvest tissue from a donor site, thereby eradicating concomitant donor site morbidity.¹¹

Bone morphogenetic proteins (BMPs) are multifunctional proteins with a wide range of biologic activities involving a variety of cell types.^{12,13} According to the scientific literature, BMPs mediate in cell growth regulation, differentiation, chemotaxis, and apoptosis and play pivotal roles in morphogenesis.¹⁴ Implantation of this protein component of bone matrix results in a complex series of cellular events, including mesenchymal cell infiltra-

tion, cartilage formation, vascularization, bone formation, and ultimately, remodeling of the new bone tissue along with population by hematopoietic bone marrow elements.¹⁵

In 2004, Warnke et al¹⁶ reported a case of mandibular reconstruction with a titanium mesh cage filled with bone mineral blocks, 7 mg of recombinant bone morphogenetic protein 7 (rBMP-7), and 20 mL of the patient's bone marrow. The reconstruction was implanted into the latissimus dorsi muscle and then transferred to repair the mandibular defect. This technique provided a good three-dimensional outcome.¹⁶

The aim of this article is to report a case of recurrent ameloblastoma in which mandibular reconstruction was achieved with bovine hydroxyapatite blocks and BMP-7 in combination with bone marrow aspirate concentrate.

Case report

A 33-year-old woman was referred to the authors' institute with a diagnosis of recurrent ameloblastoma. The patient had been initially diagnosed 2 years earlier, and conservative treatment (extensive curettage) had been applied at that time at a different facility. Tumor recurrence was detected 11 months later, and the patient was subsequently referred to the authors' institute for radical treatment.

A cone beam computed tomography (CBCT) evaluation revealed an expansive lesion in the left mandibular body with cortical

penetration and involvement of a neighboring dental implant (Fig 1). The surgical plan included mandibular segmentectomy with safety margins to avoid further recurrences and a reconstructive procedure. Regarding the latter, the patient refused a free bone graft from the iliac crest and a microvascularized flap from the same donor site. Reconstruction with tissue engineering techniques was thus proposed.

Preoperative work-up included a stereolithographic cast on which a titanium mesh tray was adapted (Fig 2).

Surgery was performed under general anesthesia. An extraoral submandibular 4-cm incision was chosen to minimize the risk of contaminating the reconstruction. Segmental mandibular resection was performed using a reciprocating saw with a safety margin of 1 cm at each side (Fig 3). Therefore, a 6-cm defect was created. The reconstruction was prepared within the preformed titanium mesh using protein demineralized bovine blocks (Bio-Oss, Geistlich) infused with 2 g of rBMP-7 and 5 mL of concentrate from a bone marrow aspirate. To obtain the marrow-derived mesenchymal cell concentration, the iliac crest was perforated approximately 3 cm laterocaudally from the superior posterior iliac spine using a bone marrow biopsy needle. With three 20-mL syringes containing 0.3 mL of heparin solution diluted with sodium chloride to 1,000 U/mL each, 40 mL of bone marrow was collected. The aspirate was pooled and anticoagulated with 3.5 mL of heparin solution.

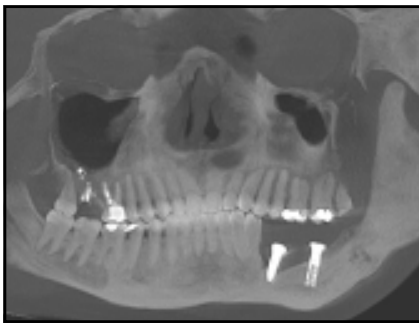


Fig 1 Orthopantomograph showing an ameloblastoma in the left side of the mandible.

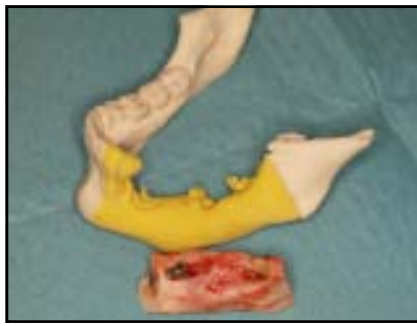

Fig 2 Stereolithographic cast of the mandible and the resected portion.




Fig 3 Titanium mesh adapted to the stereolithographic cast.



Fig 4 Titanium mesh with protein demineralized bovine blocks, bone marrow cells, BMP-7, and bioabsorbable collagen membranes.

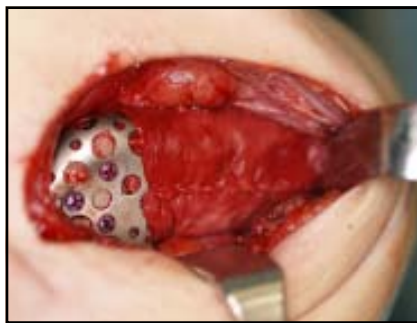

Fig 5 Intraoperative view of the titanium mesh adapted to the patient's mandible and covered with bioabsorbable collagen membranes.

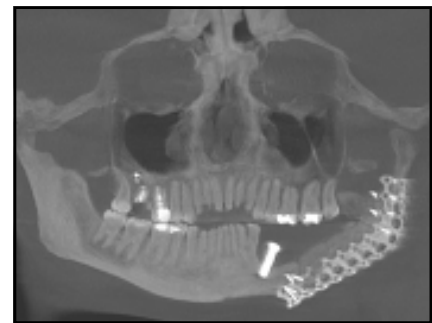

Fig 6 Postoperative orthopantomograph showing the titanium mesh and protein demineralized bovine blocks in place.

According to the manufacturer's instructions, bone marrow cells were isolated directly in the operating room using the BMCA system (Bone Marrow Procedure Pack, Harvest Technologies). To avoid fibrous tissue ingrowth, four bioabsorbable collagen membranes (Bio-Gide, Geistlich) were used (Fig 4). The tissue-engineered reconstruction was then stabilized with screws to bridge the defect, and wound closure was achieved in three layers (Fig 5).

Postoperative recovery was uneventful. A postoperative CBCT confirmed adequate reconstruction of the defect (Fig 6). The pathology report was consistent with the

diagnosis of ameloblastoma, and the resection margins were free of tumor invasion.

Nine months later, reentry for implant placement allowed for the harvesting of two cores for histologic analysis. Three 4×13 -mm Osseotite implants (Biomet 3i) were inserted (two implants in the reconstructed area) (Fig 7). Histologic analysis of the cores harvested at implant insertion revealed new bone formation around the particles of xenograft material (Fig 8). Four months later, the implants were loaded with a fixed prosthesis. At the 1-year follow-up, the implants remained stable (Fig 9).

Discussion

At present, autogenous bone represents the gold standard for hard tissue regeneration. Alternative options include allogenic or xenogenic bone substitutes. The advent of tissue engineering has allowed for the upgrading of standard treatment options, but the efficacy of tissue-engineering techniques depends on the particular method and grafting material used. In the present report, a large critical-sized defect was repaired with bone marrow aspirate seeded on a scaffold obtained from bovine hydroxyapatite blocks, and BMP-7 served as an osteoinductive medium.

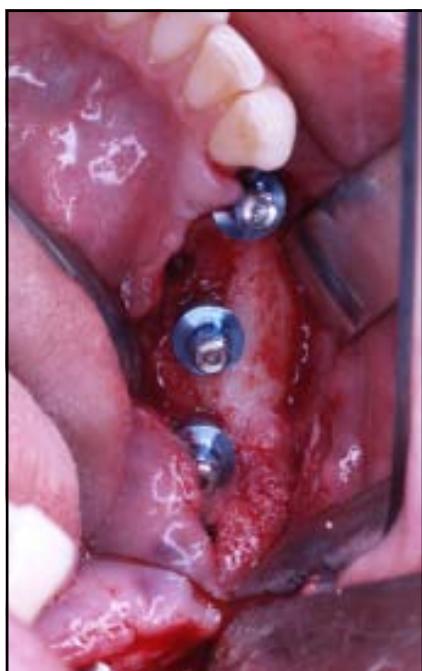

Fig 7 Implants were placed in the reconstructed area after 9 months.

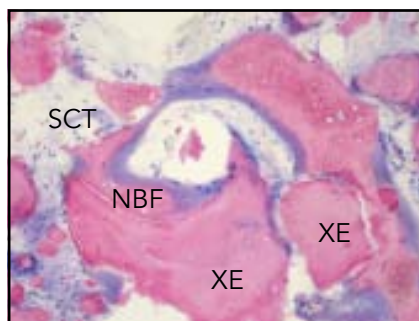


Fig 8 Histomorphometric analysis revealed new bone formation (NBF) around particles of xenograft material (XE) and soft connective tissue (SCT).

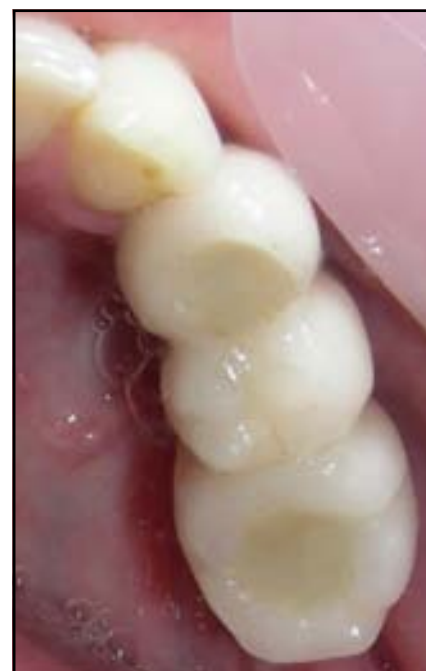

Fig 9 Occlusal view of the implant prosthesis after 1 year in function.

There is recent evidence proving the efficacy of BMPs.^{8,10,12-21} In terms of osteogenesis and osseous defect repair, growth factors seem to have the highest efficacy.²² Regarding safety, minor side effects, including headaches, an increase and modification of plasma amylase levels without pancreatitis, and a decrease in magnesium and tachycardia, have been reported in accordance with BMP use.²³ The generation of anti-BMP or anticollagen antibodies has been detected in less than 4% of the population, with no clinically significant consequences.²³

BMP-7, also known as osteogenic protein 1 (OP-1), has proven its osteoinductive capacity both in experimental and clinical trials.²⁴

It has been used in combination with a type I collagen carrier for the treatment of tibial nonunions, and clinical and radiographic results comparable to the autogenous bone control group have been reported.²⁵ All new bone induced by any bone grafting material or osteogenic molecule, including BMP-7, may be considered of autogenous origin and is prone to normal bone remodeling.²⁵

In clinical use, bone growth factors need a carrier. Many types of scaffolding have been developed to maintain BMP levels for a long period.²⁶ Animal studies have shown efficient regeneration of critical-sized defects with recombinant forms of BMP combined with collagen carriers such as guanidine-

extracted demineralized bone matrix, hydroxyapatite, or biodegradable polymers.²⁶

Bone marrow-derived stem and progenitor cells have been used to regenerate several tissues, including bone.^{27,28} Their use as bone marrow aspirate concentrate is a promising alternative to conventional autogenous grafting.²⁹ A recent prospective study in the field of orthopedic surgery has shown bone marrow aspirate concentrate combined with biomaterials (porous hydroxyapatite and β -tricalcium phosphate) generates bone trabeculae and a lamellar pattern in spinal fusion surgery.³⁰

In this patient, bone marrow aspirate seeded on a scaffold obtained from bovine hydroxyapatite

blocks (soaked in bone marrow concentrate for 10 minutes) and BMP-7 gave way to new bone formation that was confirmed histologically. The patient presented sufficient bone for implant placement and stable results after 1 year of loading.

Conclusion

Tissue engineering can be a valid alternative to conventional mandibular reconstruction techniques, decreasing patient morbidity and surgical time and thus increasing patient acceptance of the procedure. According to the results of this clinical evaluation, bone marrow aspirate seeded on a scaffold obtained from bovine hydroxyapatite blocks and BMP-7 achieves new bone formation with sufficient quantity and quality to allow for implant placement. Despite this promising preliminary outcome, further clinical assessment is mandatory.

References

- Gorlin RJ, Chaudhry AP, Pindborg JJ. Odontogenic tumors. Classification, histopathology, and clinical behavior in man and domesticated animals. *Cancer* 1961; 14:73–101.
- Adebiyi KE, Ugboko VI, Omoniyi-Esan GO, Ndukwe KC, Oginni FO. Clinicopathological analysis of histological variants of ameloblastoma in a suburban Nigerian population. *Niger J Clin Pract* 2011; 14:242–244.
- Sham E, Leong J, Maher R, Schenberg M, Leung M, Mansour AK. Mandibular ameloblastoma: Clinical experience and literature review. *ANZ J Surg* 2009;79:739–744.
- Bataineh AB. Effect of preservation of the inferior and posterior borders on recurrence of ameloblastomas of the mandible. *Oral Surg Oral Med Oral Pathol Oral Radiol Endod* 2000;90:155–163.
- Zétola A, Ferreira FM, Larson R, Shibli JA. Recombinant human bone morphogenetic protein-2 (rhBMP-2) in the treatment of mandibular sequelae after tumor resection. *Oral Maxillofac Surg* 2011;15:169–174.
- Goh BT, Lee S, Tideman H, Stoelinga PJ. Mandibular reconstruction in adults: A review. *Int J Oral Maxillofac Surg* 2008; 37:597–605.
- Hidalgo DA. Fibula free flap: A new method of mandible reconstruction. *Plast Reconstr Surg* 1989;84:71–79.
- Herford AS, Boyne PJ. Reconstruction of mandibular continuity defects with bone morphogenetic protein-2 (rhBMP-2). *J Oral Maxillofac Surg* 2008;66:616–624.
- Sun G, Yang X, Wen J, Wang A, Hu Q, Tang E. Treatment of compartment syndrome in donor site of free fibula flap after mandibular reconstruction surgery. *Oral Surg Oral Med Oral Pathol Oral Radiol Endod* 2009;108:e15–e18.
- Vats A, Tolley NS, Polak JM, Gough JE. Scaffolds and biomaterials for tissue engineering: A review of clinical applications. *Clin Otolaryngol Allied Sci* 2003; 28:165–172.
- Schmelzeisen R, Schimming R, Sittinger M. Making bone: Implant insertion into tissue-engineered bone for maxillary sinus floor augmentation—A preliminary report. *J Craniomaxillofac Surg* 2003;31:34–39.
- Wozney JM, Rosen V, Celeste AJ, et al. Novel regulators of bone formation: Molecular clones and activities. *Science* 1988; 242:1528–1534.
- Ebara S, Nakayama K. Mechanism for the action of bone morphogenetic proteins and regulation of their activity. *Spine (Phila Pa 1976)* 2002;27(suppl 1):S10–S15.
- Hogan BL. Bone morphogenetic proteins: Multifunctional regulators of vertebrate development. *Genes Dev* 1996;10: 1580–1594.
- Reddi AH. Cell biology and biochemistry of endochondral bone development. *Coll Relat Res* 1981;1:209–226.
- Warnke PH, Springer IN, Wiltfang J, et al. Growth and transplantation of a custom vascularised bone graft in a man. *Lancet* 2004;364:766–770.
- Urist MR, Strates BS. Bone morphogenetic protein. *J Dent Res* 1971;50:1392–1406.
- Wozney JM. Overview of bone morphogenetic proteins. *Spine (Phila Pa 1976)* 2002;27(suppl 1):S2–S8.
- Wikesjö UM, Qahash M, Huang YH, Xiropaidis A, Polimeni G, Susin C. Bone morphogenetic proteins for periodontal and alveolar indications; Biological observations—Clinical implications. *Orthod Craniofac Res* 2009;12:263–270.
- Lan J, Wang ZF, Shi B, Xia HB, Cheng XR. The influence of recombinant human BMP-2 on bone-implant osseointegration: Biomechanical testing and histomorphometric analysis. *Int J Oral Maxillofac Surg* 2007;36:345–349.
- Boyne PJ. Application of bone morphogenetic proteins in the treatment of clinical oral and maxillofacial osseous defects. *J Bone Joint Surg Am* 2001;83-A(suppl 1): S146–S150.
- Schliephake H. Bone growth factors in maxillofacial skeletal reconstruction. *Int J Oral Maxillofac Surg* 2002;31:469–484.
- Obert L, Deschaseaux F, Garbuio P. Critical analysis and efficacy of BMPs in long bones non-union. *Injury* 2005;36(suppl 3): S38–S42.
- Terheyden H, Warnke P, Dunsche A, et al. Mandibular reconstruction with prefabricated vascularized bone grafts using recombinant human osteogenic protein-1: An experimental study in miniature pigs. Part II: Transplantation. *Int J Oral Maxillofac Surg* 2001;30:469–478.
- Friedlaender GE, Perry CR, Cole JD, et al. Osteogenic protein-1 (bone morphogenetic protein-7) in the treatment of tibial nonunions. *J Bone Joint Surg Am* 2001;83-A(suppl 1):S151–S158.
- Lane JM. BMPs: Why are they not in everyday use? *J Bone Joint Surg Am* 2001;83-A(suppl 1):S161–S163.
- Dennis JE, Esterly K, Awadallah A, Parrish CR, Poynter GM, Goltry KL. Clinical-scale expansion of a mixed population of bone-marrow-derived stem and progenitor cells for potential use in bone-tissue regeneration. *Stem Cells* 2007;25: 2575–2582.
- Smiler D, Soltan M. Bone marrow aspiration: Technique, grafts, and reports. *Implant Dent* 2006;15:229–235.
- Sauerbier S, Stricker A, Kuschnierz J, et al. In vivo comparison of hard tissue regeneration with human mesenchymal stem cells processed with either the FICOLL method or the BMAC method. *Tissue Eng Part C Methods* 2010;16:215–223.
- Bansal S, Chauhan V, Sharma S, Maheshwari R, Juyal A, Raghuvanshi S. Evaluation of hydroxyapatite and beta-tricalcium phosphate mixed with bone marrow aspirate as a bone graft substitute for posterolateral spinal fusion. *Indian J Orthop* 2009; 43:234–239.